

## Protective Effects of Interleukin-4 on Tissue Destruction and Morphological Changes of Bovine Nasal Chondrocytes *in vitro*

Maryam Yadegari<sup>1,2</sup>, Mahmoud Orazizadeh<sup>\*2</sup>, Mahmoud Hashemitabar<sup>2</sup> and Ali Khodadadi<sup>3</sup>

<sup>1</sup>Dept. of Biology and Anatomical Sciences, Shahid Sadoughi University of Medical Sciences, Faculty of Medicine, Yazd, Iran; <sup>2</sup>Dept. of Anatomical Sciences, Cellular and Molecular Research Center (CMRC), Ahvaz Jundishapur University of Medical Sciences, Faculty of Medicine, Ahvaz, Iran; <sup>3</sup>Dept. of Immunology, Ahvaz Jundishapur University of Medical Sciences, Faculty of Medicine, Ahvaz, Iran

Received 9 March 2013; revised 31 July 2013; accepted 11 August 2013

### ABSTRACT

**Background:** Previous studies have shown that some cytokines have protective effects on cartilage in joint diseases. In the current study, effects of IL-4 against morphological changes and tissue degradation induced by IL-1 $\alpha$  on bovine nasal cartilage (BNC) explants were investigated. **Methods:** Fresh BNC samples were prepared from a slaughterhouse under sterile conditions. BNC explants culture was treated with both IL-1 $\alpha$  (10 ng/ml) and IL-4 (50 ng/ml) at the same time for 28 days. The morphological characteristics of explants were assessed by using histology techniques and invert microscopy. Matrix metalloproteinase-1 (MMP-1) production was assessed within different days by using Western blotting. **Results:** IL-1 $\alpha$  induced prominent cartilage morphology degradation. The pro and active form of MMP-1 band substantially increased at day 21 of culture. In the presence of both IL-1 $\alpha$  and IL-4, chondrocytes preserved their ordinary normal phenotype with intact extracellular matrix. In addition, a significant reduction in pro-MMP-1 and inhibition of active MMP-1 was seen. **Conclusion:** In conclusion, IL-4 could be regarded as a potential candidate in cartilage protecting against the degradation changes of IL-1 $\alpha$ . It seems that the preservation effect of IL-4 is associated with significant reduction of MMP-1. *Iran. Biomed. J. 17 (4): 187-193, 2013*

**Keywords:** Chondrocyte, Interleukin-1 $\alpha$ , Interleukin-4, Matrix metalloproteinase-1, Bovine nasal cartilage

### INTRODUCTION

Previous studies have shown that patients with joint diseases such as rheumatoid arthritis and osteoarthritis are at high risk of developing several disorders, and these patients, experience poorer outcomes compared with the general population [1, 2]. Destruction of articular cartilage and underlying bone is a major indication in joint diseases. Articular cartilage is composed of one cell type, chondrocytes, and extracellular matrix (ECM) in which proteoglycan and collagen are the two major structural components. The loss of proteoglycan and type II collagen are principal features of the damage to articular cartilage in both rheumatoid arthritis and osteoarthritis [2-4].

During joint diseases, proinflammatory cytokines such as TNF- $\alpha$  and IL-1 act upon chondrocytes to produce matrix metalloproteinases (MMP). It has been previously shown that MMP are activated during the joint diseases and lead to destruction of the cartilage,

thus result in joint dysfunction [4-5]. MMP are a family with at least 21 members, which can be classified into: collagenases (MMP-1, -8, and -13), stromelysins (MMP-3, -10, and -11), gelatinases (MMP-2 and -9), and membrane type 1 (MMP-14). MMP are regulated at a number of points, including synthesis and secretion by cytokines, requiring proteolytic cleavage for activation of proenzyme forms and inhibition of their active forms by inhibitors [5-7]. MMP-1 is involved in the breakdown of cartilage collagen in joint disorders and is known to be present inside the rheumatoid synovial fluid taken from patients with rheumatoid arthritis [5, 8-10].

Some cytokines may take part in suppressing of synovial inflammation and joint destruction. Anti-inflammatory cytokines have important roles in suppression of inflammatory cytokines. IL-4, an anti-inflammatory cytokine, is undetectable in arthritic tissue of rheumatoid arthritis patients [11-13]. Studies have shown that incubation of human synovial

fibroblasts with both IL-1 and IL-4 at the same time resulted in a significant decrease in both MMP-1 and MMP-3 mRNA levels compared with IL-1 alone. In addition, IL-4 in osteoarthritis synovial tissue could suppress the synthesis of both IL-1 and TNF- $\alpha$  [14, 15].

The chondrocytes are important in the control of cartilage integrity, and they are responsible for synthesis and maintenance of the cartilage ECM [2-4]. Although different effects of IL-4 on cartilage under *in vitro* conditions have been previously reported [4, 15], the mechanisms of IL-4 on chondrocyte morphology and ECM alterations have been poorly characterized. In our previous study, IL-4 showed significant protective effects on chondrocytes morphology in comparison with prednisolone alone [16]. Therefore, in this study, to achieve more details of our previous study [16], the proper effects of IL-4 on proteoglycan releasing, the alterations of ECM, and chondrocyte morphological changes of bovine nasal cartilage (BNC) explants were investigated. In addition, the effects of IL-4 on MMP-1 production (as an important degenerating factor in cartilage), and a possible association between MMP-1 regulation and the effects of IL-4 on chondrocyte morphology were also investigated.

## MATERIALS AND METHODS

**Preparation of cartilage.** BNC was obtained from an adult animal shortly after sacrifice. The nasal septum was dissected out, and samples were washed thoroughly with normal saline and sterile PBS ( $\times 2$ ). The whole perichondrium was removed from the cartilage with sterile scalpel. The procedure was applied as described previously [16, 17].

**Preparation of explants.** The cartilage samples were punched aseptically using a steel punch. The punch with a diameter of 2 mm was used to remove equal cores of cartilage [16, 17]. After punching out, the uniform slices were cultured in serum-free DMEM, containing 2,000 U/mL penicillin G, 0.1 mg/ml streptomycin, 2 mM glutamine, 2.5  $\mu$ g/ml amphotericin B, and 50  $\mu$ g/ml vitamin C for 28 days in 24-well sterile plate at 37°C in a humidified atmosphere of 5% CO<sub>2</sub>, 95% O<sub>2</sub>.

**Induction of cartilage degradation.** The samples were divided into four groups. The explants were cultured in DMEM only, as group A or control group. In group B, the samples were treated with IL-1 $\alpha$  (10 ng/ml, PHC0017, Gibco, USA). In group C, the explants were treated with IL-4 (50 ng/ml, Gibco, PHC0045, USA), and in group D, the pieces were treated with both IL-4 (50 ng/ml) and IL-1 $\alpha$  (10 ng/ml)

for 28 days [16]. At days 3, 7, 14, 21, and 28, media and samples were removed, and the media were frozen and stored at -20°C until analysis [2, 16].

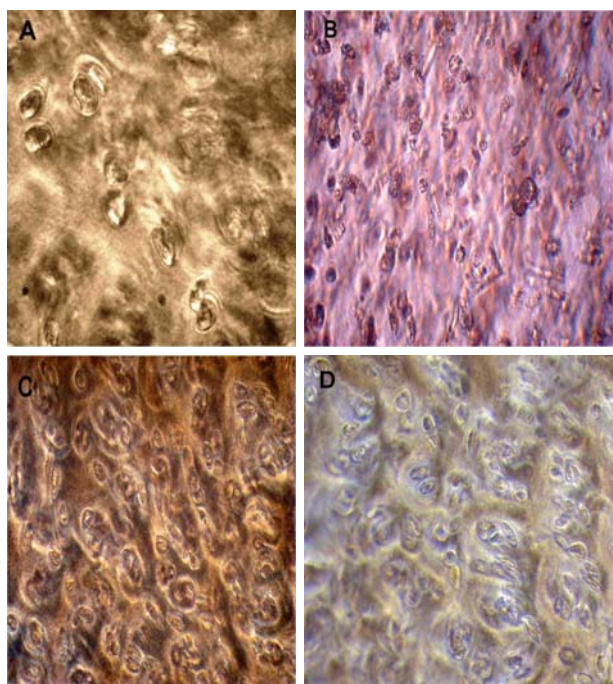
**Morphology assessment.** Morphological alterations of unfixed BNC in the culture media were assessed by using an invert microscope.

**Histology assessment.** The BNC explants in different groups were collected, and morphological alterations were assessed by using histology method and a light microscope after 28 days of culture. Formaldehyde-fixed and paraffin-embedded samples were stained with hematoxylin-eosin method using standard histological techniques [6].

**Alcian blue staining.** Alcian blue was used to visualize the alterations of proteoglycans in different groups. Cartilage explants from each group were taken out of the culture, fixed in formaldehyde, and processed for standard histology staining. The 6- $\mu$ m sections were stained in a 1% solution of Alcian blue in 3% acetic acid for 30 min [18]. Digital histographic images were captured using an Olympus light microscope (Olympus, Japan, magnification 40 $\times$ ).

**Western blotting.** The media of IL-1 $\alpha$  treated group at days 3, 7, 14, 21, and 28 of culture were collected and MMP-1 production was analyzed by using reducing Western blotting. Then, according to optimum results, medium from cartilage explants of different groups on day 21 were harvested, and production of MMP-1 was also analyzed by using reducing Western blotting. Medium samples (20  $\mu$ l) were boiled with 2-mercaptoethanol for 5 min. Next, the samples were separated on 12% SDS-PAGE and electrophoretically transferred to polyvinylidene difluoride membrane. The membrane was blocked in Tris-buffered saline + Tween 20 (TBST) containing 2% BSA at 4°C overnight. It was also probed with rabbit antihuman MMP-1 polyclonal antibody (1:250 dilution, Sc-6837, Santa Cruz Biotechnology, USA) in blocking buffer at room temperature for 8 h. After washing three times for 15 min with TBST, the membrane was incubated for 1 h with goat anti-rabbit IgG-horseradish peroxidase conjugated (1:2000 dilution, sc-2004, Santa Cruz Biotechnology, USA) in TBST [2, 5]. Then, the membrane was washed five times for 15 min in the TBST. The bands of interest were detected by using diaminobenzidine tetrahydrochloride as substrate [5, 16].

**Statistical analysis.** Values are expressed as mean  $\pm$  SEM. The data was compared among groups by using One-way ANOVA by SPSS for windows (version 15)



**Fig. 1.** Chondrocytes morphology in explant culture. (A) Cartilage explant from control group after 28 days; (B) Cartilage explant cultured in the presence of IL-1 $\alpha$ ; the edge of cartilage explants started to become translucent, and chondrocytes showed granular black appearance, and (C and D) Cartilage explant cultured in the presence of IL-4 and IL-1 $\alpha$  + IL-4, respectively. Chondrocytes preserved their normal phenotype (40 $\times$ ).

and followed by post hoc Tukey. The differences were considered significant at  $P < 0.05$ .

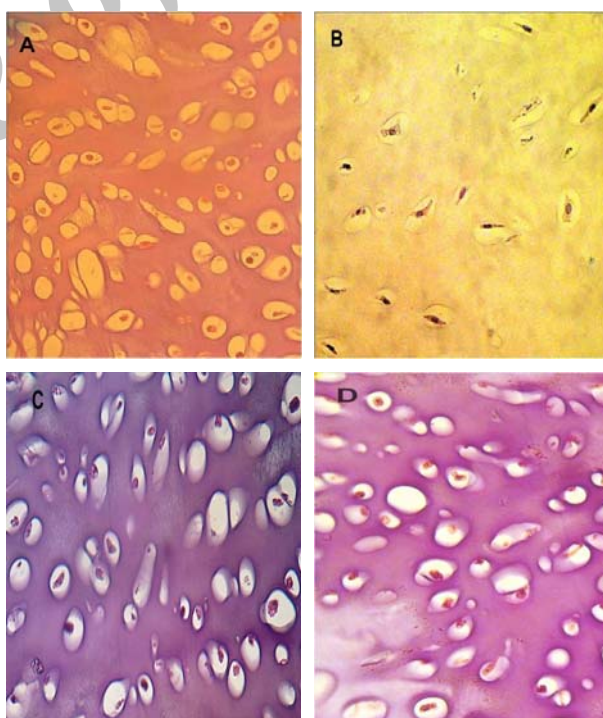
## RESULTS

**Morphological assessment.** Chondrocytes morphology in different groups was assessed by an invert microscope. In control group, chondrocytes showed spherical shape after 28 days of culture (Fig. 1A). In the presence of IL-1 $\alpha$ , most cells showed fibroblast-like morphology. All of the chondrocytes showed a granular black point appearance (Fig. 1B). In the presence of IL-4, chondrocytes preserved their original round morphology. There was little fibroblast-like morphology chondrocytes with a foamy and vacuolated cytoplasm in groups C and D (Fig. 1C and Fig. 1D).

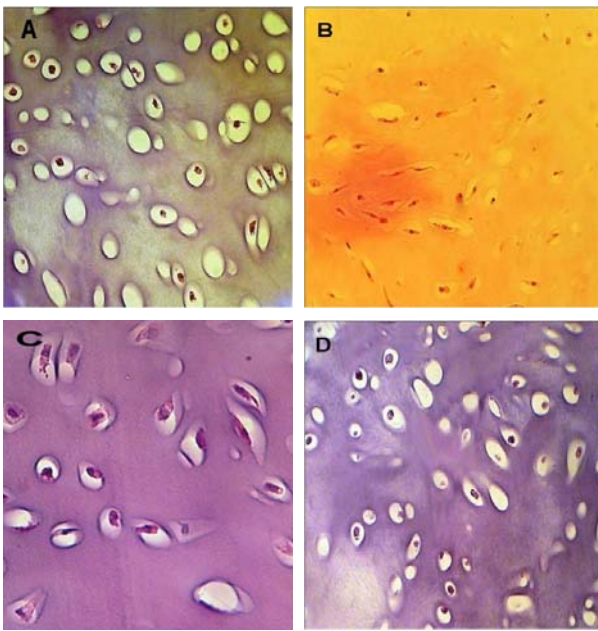
**Tissue changes assessment.** Tissue destruction and morphological alterations of BNC explants in different groups were also assessed by using hematoxylin-eosin staining after 28 days of culture (Fig. 2). Specimens from control group showed a normal morphologic appearance (Fig. 2A). In group B, morphology of chondrocytes was modified and most chondrocytes

transformed into elongated fibroblast-like morphology with pyknotic nuclei. Some chondrocytes showed vacuolated eosinophilic cytoplasm and nuclei dislocation (Fig. 2B). In group C, most chondrocytes showed normal features (Fig. 2C). In group D, there were few numbers of fibroblast-like chondrocytes with pyknotic nuclei compared with IL-1 $\alpha$ -treated group and most chondrocytes showed a normal morphology phenotype (Fig. 2D).

**ECM change evaluation.** To show the ECM alteration in cartilage explants, histology method was performed on explants in different groups at day 28 by using Alcian blue staining method (Fig. 3). In group A, there was relatively an intensive staining of proteoglycan (Fig. 3A). The intensity of the staining was very weak in explants stimulated with IL-1 $\alpha$  (group B), dark blue staining completely disappeared and ECM showed degenerative appearance (Fig. 3B). In group C, ECM explants showed an intensive staining of proteoglycan (Fig. 3C). In group D, matrix was significantly stained with alcian blue, and increased pericellular matrix staining as compared with IL-1 $\alpha$  group and ECM was intact (Fig. 3D).



**Fig. 2.** Light microscopy of morphological alteration of BNC explants in different groups, hematoxylin-eosin staining. (A) In control group, chondrocytes showed round shape; (B) In the presence of IL-1 $\alpha$ , most chondrocytes transformed into fibroblast-like with pyknotic nuclei, and chondrocytes showed vacuolated eosinophilic cytoplasm; (C) In IL-4 group, most chondrocytes showed round normal shape, and (D) In the presence of both IL-1 $\alpha$  and IL-4, there were few pyknotic nuclei in comparison with IL-1 $\alpha$ -treated group (40 $\times$ ).



**Fig. 3.** Light microscopy of proteoglycan alteration of BNC explants in different groups, and alcian blue staining. (A) In control group, there was relatively an intensive staining of proteoglycan; (B) In IL-1 $\alpha$ -treated group, dark blue staining completely disappeared, and ECM was degenerative; (C) In the presence of IL-4 alone, there was an intensive staining of proteoglycan, and ECM was intact, and (D) In the presence of both IL-1 $\alpha$  and IL-4, matrix stained significantly with Alcian blue (40 $\times$ ).

**Detection of MMP-1 in the media of IL-1 $\alpha$ -treated group.** The media of IL-1 $\alpha$ -treated groups from days 3, 7, 14, 21, and 28 of culture were collected and subjected to reducing Western blot analysis. The pro-


MMP-1 band was very weak during the first three days of culture with IL-1 $\alpha$ , but pro-MMP-1 showed a clear band from day 7, and its releasing between days 14 to 21 was prominent. After day 21, pro-MMP-1 detection was reduced gradually. At day 21 of culture, when cartilage degradation was apparent, pro-MMP-1 (higher apparent molecular weight band, 84 kDa) and active MMP-1 (lower apparent molecular weight band, 66 kDa) were both detected in IL-1 $\alpha$  group (Fig. 4).

**Detection of MMP-1 in the media of different groups.** According to optimum results of IL-1 $\alpha$ -treated group, samples at day 21 of culture in different groups were also analyzed by reducing Western blotting. No band of MMP-1 was detected in control medium (group A) and in the presence of IL-4 alone (group C). In group D, just very weak band of pro-MMP-1 (84 kDa) was detected, but in group B, a clear band of MMP-1 was recognized (Fig. 5).


## DISCUSSION

In the current study, we have used IL-4 against tissue degradation induced by IL-1 $\alpha$ . The results showed that IL-4 significantly preserved the cartilage normal morphological characteristics and suppressed degradation effects of IL-1 $\alpha$ . In this study, the MMP-1 production has investigated in cartilage degradation by Western blotting.

The stimulation of BNC with IL-1 $\alpha$  represents a reproducible model of the cartilage destruction that is prevalent in the joint diseases [6, 16, 17]. In previous studies, Kozaci *et al.* [6] and Jansen *et al.* [19] have



**Fig. 4.** Western blotting for matrix metalloproteinase-1 (MMP-1) in IL-1 $\alpha$  group at different days. Lane 1, control group which there was not seen any band; lanes 2-6, media taken on days 3, 7, 14, 21, and 28, respectively. The MMP-1 production was very weak during the first three days of culture, but pro-MMP-1 (84 kDa) showed a significant production from day 7, and its expression between day 14 and 21 was prominent. The pro-MMP-1 band was reduced gradually after day 21. The 2 main bands observed at day 21 of culture are consistent with pro and active form of MMP-1, respectively.



**Fig. 5.** Western blotting for matrix metalloproteinase-1 (MMP-1) in different groups at day 21. Lane 1, control group, and no band was detected; lane 2, media taken from IL-4-treated group, and no band was detected; lane 3, media taken from both IL-4 and IL-1 $\alpha$ -treated group, and just very weak band of pro-MMP-1 was detected; lanes 4 and 5, media taken from two different samples of IL-1 $\alpha$  alone group, and a clear band of MMP-1 was detected.

used IL-1 $\alpha$  (50 ng/ml), and BNC was almost completely degraded within 21 and 18 days, respectively. In the present investigation, the lower concentration of IL-1 $\alpha$  (10 ng/ml) was used for 28 days as used for other groups [16, 20]. In the presence of IL-1 $\alpha$ , most chondrocytes showed a fibroblast-like morphology with pyknotic nuclei. These findings are in agreement with Kozaci *et al.* [6] result declared that such phenotypic nuclei in BNC cultured with IL-1 $\alpha$  (50 ng/ml) may be because of degenerating cells. In the current work, IL-1 $\alpha$  also caused increased vacuolated eosinophilic cytoplasm in some chondrocytes that probably is related to the presence of acidic organelles (lysosomes or secretory vesicles) in the cytoplasm. Kozaci *et al.* [6] concluded that these staining are because of increased lysosomal activity in the presence of IL-1 $\alpha$ .

In the present survey, IL-4 preserved round morphology of chondrocytes and few numbers of cells showed a fibroblast-like shape with pyknotic nuclei. It has been previously demonstrated that fibroblast-like chondrocytes are dedifferentiated, and the round morphology is essential to support the chondrocyte phenotype [21, 22]. IL-4 addition modulated the dedifferentiation and preserved the chondrocytes normal morphology as compared with IL-1 $\alpha$  group. These results are in agreement with our previous study results [16] and Joosten *et al.* [11] study, proposed that IL-4 could preserve chondrocytes from death.

Observations related to IL-4 effects on proteoglycans alterations differ widely. Previous studies have shown that early proteoglycan loss is mediated by aggrecanase, whereas erosive late proteoglycan destruction is linked to MMP-3 [21-24]. It has been also demonstrated that IL-4 down-regulates both

MMP-3 and collagenase synthesis, thereby contributes to inhibition of cartilage proteoglycan degradation [21-24]. On the other hand, a number of studies have reported that IL-4 does not protect cartilage against proteoglycan degradation, because IL-4 has no major suppressive effect on aggrecanase [11, 14, 15]. The above mentioned controversy prompted us to evaluate the effects of IL-4 against proteoglycan degradation. In the present research, IL-4 significantly decreased BNC proteoglycan degradation induced by IL-1 $\alpha$ . Increased pericellular matrix staining showed a new proteoglycan synthesis around chondrocytes and possibly reflects the repairing effects of IL-4.

Regulation of MMP is critical to the turnover of the ECM. All MMP are synthesized in a pro form that requires the proteolytic removal of a prodomain to generate the active form of enzyme [4, 5]. Previous studies have shown that MMP-1 is upregulated when cartilage is cultured in the presence of proinflammatory cytokines, but MMP-1 must be activated before collagen degradation proceeds [4, 5]. Kozaci *et al.* [2] have reported that in cultures of BNC with IL-1 $\alpha$  (50 ng/ml), proenzyme, active enzyme, and superactive form of MMP-1 were detected in BNC explants culture particularly at week 3 of culture. In the current study, between day 3 and 21 of culture, there was only pro-MMP-1 releasing into the culture medium. At day 21 of culture, both pro and active form of MMP-1 were detected in IL-1 $\alpha$ -treated group. In this day, when active MMP-1 was released into the medium, chondrocyte morphological changes were significantly apparent, and cartilage degradation was prominent. These findings are in agreement with Kozaci *et al.* [2] results. They concluded that the increased MMP activity at week 3 of culture should result from

increased synthesis of pro-MMP proteins as well as decreased synthesis of MMP inhibitors.

A few previous studies have indicated that IL-4 markedly decreased MMP-1, MMP-3, and MMP-13 in inflammatory cytokines-treated chondrocytes, but it is unclear how IL-4 can modulate MMP activity [4, 15]. In the our study, in the presence of IL-4 (50 ng/ml) active MMP-1 was not detectable. On the other hand, IL-4 decreased pro-MMP-1 production into the medium, suggesting that IL-4 can decrease pro-MMP-1 and inhibit MMP-1 activation. A previous work has shown that pro-MMP activation is an important control point in cartilage breakdown [25]. Therefore, the present findings could complete and add more details of IL-4 effects on MMP regulation. Cleaver *et al.* [4] demonstrated that IL-4 can prevent activation of pro-MMP-1 by down-regulation of an enzyme present in the activation cascade, and/or by promoting local levels of tissue inhibitors of metalloproteinase, thus preventing matrix turnover. The findings of the current study are in agreement with our previous work [16] that IL-4 inhibited activation of MMP-1 and decreased production of latent MMP-1 into the medium. These findings suggest that there is a relationship between MMP-1 inhibition and protective effect of IL-4 on chondrocyte morphology.

In conclusion, the results of the present study suggest that IL-4 involves in a chondroprotective manner by (a) inhibiting the production of an active MMP-1 that is released from the cartilage, (b) reducing the production of pro-MMP-1, that is released from the cartilage, (c) inhibiting proteoglycan degradation from BNC, and (d) preserving chondrocyte morphology in an original normal phenotype. Therefore, these data propose that anti-inflammatory cytokines could be an effective candidate for therapeutic methods in arthritis diseases. Further studies are required to clear the effects of IL-4 on tissue inhibitors of metalloproteinase by Western blotting and assay its effects on chondrocyte morphology by electron microscopy.

#### ACKNOWLEDGMENTS

The present study, which is a part of the research project (No. CMRC-18) and also a Ph.D. thesis of Maryam Yadegari, has been financially supported by the Research Deputy of Ahvaz Jundishapur University of Medical Sciences, Ahvaz, Iran.

#### REFERENCES

- Gabriel SE, Michaud K. Epidemiological studies in incidence, prevalence, mortality, and co morbidity of the rheumatic diseases. *Arthritis Res Ther.* 2009; 11(3):229.
- Kozaci LD, Buttle DJ, Hollander AP. Degradation of type II collagen, but not proteoglycan, correlated with matrix metalloproteinase activity in cartilage explant cultures. *Arthritis Rheum.* 1997 Jan; 40(1):164-74.
- Englund M, Jöud A, Geborek P, Felson DT, Jacobsson LT, Petersson IF. Prevalence and incidence of rheumatoid arthritis in southern Sweden 2008 and their relation to prescribed biologics. *J Rheumatol.* 2010 Aug; 49(8):1563-9.
- Cleaver CS, Rowan AD, Cawston TE. Interleukin 13 blocks the release of collagen from bovine nasal cartilage treated with proinflammatory cytokines. *Ann Rheum Dis.* 2001 Feb; 60(2):150-7.
- Shingleton WD, Ellis AJ, Rowan AD, Cawston TE. Retinoic acid combines with interleukin-1 to promote the degradation of collagen from bovine nasal cartilage: Matrix metalloproteinases-1 and -13 are involved in cartilage collagen breakdown. *J Cell Biochem.* 2000 Sep; 79(4):519-31.
- Kozaci LD, Oktay G, Hollander AP. Effects of interleukin 1(IL1)-induced matrix breakdown on chondrocyte morphology in bovine nasal cartilage explants. *Turk J Vet Anim Sci.* 2005; 29:951-7.
- Cawston TE, Young DA. Proteinases involved in matrix turnover during cartilage and bone breakdown. *Cell Tissue Res.* 2010 Jan; 339(1):221-35.
- Kokebie R, Aggarwal R, Lidder S, Hakimiyani AA, Rueger DC, Block JA, et al. The role of synovial fluid markers of catabolism and anabolism in osteoarthritis, rheumatoid arthritis and asymptomatic organ donors. *Arthritis Res Ther.* 2011 Mar; 13(2):R50.
- Chen Y, Nixon NB, Dawes PT, Matthey DL. Influence of variations across the MMP-1 and -3 genes on the serum levels of MMP-1 and -3 and disease activity in rheumatoid arthritis. *Genes Immun.* 2012 Jan; 13(1):29-37.
- Green MJ, Gough AK, Devlin J, Smith J, Astin P, Taylor D, et al. Serum MMP-3 and MMP-1 and progression of joint damage in early rheumatoid arthritis. *Rheumatology (Oxford).* 2003 Jan; 42(1):83-8.
- Joosten LA, Lubberts E, Helsen MM, Saxne T, Coenen-de Roo CJ, Heinegard D, et al. Protection against cartilage and bone destruction by systemic interleukin-4 treatment in established murine type II collagen induced arthritis. *Arthritis Res.* 1999; 1(1):81-91.
- Goldring MB, Otero M, Plumb DA, Dragomir C, Favero M, El Hachem K, et al. Roles of inflammatory and anabolic cytokines in cartilage metabolism: signals and multiple effectors converge upon MMP-13 regulation in osteoarthritis. *Eur Cell Mater.* 2011 Feb; 21:202-20.
- Wallis SK, Cooney LA, Endres JL, Lee MJ, Ryu J, Somers EC, et al. A polymorphism in the interleukin-4 receptor affects the ability of interleukin-4 to regulate Th17 cells: a possible immunoregulatory mechanism for genetic control of the severity of rheumatoid arthritis. *Arthritis Res Ther.* 2011 Feb; 13(1):R15.
- Borghaei RC, Rawlings PL, Jr, Mochan E. Interleukin-4 suppression of Interleukin-1-induced transcription of collagenase (MMP-1) and stromelysin1(MMP-3) in human synovial fibroblasts. *Arthritis Rheum.* 1998 Aug; 41(8):1398-406.
- Cawston TE, Ellis AJ, Bigg H, Curry V, Lean E, Ward

- D. Interleukin-4 blocks the release of collagen fragments from bovine nasal cartilage treated with cytokines. *Biochim Biophys Acta*. 1996 Dec; 1314(3): 226-32.
16. Yadegari M, Orazizadeh M, Hashemitabar M, Khodadadi A. Combination Effects of Prednisolone and Interleukin-4 Protect Bovine Nasal Cartilage Explants from Interleukin-1 $\alpha$  Induced Degradation. *Iran Biomed J*. 2011; 15(4):143-50.
17. Shohani B, Orazizadeh M, Hashemitabar M, Heinegard D. Degradation of extracellular matrix molecules in interleukin-1 $\alpha$  treated bovine nasal cartilage. *Iran Biomed J*. 2010 Oct; 14(4):158-63.
18. Karsdal MA, Madsen SH, Christiansen C, Henriksen K, Fosang AJ, Sondergaard BC. Cartilage degradation is fully reversible in the presence of aggrecanase but not matrix metalloproteinase activity. *Arthritis Res Ther*. 2008; 10(3):R63.
19. Jansen ID, Hollander AP, Buttle DJ, Everts V. Type II and VI collagen in nasal and articular cartilage and the effect of IL-1 $\alpha$  on the distribution of these collagens. *J Mol Histol*. 2010 Feb; 41(1):9-17.
20. Torzilli PA, Bhargava M, Parkz S, Cheny CT. Mechanical load inhibits IL-1 induced matrix degradation in articular cartilage. *Osteoarthritis Cartilage*. 2010 Jan; 18(1):97-105.
21. Orazizadeh M, Hashemitabar M, Fakoore M, Moghadam MT. Effect of bone morphogenetic protein-2 on normal and osteoarthritic human articular chondrocytes. *Pak J Biol Sci*. 2009 Sep; 12(17):1194-9.
22. Brodtkin KR, Garcia AJ, Levenston ME. Chondrocyte phenotypes on different extracellular matrix monolayers. *Biomaterials*. 2004 Dec; 25(28):5929-38.
23. Nemoto O, Yamada H, Kikuchi T, Shinmei M, Obata K, Sato H et al. Suppression of matrix metalloproteinase -3 synthesis by interleukin-4 in human articular chondrocytes. *J Rheumatol*. 1997 Sep; 24(9):1774-9.
24. Van de Loo FA, Arntz OJ, Enckevort FH, van Lent PL, van den Berg WB. Reduced cartilage proteoglycan loss during zymosan induced arthritis in NOS-2 deficient mice and in anti-interleukin-1 treated wild type mice with unabated joint inflammation. *Arthritis Rheum*. 1998 Apr; 41(4):634-46.
25. Milner JM, Elliott SF, Cawston TE. Activation of procollagenases is a key control point in cartilage collagen degradation: interaction of serine and metalloproteinase pathways. *Arthritis Rheum*. 2001 Sep; 44(9):2084-96.