

Splenic Actinomycosis: Unusual Presentation

N. Azarpira, B. Ghasemzadeh

Abstract

Splenic abscess is not a common condition and actinomycosis as a cause is very rarely reported. We report a case of actinomycosis of spleen in a 12 year-old boy, with a few days history of abdominal pain and fever. Past medical history was not significant. Due to sever abdominal pain and tenderness condition laparotomy was done that a small perforated area was seen on hilum of spleen, so splenectomy was done. In the histological sections typical actinomycetes ball surrounded by many inflammatory cells are seen. The patient received penicillin and discharged in a good condition. This has not been previously reported in the pediatric literature.

Iran J Med Sci 2005; 30(3): 141-143.

Keywords • Spleen • actinomycosis • splenectomy

Introduction

Actinomycetes are slow growing, Gram positive, non acid fast, anaerobic, commensal bacteria within oral cavity (tonsillar crypt and teeth), colon and vagina. Their filamentous structure gives them a fungus-like appearance. Mucosal disruption may lead to infection at virtually any site in the body. *In vivo* growth of actinomycetes usually results in the formation of characteristic clumps called grains or sulfur granules. Actinomycosis is not an opportunistic infection and usually occur in healthy individuals, however an increasing number of reports have described an association with HIV infection, transplantation and radio-or chemotherapy.¹ Actinomycosis occurs worldwide without relation to age, race, season, or occupation.² Males have a higher incidence of infection than female, possibly because of poorer dental hygiene and/or more frequent trauma.¹ This infection is commonly seen and reported in craniofacial, ileocecal, pulmonary regions and the vaginal smear of intrauterine device users. It is also reported rarely at other sites such as liver, breast, parotid, muscle, prostate and spleen. Penicillin continues to be the standard treatment for actinomycosis.²

Case report

A 12-year-boy from rural area of South of Shiraz was presented to Nemazee Hospital, affiliated to Shiraz University of Medical Science, Shiraz Iran, with one week history of anorexia, fever and abdominal pain. The pain was constant and located in the left upper quadrant. In past medical history, there was no evidence of recurrent prolonged infection or exaggerated response to live virus or attenuated bacterial vaccines. He had no recent illness, any signs of trauma, nausea, vomiting or diarrhea. On initial examination in the Emergency Room his temperature was 39.5°C, heart rate 95/min, respiratory rate 22/min and blood pressure 118/80 mmHg. In physical examination his chest

Organ Transplant Research Center,
Department of Pathology,
Nemazee Hospital,
Shiraz University of Medical Sciences,
Shiraz, Iran.

Correspondence:

Negar Azarpira MD,
Transplant Research Center,
Nemazee Hospital,
Shiraz University of Medical Sciences,
Shiraz, Iran.

Tel/Fax: +98 711 6276211

E-mail: negarazarpira@yahoo.com



Fig 1: Macroscopic appearance of the splenic abscess in cut section.

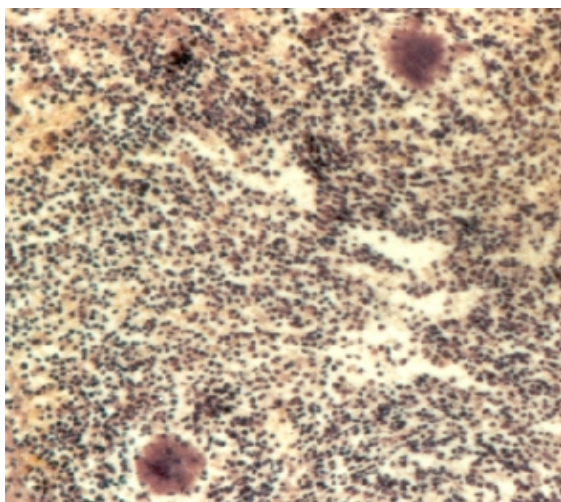


Fig 2: Low power view of spleen shows ball of actinomycetes surrounded by neutrophils (H/E staining, x100).

and urine were negative. Chest X-ray and abdominal sonography were normal.

Due to aggravated condition with impression of generalized peritonitis, the patient underwent laparotomy and splenectomy. Grossly there was a necrotic area in the hilum of the spleen with the ruptured splenic capsule (Fig 1). Histological examination showed a mixed inflammatory infiltration, mainly by neutrophils surrounding the typical ball of actinomycosis (Figs 2 and 3) which is the typical histological feature of actinomycosis. After all, the patient admitted and received crystalline penicillin G.

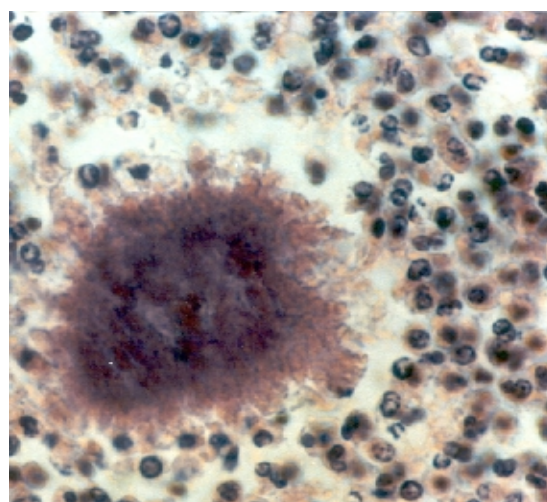


Fig 3: High power view of aggregation of actinomycosis in inflammatory background (H/E staining x400).

was clear to auscultation and no cardiac murmur was audible. The abdomen was tender in left upper quadrant with rebound. The liver was palpable one cm below costal margin with no splenomegaly or other abdominal mass. There were no accessible lymph nodes, and abdominal examination was negative for splenomegaly. Neurological examination was normal.

Clinical laboratory studies revealed a white blood cell count of 10,000/ μ l with 95% neutrophils, 3% lymphocytes, 2% monocytes; hemoglobin of 10.5 g%; and a platelet count 230,000/ μ l. The aspartate and alanine aminotransferases were 30 IU/l and 28 IU/l respectively. The erythrocyte sedimentation rate was 10 mm/h and C-reactive protein was negative. The serum sodium and potassium levels were 129 and 2.6 mmol/l respectively. The liver and kidney function tests were within normal limit. Because of the obscure nature of the fever, multiple diagnostic tests were performed. Serologies for *Brucella* and *Salmonella* were negative. Routine cultures of blood, feces

Discussion

Splenic abscess, an extremely rare condition, can be the result of trauma or metastatic spread of infection from other sites such as the heart in subacute bacterial endocarditis.³ Splenic actinomycosis is very rarely reported in literature.⁴⁻⁷ The usual sites of actinomycosis are cervicofacial, respiratory and digestive tract.^{8,9} The most common actinomycococ species causing human disease is *Actinomyces israelii*.¹⁰ Their identification needs a strict anaerobic environment on an enriched media and observation for at least one week but may take as long as 2 to 4 weeks.^{1,10}

Recognized routes of entry of cervicofacial actinomycosis include dental caries, or tooth extraction.¹¹ It can also occur as a complication of trauma to the respiratory and digestive tracts including operative procedures. Aspiration and biopsies are being used successfully to obtain clinical material for diagnosis, although surgery may be required.¹ A prolonged course of antibiotic therapy is recommended, but the exact

duration of therapy depends on the site and severity of the disease.¹²⁻¹⁵

In our case the patient was immunocompetent, and there were no previous history of falling down, maxillofacial manipulation or abdominal surgery. According to the clinical presentation and physical findings other causes of acute abdomen such as intussusception, volvulus or rarely hollow viscus obstruction were suspected. What is unique about our patient is that we never clinically suspected actinomycosis and the diagnosis was confirmed by histological examination. Splenectomy helped for the diagnosis of actinomycosis and relieved him from fever.

References

- 1 Russo TA. Actinomycosis. In: Kasper DL, Longo DL, Fauci ANS, Harrison's principles of internal medicine. Mc Graw-Hill; 2005. p. 937-9.
- 2 Jacobs RF, Schutze GE. Actinomyces. In: Behrman RE, Kliegman RM, Jenson HB. Nelson textbook of pediatrics. Saunders Philadelphia; 2004. p. 892-4.
- 3 Briggs RD, Davidson AI, Fletcher BR. Solitary abscess of spleen. *J R Coll Surg Ed-inb* 1997; 22: 345-7.
- 4 Chen CY, Chen YC, Tang JL, et al. Splenic actinomycotic abscess in a patient with acute myeloid leukemia. *Ann Hematol* 2002; 81: 532-4.
- 5 Quintero-Del-Rio AI, Trujillo M, Fink CW. Actinomycotic splenic abscess presenting with arthritis. *Clin Exp Rheumatol* 1997; 15: 445-8.
- 6 Chan PM, Chong SM, Ng BK, Chan ST. Splenic actinomycosis. *J R Coll Surg Ed-inb* 1999; 44: 344-5.
- 7 Gaurdo E, Rebollo M, Asencio MA, et al. Splenic abscess caused by Actinomycosis meyeri in a patient with autoimmune hepatitis. *Diagn Microbiol Inf Disease* 2000; 37: 213-4.
- 8 Kumar PV, Javid SA, Bedayat GR, Amrolahi A. An unusual case of actinomycosis diagnosed by fine needle aspiration cytology. *Acta cyto* 1990; 34: 408-10.
- 9 Miyamoto MI, Fang, FC. Pyogenic liver abscess involving Actinomyces. Case report. *Clin Infect Dis* 1993; 16: 303-9.
- 10 Gail BS, Woods L. Medical bacteriology. In: Henry JB, Clinical diagnosis and management by laboratory methods, W.B. Saunders Philadelphia; 2001. p. 1099 -100.
- 11 Ermis I, Topalan M, Aydin A, Erer M. Actinomycosis of frontal and parotid regions. *Ann Plast Surg* 2001; 46: 55- 8.
- 12 Apotheloz C, Regamey C. Disseminated infection due to Actinomyces meyeri. Case report and review. *Clin Infect Dis* 1996; 22: 621-5.
- 13 Edelman M, Cullmann W, Nowak KH, Kozuschek W. Treatment of abdominothoracic actinomycosis with imipenem. *Eur J Clin Microbiol* 1987; 6: 194-5.
- 14 Yew WW, Wong PC, Wong CF, Chau CH. Use of imipenem in the treatment of thoracic actinomycosis. *Clin Infect Dis* 1994; 19: 983-4.
- 15 Hamed KA. Successful treatment of primary actinomyces viscous endocarditis with third-generation cephalosporins. *Clin Infect Dis* 1998; 26: 211-2.