

Postoperative Respiratory Distress in a Patient with History of Familial Mediterranean Fever

A.R. Mahoori, H. Noroozina, A. Sina¹,
S.H. Nowruzinia²

Abstract

Postoperative respiratory distress and pulmonary edema can be seen after a wide variety of serious clinical situations, or rare diseases such as familial Mediterranean fever (FMF). FMF is a multisystemic disorder characterized by recurrent bouts of fever and pain due to inflammation of the peritoneum, synovia, or pleura. We report a case with history of FMF who developed postoperative respiratory distress after repairing the abdominal incisional hernia. Ten hours after administration of colchicine, the patient's symptoms were reduced. This rare disease should be included as a differential diagnosis for acute-onset respiratory distress in postoperative period.

Iran J Med Sci 2008; 33(1): 60-62.

Keywords • Postoperative period • pulmonary edema • familial Mediterranean fever

Introduction

Postoperative respiratory distress and pulmonary edema are seen after a wide variety of serious clinical situations such as left ventricular failure, hypertension, shock, trauma, massive transfusion, sepsis, anaphylaxis, and other rare diseases such as familial Mediterranean fever (FMF).¹

FMF is a genetic multisystemic disorder of unknown etiology characterized by recurrent bouts of fever and pain due to inflammation of peritoneum, synovia, or pleura.² Patients are symptom-free between the episodes, which usually occur at irregular and unpredictable intervals. The disease is restricted mainly to certain ethnic groups of Mediterranean and Middle Eastern origin.^{3,4} The disease is most prevalent among non-Ashkenazi Jews, Arabs, Turks and Armenians, with carrier frequencies of 1:5 to 1:16, 1:5, 1:5, and 1:7, respectively. Yet, it is observed worldwide due to the extensive population movements of the 20th century.⁵

We report a case with history of episodic abdominal pain who developed postoperative respiratory distress two hours after repairing abdominal incisional hernia.

Case Report

A 45-year-old man was referred to us for surgical repairing of abdominal incisional hernia. The patient had a history of uneventful cholecystectomy two years ago. He was a known case of FMF and under treatment with colchicine. Since second decade of life, he had experienced one or two attacks of abdominal pain annually, lasting from a few hours to two days. Because of long remissions in the last few years, he used the drug irregularly. But he did not mention that preoperatively. He had not history of cardiac or respiratory problems. Chest radiograph and

Departments of Anesthesiology and
¹Radiology,
Urmia University of Medical Science,
Urmia, Iran.
²Anesthesiologist of Imam Reza Hospital,
Urmia, Iran.

Correspondence:

Ali Reza Mahoori MD,
Department of Anesthesiology
Urmia University of Medical Sciences,
Urmia, Iran.
Tel: + 98 441 3468967
Fax: + 98 441 3468967
Email: alimahoorir@yahoo.com

electrocardiogram were normal in perioperative assessment (figure 1). There were no abnormalities in laboratory tests.

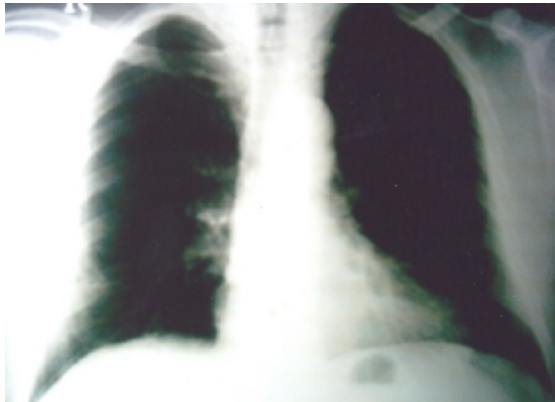


Figure 1: Normal chest radiograph before operation.

Anesthesia and surgery were uneventful and after gentle tracheal extubation he was transferred to the recovery room. Fluid replacement during operation was appropriate. The patient was discharged from the recovery room after full awaking and orientation. Two hours later, he developed unilateral pleuretic pain in right side of the chest. He had shortness of breathing and restlessness. Heart rate and body temperature increased and SaO_2 was 90-92% with O_2 supplement. So the patient was transferred to the intensive care unit. After conservative treatment, chest radiograph and electrocardiogram were obtained. The electrocardiogram showed right axis deviation and the chest radiograph showed bilateral pleural effusion and diffused infiltration (figure 2). Thoracentesis demonstrated an exudative fluid rich in neutrophils. There was no evidence of pulmonary embolism in perfusion scan. The patient had also leukocytosis, elevated C-reactive protein, and mild compensated respiratory acidosis. Ten hours after administration of oral colchicine (10 mg), symptoms of the patient were reduced and he was discharged from intensive care unit in the following day.

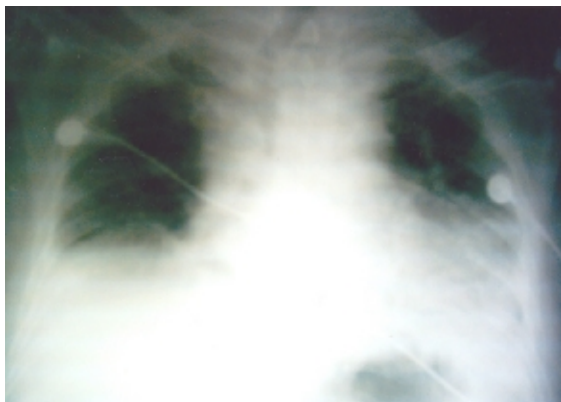


Figure 2: Bilateral pleural effusion and diffused infiltration in the chest radiograph 2 hours after operation.

Discussion

The FMF is characterized by fever, acute abdominal pain, pleural pain, and arthralgia due to inflammation of the peritoneal, pleural, and synovial membranes. Other less common acute manifestations are skin-related signs such as erysipelas-like erythema, nodular erythema and urticaria, angio-edema,⁶ acute orchitis,⁷ pericarditis,^{8,9} meningitis, Henoch-Schönlein purpura, polyarteritis nodosa,¹⁰ protracted febrile myalgia,¹¹ and glomerulonephritis.¹²

Abdominal pain is the most common presenting feature of FMF, eventually occurring in 95% of patients. The abdominal pain may be diffuse or localised, and varies in intensity from mild, without overt signs of peritonitis, to the more typical severe pain, which necessitates bed rest. It is exacerbated by breathing and accompanied by signs of peritoneal inflammation. Attacks begin suddenly, usually without a recognisable precipitating event and last for 6 to 96 hours. Women of child-bearing age may note a tendency for attacks to occur around menstruation.²

Chest attacks, due to inflammation of the pleura, are reported by 30% of the patients. Usually they are similar to abdominal and joint attacks and will resolve within hours to several days.² Pleural attacks are usually manifested by unilateral, sharp, stabbing chest pain. Radiographs may show atelectasis and sometimes an effusion. Thoracentesis demonstrates an exudative fluid rich in neutrophils. After repeated attacks, pleural thickening may develop.¹³

For typical cases, experienced physicians can often make the diagnosis on clinical grounds alone. Clinical criteria for FMF have been shown to have high sensitivity and specificity in parts of the world where the pretest probability of FMF is high. In these cases clinical judgment is very important, and sometimes a therapeutic trial of colchicine may help to confirm the diagnosis.¹³

Laboratory features of FMF attacks are consistent with acute inflammation and include an elevated erythrocyte sedimentation rate, leukocytosis, and elevations in the C-reactive protein, fibrinogen, haptoglobin, and serum immunoglobulins. Transient albuminuria and hematuria may also be seen.

Our case had postoperative respiratory attack manifested by shortness of breathing, unilateral and sharp chest pain and some non-specific laboratory tests abnormalities such as leukocytosis, elevated C-reactive protein and D-Dimer. Perhaps this attack was related to the stress induced by general anesthesia or surgery.

In conclusion this rare disease should be included as a differential diagnosis for acute-onset respiratory distress in postoperative period.

References

- 1 Feeley TW, Macario A. The post anesthesia Care Unit. In Miller RD: Miller's Anesthesia, 6th ed, Philadelphia, Churchill Livingstone; 2005. p. 2713.
- 2 Sohar MJ, Gafni J, Pras M, Heller H. Familial Mediterranean fever. A survey of 470 cases and review of the literature. *Am J Med* 1967; 43: 227-53.
- 3 Barakat M, Karnick A, Majeed HA, et al. Familial Mediterranean fever (recurrent hereditary polyserositis) in Arabs. A study of 175 patients and review of the literature. *Q J Med* 1986; 60: 837-47.
- 4 Rogers DB, Shohat M, Petersen GM, et al. Familial Mediterranean fever in Armenians: autosomal recessive inheritance with high gene frequency. *Am J Med Genet* 1989; 34: 168-72.
- 5 Kastner DL, Aksentijevich I. Intermittent and periodic arthritis syndromes. In: Koopman WJ, Moreland LW, eds. Arthritis and Allied Conditions (15th ed). Philadelphia: Lippincott Williams and Wilkins; 2005. p. 1411-61.
- 6 Schwabe AD. Recurrent polyserositis (Familial Mediterranean fever). In Haubrich WS, Schaffner F, Berk JE. Gastroenterology. Philadelphia. WB Saunders Co; 1995. p. 3097-105.
- 7 Eshel G, Zemer D, Bar-Yochai A. Acute orchitis in familial Mediterranean fever. *Ann Intern Med* 1988; 109: 164-5.
- 8 Tutar HE, Imamoglu A, Atalay S. Recurrent pericarditis in familial Mediterranean fever. *Acta Paediatr* 1999; 88: 1045-6.
- 9 Zimand S, Tauber T, Hegesch T, Aladjem M. Familial Mediterranean fever presenting with massive cardiac tamponade. *Clin Exp Rheumatol* 1994; 12: 67-9.
- 10 Glikson M, Galun E, Schlezinger M, et al. Polyarteritis nodosa and familial Mediterranean fever: a report of 2 cases and review of the literature. *J Rheumatol* 1989; 16: 536-9.
- 11 Langevitz P, Zemer D, Livneh A, et al. Protracted febrile myalgia in patients with familial Mediterranean fever. *J Rheumatol* 1994; 21: 1708-9.
- 12 Said R, Hemzeh Y, Said S, et al. Spectrum of renal involvement in familial Mediterranean fever. *Kidney Int* 1992; 41: 414-9.
- 13 Casper DL, Fauci AS, Braunwald E, et al. Harrison's Principles of Internal Medicine. 16th ed, MC Graw-Hill; 2005. p. 1793-95.