

Correlation between p33ING1b Cytoplasmic Transfer and Lymph Node Metastasis in Oral Squamous Cell Carcinoma

R.D. Farhadieh, R. Smee,
A. Salardini³, K. Ow¹, J.L. Yang²,
P.J. Russell¹

Abstract

Background: Oral squamous cell carcinoma is the sixth most common malignancy in the world today. ING1b/p33 is a newly-discovered tumor suppressor which enhances p53 activity. Transfer of p33 protein from nucleus to cytoplasmic compartment has been previously reported in leukemias. The objective of this study was to determine the correlation between p33ing1b cytoplasmic transfer and lymph node metastasis in oral squamous cell carcinoma.

Methods: Fifty seven patients treated with surgery alone or surgery and adjuvant radiotherapy for primary oral squamous cell carcinoma were enrolled into this study. Immunohistochemical expression of all of the above-mentioned markers was studied.

Results: Analysis of the sections demonstrated that p53 and MDM2 were expressed in 45.6% and 68.4% of patients, respectively. p33ING1b nuclear expression was completely absent while cytoplasmic translocation was noted in 78.9% of cases. Positive cytoplasmic expression of p33ING1b correlated with increased risk of lymphatic metastasis ($p=0.04$). No further correlation with overall disease recurrence or survival was noted.

Conclusion: Apparently, p33ING1b cytoplasmic transfer correlates with lymph node metastasis in oral squamous cell carcinoma.

Iran J Med Sci 2008; 33(1): 27-32.

Keywords • Oral cancer • p33 (ING1b) protein • lymph node metastasis

Introduction

Head and Neck squamous cell carcinoma (HNSCC) represents approximately 5% of all newly-diagnosed cancer cases in the Western world.¹ Long-term survival of these patients has been changed little during the last two decades.² Local and regional tumor recurrence is the major factor for this lack of progress.^{3,4} Despite our vastly improved understanding of cancer biology during recent years, discovery of a biomarker able to reliably predict the risk of cancer recurrence or new cancers has been proved elusive.

Development of head and neck cancer is a multi-step process which involves loss of key regulatory genes.⁵ The tumor suppressor gene p53 located on the short arm of chromosome

Departments of Radio-Oncology,
¹Surgery,
Prince of Wales Hospital, UNSW,
Randwick 2031,
Sydney, Australia.
Division of Medicine Yale University,
USA.

Correspondence:

Ross D Farhadieh BSc(Med)Hons MB BS
Department of Radio-Oncology
Prince of Wales Hospital
High St Randwick, 2031
Sydney, Australia.
Tel: +61 2 93822595
Fax: +61 2 93822550
Email: rostam74@yahoo.com.au

17 encodes a 53-kDa protein which plays a central role in genomic stability, cell differentiation, cell cycle arrest, DNA repair and apoptosis.^{6,7} Dysfunction of this gene, owing to mutation, is the most common abnormality detected in human cancers.⁸ In most studies of HNSCC however, p53 expression alone has not been correlated with the prognosis.⁹⁻¹²

Murine double minute 2 (MDM2) protein and a recently-discovered tumor suppressor p33ING1b are involved in regulation of p53 protein levels. The exact mechanism of action of p33ING1b is not clear yet, however, it appears to stabilize and enhance intra-nuclear expression of the p53 protein, at least in part by antagonizing MDM2-related negative regulation of p53 expression.¹³⁻¹⁵

The objective of this study was to assess the combined status of p53, MDM2 and p33 expression and their possible correlation to clinico-pathologic factors in a cohort of patients with oral cancer.

Materials and Methods

Patients

Fifty-seven patients who were treated at the Otolaryngology and Radio-Oncology Units of Prince of Wales Hospital (POWH) for primary oral squamous cell carcinoma of tongue and floor of mouth were enrolled into this study. The clinico-pathologic characteristics of this series are summarized in table 1. Patients were treated with either surgery alone or surgery with adjuvant radiotherapy. In all patients, the margins of resection were microscopically negative for tumor. The mean clinical follow-up was 65.80±53.60 (range: 3–258) months.

AJCC/UICC TNM and stage classifications were used in this study. Ethics approval was obtained from the South East Area Health Services (SEAHHS) Ethics Committee in accordance to National Health and Medical Research Council (NHMRC) guidelines of Australia.

Immunohistochemistry

A standard indirect immunoperoxidase technique was used to evaluate p53, MDM2 and p33ING1b protein expression in paraffin-embedded tissue samples. Breast tumor tissues showing strong immunoreactivity to p53 and MDM2 and normal thymus with p33 antibodies were used as positive control tissues. The method used for antigen retrieval from archival and formalin-fixed tissues was performed with 0.01 M citrate (pH 6) solution. Five-µm-thick sections were dewaxed in histochoice (Amersco) and rehydrated in graded series of ethanol to water. Sections were boiled for 12 min at maximum power in a 1000

Table 1: Clinicopathologic parameters, treatment and outcome of 57 patients with oral squamous cell carcinoma.

	No of Patients	% of Patients
Sex		
Male	40	70.2
Female	17	29.8
Age		
<65	37	64.9
≥65	20	35.1
Tumor Stage		
T1	14	24.6
T2	30	52.6
T3	11	19.3
T4	2	3.5
Lymph Node		
N0	38	66.7
N1-3	19	33.3
Stage		
I	13	22.8
II	22	38.6
III	14	24.6
IV	8	14
Tumor Grade		
Well-differentiated	16	28.1
Moderately-differentiated	34	59.6
Poorly-differentiated	16	28.1
Adjuvant Radiation Therapy		
Yes	20	35.1
No	37	64.9
Recurrence		
Yes	17	29.8
No	40	70.2
Local recurrence		
Yes	10	17.5
No	47	82.5
Nodal recurrence		
Yes	11	19.7
No	46	80.3

W microwave oven followed by 15 min cooling at room temperature and five min washing in water. Endogenous peroxidase was quenched with 0.4% H₂O₂/MeOH for 15 min and washed in two changes of Tris-buffered saline (TBS). Non-specific protein binding was blocked with 2% BSA/TBS for 30 min. The sections were incubated with 1:50 dilution in 0.1% BSA/TBS of mouse monoclonal anti-human p53 (DO1, IgG_{2b}, sc-126, Santa Cruz Biotechnology), MDM2 (1B10, IgM NCL-MDM2, Novocastra) or goat polyclonal anti-human p33ING1b (C-19, IgG, sc-7566) primary antibodies overnight at 4 °C and washed in two changes of TBS/0.01% Tween 20. Mouse IgG_{2b}, IgM and normal goat IgG (Dako, Carpinteria, CA USA) antibodies were used as isotype negative controls for sc-126, NCL-MDM2 and sc-7566, respectively. Negative controls also included immunostaining without the primary antibodies. For visualization of p53 and MDM2 protein expression, the sections were incubated for 30 min with Dako Envision polymer-HRP. For the detection of p33ING1b, the sections were incubated for 30 min with Dako LSAB-HRP. Brown precipitation was visualized by incubating the sections for 5 min in Dako liquid DAB (diaminobenzidine-HRP solution) and thoroughly washed in water. The

sections were then lightly counterstained with hematoxylin, dehydrated in graded series of ethanol, cleared in xylene and cover slipped.

Immunohistochemistry Evaluation

A semi-quantitative analysis of the sections was performed independently by two of the authors (RF and KO). Scores of 1–4 (1: <10%; 2: 10%–30%; 3: 30%–70%; and 4: >70% of cells positive) were given after inspection of multiple high power fields and identifying the pattern of nuclear or cytoplasmic staining. Sections with a score of two or greater were considered positive for p53 and MDM2 and those with a score of three or greater were considered positive for p33ING1b expression.

Statistical Analysis

The data concerning protein expression were presented as positive ($\geq 2^+$) or negative. Kruskal-Wallis or Mann-Whitney U tests were used, where applicable, to analyze the association between protein expression and clinicopathological parameters including tumor size, tumor grade, nodal stage, clinical stage and treatment strategies. For determination of factors related to disease-free survival and overall survival, Cox proportional hazards models (both univariate and multivariate) were used. The probability of patient disease-free and overall survival was calculated using the Kaplan-Meier survival analysis and was compared using the log-rank test. Two-tailed p values <0.05 was considered statistically significant. Statistical analysis was performed by SPSS for

Windows (SPSS Inc, Chicago, IL).

Results

Association between p33ING1b, MDM2 and p53 with clinico-pathologic factors

Tumor samples taken from 57 patients included in the study were used for immunohistochemical analysis. Correlation between expression of the above proteins and clinico-pathologic factors is presented in table 2. Consistent with other studies, p53 in 26(46%) and MDM2 in 39(68%) of 57 patients were positive and expressed in a nuclear distribution within tumor fields (figs 1A and 1B). Furthermore, no statistically significant correlation was found between each of p53 and MDM2 and tumor size ($p=0.184$ and $p=0.606$, respectively), nodal status ($p=0.06$ and $p=0.231$), pathologic stage ($p=0.063$ and $p=0.079$) or tumor grade ($p=0.403$ and $p=0.787$, respectively).

Nuclear expression of p33ING1b protein was entirely absent from tumor samples in this study, consistent with a previous report on expression of p33ING1b in gastro-esophageal adenocarcinomas.¹⁶ However, cytoplasmic expression of p33ING1b was positive in 45 (79%) patients (figs 1C and 1D). No statistically significant correlation was found between cytoplasmic expression of p33ING1b and tumor size ($p=0.569$), tumor grade ($p=0.834$), pathologic stage ($p=0.295$), MDM2 or p53 expression. Only a statistically significant correlation was demonstrated between cytoplasmic p33ING1b expression and nodal state ($P=0.04$).

Table 2: Correlation between cytoplasmic p33ING1b, nuclear MDM2, p53 protein expression and clinicopathologic parameters correlation in 57 patients with oral squamous cell carcinoma.

	Number		p53 (n=57)			MDM2			p33ING1b		
	n=57	%	Negative	Positive	P	Negative	Positive	P	Negative	Positive	P
Tumor Size					0.184			0.606			0.569
T1	14	24.6	6	8		6	8		4	10	
T2	30	52.6	19	11		9	21		7	23	
T3	11	19.3	4	7		3	8		1	10	
T4	2	3.5	2	0		0	2		0	2	
Nodal Stage					0.06			0.231			0.04
N0	38	66.7	24	14		10	28		11	27	
N1-3	19	33.3	7	12		8	11		1	18	
Clinical Stage					0.063			0.079			0.295
I	13	22.8	6	7		6	7		4	9	
II	22	38.6	16	6		3	19		6	16	
III	14	24.6	4	10		7	7		2	12	
IV	8	14	5	3		2	6		0	8	
Tumor Grade					0.403			0.787			0.834
Well-differentiated	16	28.1	7	9		5	11		3	13	
Moderate	34	59.6	21	13		10	24		8	26	
Poor	7	12.3	3	4		3	4		1	6	
Treatment					0.625			0.011			0.594
Surgery	37	64.9	21	16		16	21		7	30	
Surgery + Radiotherapy	20	35.1	10	10		2	18		5	15	

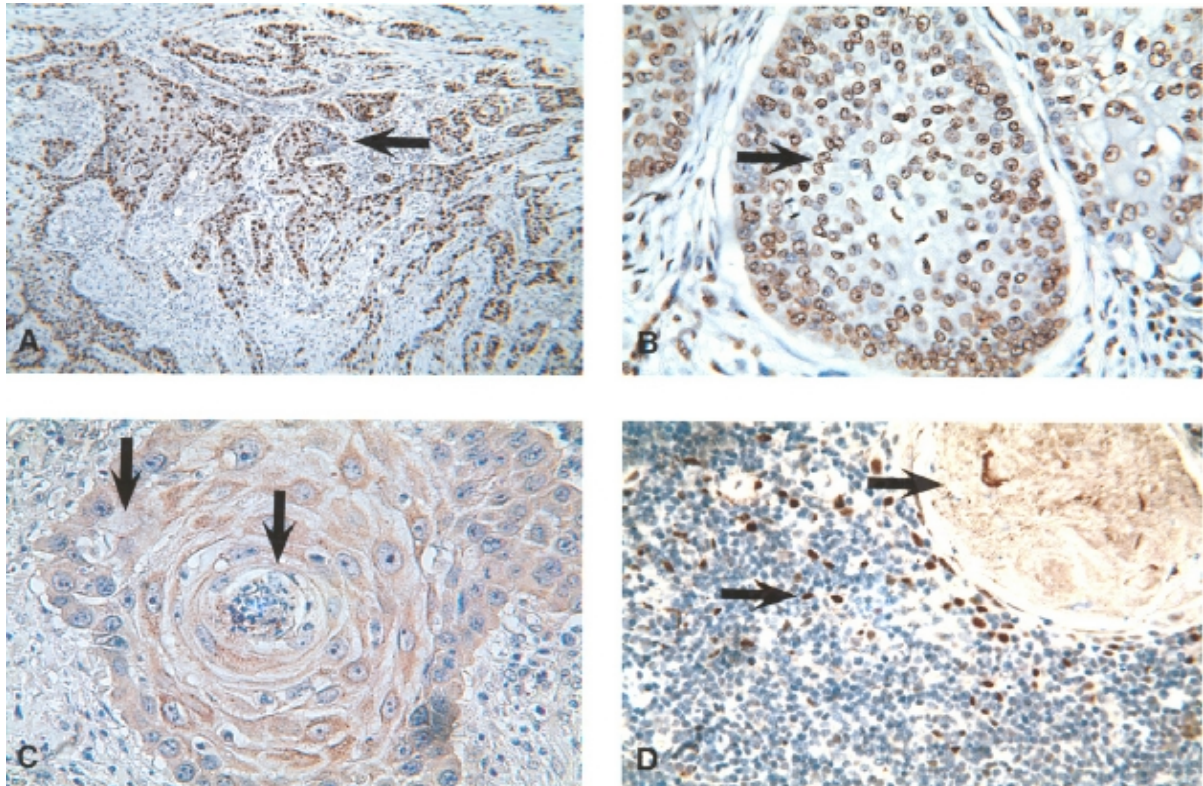


Figure 1: Representative paraffin-embedded tissues were stained according to immunohistochemistry method described (see text). (1A, ×100) Arrow highlighting invasive islands of oral squamous cell carcinoma stained positively for nuclear p53 protein expression. (1B, ×400) Arrow highlighting nuclear MDM2 expression among invasive oral squamous carcinoma cells. (1C, ×400) Central arrow highlighting an early Keratin pearl formation, peripheral arrow showing cytoplasmic p33ING1b expression among Keratin pearl forming squamous carcinoma cells. (1D, ×400) Positive tissue control of normal thymus stained with p33ING1b. Upper arrow highlights a Hassel's corpuscle; the lower arrow shows nuclear staining of T cells.

Association between p33ING1b status, disease-free and overall survival

A univariate Cox regression analysis of disease-free and overall survival were performed for each of the clinicopathologic parameters and molecular markers assessed in this study (table 3).

No statistically significant correlation was noted between the expression of any of the said molecular markers and disease-free and overall survival. Consistent with previous studies, a statistically significant correlation (log-rank $p < 0.0001$) was found between disease-free

Table 3: Univariate analysis of disease-free and overall survival in oral squamous cell carcinoma.

	Disease-Free Survival			Overall Survival		
	Relative Risk	95% Confidence Interval	P	Relative Risk	95% Confidence Interval	P
Sex						
Male vs Female	1.49	0.61-3.67	0.39	0.68	0.27-1.70	0.41
Age						
<65 vs ≥65	1.09	0.43-2.80	0.86	0.58	0.23-1.43	0.23
Tumor Stage						
T1-T2 vs T3-T4	0.64	0.13-3.05	0.57	0.92	0.18-4.82	0.93
Nodal Stage						
N0 vs N1-3	2.39	0.67-8.47	0.18	3.84	0.98-15.13	0.05
Overall Pathologic Stage						
Stage 1-2 vs Stage 3-4	0.5	0.12-2.02	0.33	0.35	0.09-1.43	0.14
Tumor Grade						
Moderate or Poor vs Well-differentiated	0.9	0.49-1.63	0.71	1.14	0.62-2.07	0.68
p53 Expression						
Positive vs Negative	0.8	0.27-2.35	0.68	2.1	0.80-5.52	0.13
MDM2 Expression						
Negative vs Positive	0.98	0.55-1.77	0.95	0.82	0.46-1.46	0.82
p33INGb Expression						
Positive vs Negative	1.28	0.36-4.58	0.71	0.52	0.15-1.89	0.32
Treatment						
Surgery+Radiotherapy vs Surgery	1.88	0.71-5.0	0.2	1.23	0.47-3.21	0.67

survival and the presence of nodal metastasis.

Discussion

In the present study, we examined the expression of p33ING1b and related p53 and MDM2 proteins in 57 patients with primary oral squamous cell carcinoma. We found total loss of nuclear expression and apparent cytoplasmic translocation of p33ING1b in 79% of patients which was correlated with lymph node metastasis ($P=0.04$); no correlations were observed with p53 or MDM2 protein expression.

An autoregulatory inhibitory loop exists between p53 and the human homologue of MDM2 protein. p53 can induce MDM2 transcription through a p53-responsive element in the first intron of MDM2 gene.^{13-15,17} MDM2 binds to p53 trans-activating domains which inhibits its function. It also targets p53 and facilitates its transport out of the nucleus for ubiquitin mediated degradation.¹⁸⁻²⁰ These two markers have been recently investigated in HNSCC for prognostic value.^{21,22}

"Inhibitor of growth 1" (ING1) was first identified in breast cancer as a tumor suppressor gene.²¹ Its deregulation has been reported in many cancers, including the upper aerodigestive tract.^{16,23} This gene is mapped out to human chromosome 13q34 by radiation hybrid analysis, where deletion of the chromosomal 13q33-34 has been reported in HNSCCs.^{24,25} The ING1 chromosomal locus encodes a set of alternately spliced mRNAs which translate to p47ING1a, p33ING1b and p24ING1C proteins.²⁶ The most widely expressed and biologically active of these proteins is p33ING1b, which possesses a zinc-finger motif. Overexpression of this 33 kDa nuclear protein inhibits cell growth by arresting cells in the G₁ phase of the cell cycle as well as apoptosis.²⁷ p33ING1b and p53 proteins are dependent on each other for optimal functional capacity in suppression of cell growth.¹⁵ The exact mechanism by which p33 stimulates p53 function is not yet known. This may be facilitated by increasing nuclear p53 level and stability which reverses the MDM2 dose-dependent degradation of p53.²⁸

Recent reports of p33ING1b in HNSCCs have been contradictory.²⁹⁻³¹ Polymerase chain reaction analysis of p33ING1b mis-sense mutations was negative in two separate series of 71 and 44 patients with oral squamous cell carcinoma and HNSCC, respectively.^{30,31} Another report of 34 informative patients with oral squamous cell carcinoma, however, demonstrated six mutations of ING1 gene of which three were mis-sense with corresponding amino acid changes affecting the PHD zinc

finger motif at the carboxyl terminal half and nuclear localization signal. These changes may ultimately interfere with p33ING1b function by preventing its nuclear accumulation and DNA recognition.^{23,29,32,33}

Loss of nuclear and increased cytoplasmic expression of the p33ING1b protein have been previously reported in childhood acute lymphoblastic leukemia, and brain tumors.^{23,32,33} The cause of this compartment shift is not clear yet, but structural changes in the p33ING1b protein may be a cause. This may in part, explain the apparent correlation with p33ING1b cytoplasmic expression and lymph node metastasis heralding the emergence of a more aggressive clone of neoplastic cells.

Acknowledgements

The authors would like to thank Dr. Ian V Jacobson for his guidance and support. This paper was presented at the Annual Scientific Congress of Royal Australasian College of Surgeons May 2004, Melbourne, Australia

References

- 1 Muir C, Weiland L. Upper Aerodigestive Tract Cancers. *Cancer* 1995; 75:147-53.
- 2 Vokes EE, Weichselbaum RR, Lipman SM, Hong WK. Head and neck cancer. *N Engl J Med* 1993; 328: 184-94.
- 3 Lippman SM, Hong WK. Second malignant tumors in head and neck squamous cell carcinomas: The overshadowing threat for patients with early stage disease. *Int J Radiat Oncol Biol Phys* 1989; 17: 691-4.
- 4 Kowalski LP, Medina JE. Nodal Metastases: predictive factors. *Otolaryngol Clin N Am* 1998; 31: 621-38.
- 5 Califano J, Van der Riet P, Westra W, et al. Genetic Progression Model for Head and Neck Cancer: implications for Field Cancerization. *Cancer Res* 1996; 56: 2488-92.
- 6 Levin AJ, Momand J, Finlay CA. The p53 tumour suppressor gene. *Nature* 1991; 351: 453-56.
- 7 Lane DP. p53: the guardian of the genome. *Nature* 1992; 358: 15-16.
- 8 Hollstein M, Sindransky D, Vogelstein B, Harris CC. p53 Mutations in Human Cancers. *Science* 1991; 253: 49-53.
- 9 Nylander K, Schildt EB, Eriksson M, Roos G. PCNA, Ki-67, p53, bcl-2 and prognosis in intraoral squamous cell carcinoma of the head and neck. *Anal Cell Pathol* 1997;14: 101-10.
- 10 Pande P, Soni S, Kaur J, et al. Prognostic factors in betel and tobacco related oral cancer. *Oral Oncology* 2002; 38: 491-9.

- 11 Yuen PW, Chow V, Choy J, et al. The clinicopathologic significance of p53 and p21 expression in the surgical management of lingual squamous cell carcinoma. *Am J Clin Pathol* 2001; 116: 240-5.
- 12 Kapranos N, Stathopoulos GP, Manopoulos L, et al. p53, p21 and p27 protein expression in head and neck cancer and their prognostic value. *Anticancer Res* 2001; 21: 521-8.
- 13 Wu X, Bayle JH, Olson D, Levine AJ. The p53-mdm-2 autoregulatory feedback loop. *Genes Dev* 1993; 7: 1126-32.
- 14 Juven T, Barak Y, Zauberman A, George DL, Oren M. Wild type p53 can mediate sequence-specific transactivation of an internal promoter within the mdm2 gene. *Oncogene* 1993; 8: 3411-6.
- 15 Garkavtsev I, Kazarov A, Gudkov A, Riabowol K. Suppression of the novel growth inhibitor p33ING1 promotes neoplastic transformation. *Nat Genet* 1996; 14: 415-20.
- 16 Hara Y, Zheng Z, Evans S, et al. ING1 and p53 tumor suppressor gene alterations in adenocarcinomas of the esophagogastric junction. *Cancer Lett* 2003; 192: 109-16.
- 17 Garkavtsev I, Grigorian IA, Ossovskaya VS, et al. The candidate tumour suppressor p33ING1 cooperates with p53 in cell growth control. *Nature* 1998; 391: 295-8.
- 18 Oliner JD, Pietenpol JA, Thiagalingam J, et al. Oncoprotein MDM2 conceals the activation domain of tumour suppressor p53. *Nature* 1993; 362: 857-60.
- 19 Haupt Y, Maya R, Kazaz, Oren M. Mdm2 promotes the rapid degradation of p53. *Nature* 1997; 387: 296-9.
- 20 Maki CG, Huibregtse JM, Howley PM. In vivo ubiquitination and proteasome-mediated degradation of p53(1). *Cancer Res* 1996; 56: 2649-54.
- 21 Yanamoto S, Kawasaki G, Yoshitomi I, Mizuno A. p53, mdm2, and p21 expression in oral squamous cell carcinomas: relationship with clinicopathologic factors. *Oral Surg Oral Med Oral Pathol Oral Radiol Endod* 2002; 94: 593-600.
- 22 Matsumura T, Yoshihama Y, Kimura T, et al. p53 and MDM2 expression in oral squamous cell carcinoma. *Oncology* 1996; 53: 308-12.
- 23 Vieyra D, Senger DL, Toyama T, et al. Altered subcellular localization and low frequency of mutations of ING1 in human brain tumors. *Clin Cancer Res* 2003; 9: 5952-61.
- 24 Zeremski M, Horrigan SK, Grigorian IA, et al. Localisation of the Candidate Tumour Suppressor ING1 to Human Chromosome 13q34. *Somat Cell Mol Genet* 1997; 23: 233-6.
- 25 Maestro R, Piccinin S, Doglioni C, et al. Chromosome 13q deletion mapping in head and neck squamous cell carcinomas: identification of two distinct regions of preferential loss. *Cancer Res* 1996; 56: 1146-50.
- 26 Saito A, Furukawa T, Fukushige S, et al. p24/ING1-ALT1 and p47/ING1-ALT2, distinct alternative transcripts of p33/ING1. *J Hum Genet* 2000; 45: 177-81.
- 27 Helbing CC, Veillette C, Riabowol K, et al. A novel candidate tumor suppressor, ING1, is involved in the regulation of apoptosis. *Cancer Res* 1997; 57: 1255-8.
- 28 Leung KM, Po LS, Tsang FC, et al. The candidate tumor suppressor ING1b can stabilize p53 by disrupting the regulation of p53 by MDM2. *Cancer Res* 2002; 62: 4890-3.
- 29 Gunduz M, Ouchida M, Fukushima K, et al. Genomic structure of the human ING1 gene and tumor-specific mutations detected in head and neck squamous cell carcinomas. *Cancer Res* 2000; 60: 3143-6.
- 30 Krishnamurthy J, Kannan K, Feng J, et al. Mutational analysis of the candidate tumor suppressor gene ING1 in Indian oral squamous cell carcinoma. *Oral Oncol* 2001; 37: 222-4.
- 31 Sanchez-Cespedes M, Okami K, Cairns P, Sidransky D. Molecular analysis of the candidate tumor suppressor gene ING1 in human head and neck tumors with 13q deletions. *Genes Chromosomes Cancer* 2000; 27: 319-22.
- 32 Nouman GS, Anderson JJ, Wood KM, et al. Loss of nuclear expression of the p33(ING1b) inhibitor of growth protein in childhood acute lymphoblastic leukaemia. *J Clin Pathol* 2002; 55: 596-601.
- 33 Nouman GS, Anderson JJ, Mathers ME, et al. Nuclear to cytoplasmic compartment shift of the p33ING1b tumour suppressor protein is associated with malignancy in melanocytic lesions. *Histopathology* 2002; 40: 360-6.