

Coronary Artery Bifurcation Lesions; A Review and a Guide for Specific Interventional Techniques

M.R. Movahed

Abstract

Percutaneous coronary intervention in the setting of coronary bifurcation lesions is associated with increased risk for complications. The goal of this manuscript is to review the currently available classifications for coronary artery bifurcation lesions with a guide to the use of specific coronary bifurcation techniques based on lesion characteristics.

Iran J Med Sci 2008; 33(4): 187-194.

Keywords • Classifications • stenting • bifurcated • angioplasty • atherosclerosis • PTCA • techniques

Background

Coronary bifurcation lesions are among the most challenging lesions with high risk for complications.¹ For this reason, based on the American College of Cardiology Task Force, bifurcation lesions are categorized simple bifurcation lesions as type B and type C lesions.² Despite the availability of drug eluting stents, the restenosis rate of coronary artery bifurcation lesions remains high,³⁻⁵ with increased risk for subacute and late stent thrombosis.^{3,6-11} Currently, there is no guideline to address the choice of particular interventional technique in regards to the specific anatomy of a given bifurcation lesion. In order to use specific technique for a given coronary bifurcation lesion, it is important to have a user friendly and applicable classification.

Coronary artery bifurcation classifications

Currently, there are six major bifurcation lesion classifications published in the literature. Of these, four classifications were published in the era of bare metal stents.^{9,12-14} There are very similarity in describing a given coronary bifurcation lesion. Different lesion types are named using numbers or alphabet with lack of association between the given name and the lesion characteristics. For instance, similar lesion types in Sanborn, Duke, and other classifications describe many details of these lesions without clinical relevance. On the other hand, they failed to describe other important features of a bifurcation lesion such as proximal segment or bifurcation angle.¹⁴ Sanborn's Type II and Type IV lesions (figure 1) describe two bifurcation lesions as two different types with the same technical relevance that only main branch has disease. On the other hand, this classification does not categorize technically important features of bifurcation lesions such as angulation between the two branches or the size of the proximal

Department of Medicine, Division of
Cardiology,
School of Medicine,
University of Arizona,
The Southern Arizona VA Health Care
System Sarver heart center,
Tucson, AZ, USA.

Correspondence:

Mohammad Reza Movahed MD, PhD,
Department of Medicine, Division of
Cardiology,
School of Medicine,
University of Arizona,
The Southern Arizona VA Health Care
System
Tucson, AZ, USA.

Tel: +1 520 6262000

+1 949 4000091

Fax: +1 520 6294636

Emails: rmovahed@email.arizona.edu

rmova@aol.com

Submitted: 16 August 2008

Revised: 11 October 2008

Accepted: 15 October 2008

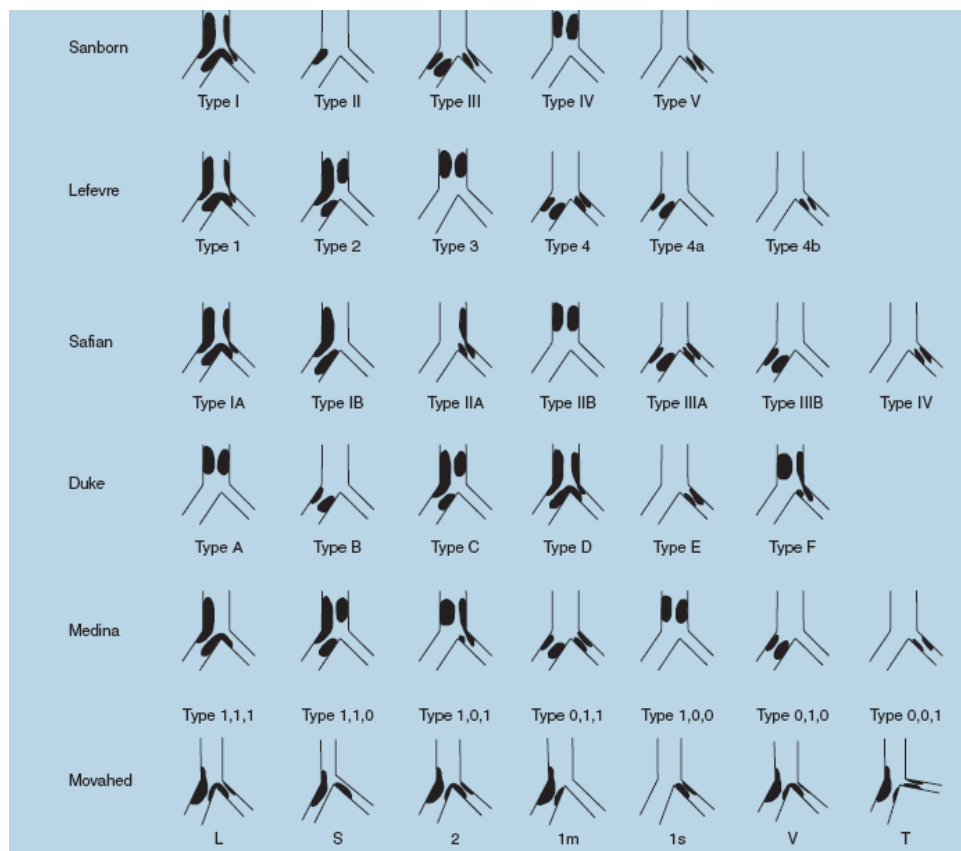


Figure 1: Summary of currently published major coronary bifurcation classifications (Movahed MR. Coronary artery bifurcation lesion classifications, interventional techniques and clinical outcome (With permission from Expert Rev Cardiovasc Ther 2008;6:261-74).

healthy segment (important features for kissing stent technique). Duke classification,¹² also fails to describe bifurcation angle and proximal healthy segment. Again, there are redundancies in these classifications. For example, Duke type A, type B, and type C lesions are similar in regards to technical decision making (figure 1). The same redundancy in separating bifurcation lesions into different types without technical relevance can be seen in all the Safian and Lefevre types,¹³ (figure 1). Again, in those classifications, there is no description about proximal segment or angulation between the two branches missing important technical information. Furthermore, there is no connection between the lesion types and the lesion's names making it very hard to remember. These are the reasons why these classifications not being used clinically.

Recently, two new bifurcation classifications were published in order to improve some of the limitations of the previous classifications. First attempt to simplify these classifications for better memorization was made by Medina et al.¹⁵ (figure 1). Their group divided bifurcation lesions into three segments: proximal segment of the main branch, side branch ostia, and distal

segment of the main branch. Any involvement of each segment is assigned suffix 1, otherwise suffix 0 was given from left to right. For example, lesion 1,0,1 means that proximal segment and distal part of the main branch has disease but side branch ostia are free of disease (figure 1). This classification is easier to remember in comparison to older classifications. However, the Medina classification completely fails to include two extremely important features of bifurcation lesions: angulation and the size of the proximal healthy segment. This classification has redundancy as can be seen in the other classifications. For example, lesions 1,1,1 and 0,1,1 and 1,1,0 (figure 1) describe three types of lesions with involvement of the main and side branch ostia. Therefore, these lesions are anatomically very similar with little differences in regards to technical decision making.

Newest simplified classification of bifurcation lesions that can be easily remembered and relevant to interventional techniques

In order to overcome the limitations and shortcomings of the above mentioned classifications,

a new classification (Movahed classification) was recently published eliminating the redundancy and including other technically important features of a given bifurcation lesion.¹⁶ This classification is based on a system that is composed of a single prefix to which up to four different suffixes can be added (figures 1 and 2). The description of this classification begins with the prefix B (for Bifurcation lesion) to which four different suffixes are added to obtain the final description of the lesion or only one or more suffixes can be used for simplicity. The nomenclature for true bifurcation lesions involves only two main subgroups for each of the four suffixes. Each suffix describes technically important feature of a bifurcation lesion in the context of technical decision making. Using suffixes that are directly related to the important features of a bifurcation lesion makes this classification very easy to memorize. This classification is complete and includes two other important technical features of bifurcation lesions that are not described in any other major classifications: the proximal healthy segment and the angle of bifurcation branches.

Detailed features of nomenclature in

Movahed classification

Large proximal segment is a very important requirement for kissing stent technique that is included in this classification. For kissing stent technique, it is required to have a proximal healthy segment that is at least as large as 2/3 of the sum of the diameter of both branch vessels in order to accommodate two stents.⁵ The first suffix of this classification addresses this feature. If the proximal segment is large enough L is given for the first suffix (L for large proximal segment). On the other hand if the proximal segment is small (less than 2/3 of the sum of the diameters of both branch vessels) suffix of S (for small proximal segment) is used. Therefore, BS lesions are not suitable for kissing stent technique.⁵

The second suffix in this classification describes one of the most important features of coronary bifurcation lesions describing the involvement of branches. If both ostia of bifurcation branches are diseased, the suffix number 2 is used. It is known that significant ostial disease of main and side branch dramatically increases the risk of side branch occlusion during stenting of the main branch. In one large

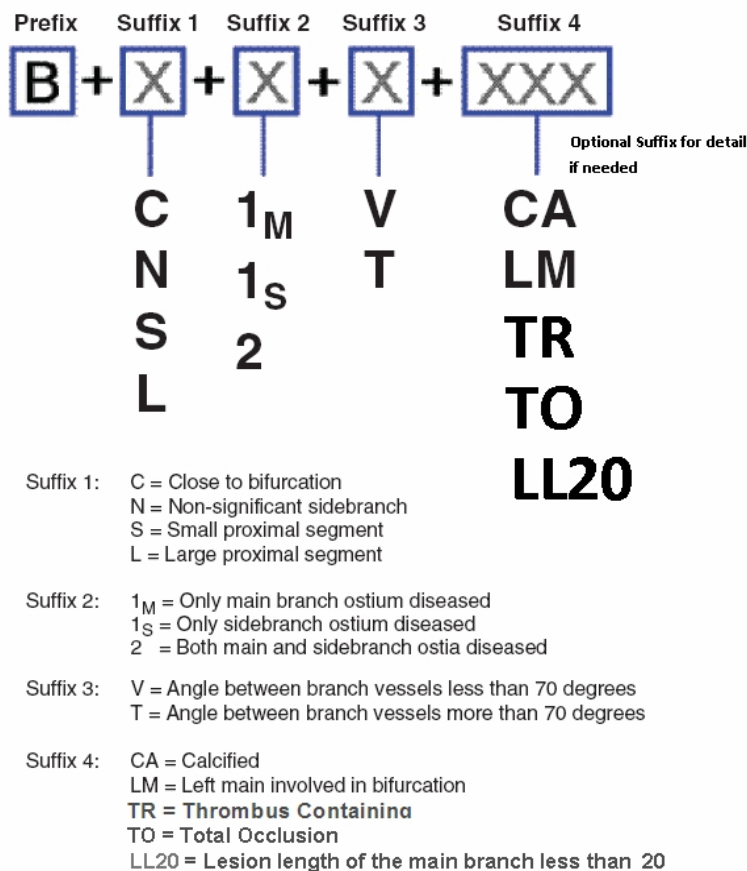


Figure 2: Detail structural description of the Movahed's coronary bifurcation classification with modification of the 4th suffix (reprint with permission from The Journal of Invasive Cardiology).

study, atherosclerotic involvement of both branch ostia was associated with 40% occurrence of myocardial infarction whereas if only main branch was diseased, myocardial infarction occurred in only 4.7%.¹⁷ Furthermore, side branch closure occurred in 65% of lesions if both ostia were diseased versus 4% in lesions without side branch involvement.¹⁸ In Movahed classification, if only the main branch is diseased regardless of proximal or distal segment involvement, suffix 1m will be used. If only the side branch has disease (or anatomically less important branch), suffix 1s will be used. This distinction is important for technical decision making, which is discussed later.

The third important suffix in this classification describes the angulation of bifurcation branches, which had not been mentioned in other classifications. Lesions with steep angulations have major disadvantage that the side branch access can be very difficult after main branch stenting. It is also associated with increase in the long term mortality if crush stent technique is utilized.¹⁹ Furthermore, steep angle is significantly associated with the risk of abrupt vessel closure,²⁰ or side branch occlusion.¹⁸ Therefore, it is important to incorporate this anatomical feature into a classification. The suffix V is given for shallow angles < 70 degree (which looks like a V) and suffix T is given for a bifurcation with steep angle of > 70 degree (which looks like a T). For example a BL2V lesion is a bifurcation lesion (B for bifurcation) that has a large proximal segment (L for large that is suitable for kissing stent technique) with involvement of 2 ostia (2 for both ostia) in the disease process with a shallow angulation (V for shallow angulation looks like a V) of the branches. For simplicity, only one feature can be used to describe a given (B2, B1m, BV, BT, BL etc. lesions).

This classification includes optional suffixes for other high risk features at the end of the classification symbols (in this classification LM was used for left main and CA for calcium). However, an expansion of this classification can be done easily by adding an abbreviation of other high risk features to the end of the lesion description such as TO for total occlusion or TR for thrombus containing lesion, etc. A summary of currently available classifications can be seen in figure 1. Detailed structural explanation of the newest comprehensive simplified classification can be seen in figure 2.

Technical details of major interventional

techniques for the treatment of bifurcation lesions

Several techniques have been used and described in the treatment of bifurcation lesions. There is a considerable confusion in the description of bifurcational techniques in the past.^{9,12,14,21-25} For example, 'V' stenting if proximal overlap of both stents is too short is used for the kissing stent technique.^{5,22} Recently, European Bifurcation Club has divided bifurcation interventions in categories based on the location and timing of the first stent implantation. If the first stent is utilized in the main branch, they call it M (M for Main branch). If it crosses the bifurcation, it is called A (A for Across) and if the side branch is stented first, they call it S (S for Side branch).²⁶ The major problem with this nomenclature is the fact that it does not describe technical aspects of important interventional techniques in regards to using one or two stents. For simplification, the most common bifurcation techniques for stenting have been recently classified by Movahed et al. into 6 categories;¹⁶ 1) OST= One Stent Technique, 2) SBT= Stent with Balloon Technique, 3) KST=Kissing Stent Technique, 4) TST=T Stent Technique, 5) CRT= Crush Stent Technique, and 6) CUT= CULLotte stent Technique (figure 3).

The first rule is to use one stent if the lesion morphology is not a high risk for side branch occlusion. The simplest technique is using one stent technique with provisional side branch stenting in lesions at low risk for side branch occlusion (OST or SBT). The long term outcome of using one stent technique has been similar or even better than two stent techniques. Even in the era of drug eluting stents, two stent techniques did not improve restenosis rate in most trials with the higher risk for subacute stent thrombosis.^{3,27-29} On the other hand, provisional side branch stenting in B2 lesions (both ostia are diseased) poses a high risk for side branch occlusion and complication. The risk of side branch occlusion in B2 lesions that can be as high as 65% depend on the side branch angle.^{17,18} There is a general consensus that if a bifurcation lesion is not a B2 lesion, using one stent techniques (OST or SBT) with provisional side branch stenting is the preferred technique with acceptable risk unless the side branch is very important and large branch with a lot of myocardium in jeopardy. In B2 lesions, two stent techniques offer safer access to both diseased branches. Usually, for easier advancement of two stents in the bifurcation lesions, balloon predilation is recommended.

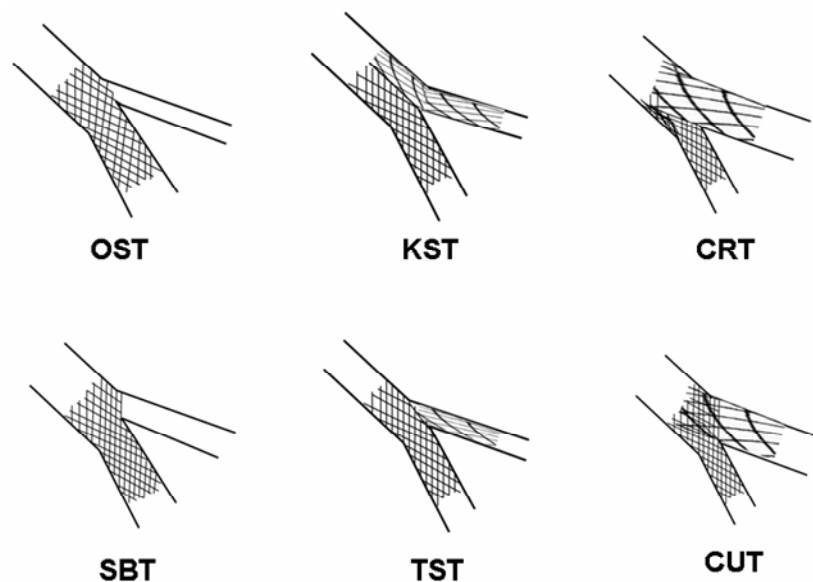


Figure 3: Schematic description of interventional bifurcation techniques: OST=One stent technique, SBT= Stent with balloon technique, KST=Kissing stent technique, TST= "T" stent technique, CRT= Crush stent technique, CUT= Cullotte stent technique. (Movahed MR. Coronary artery bifurcation lesion classifications, interventional techniques and clinical outcome (With permission from Expert Rev Cardiovasc Ther 2008;6: 261-74)

Indications and technical features of stent techniques (OST, SBT)

The OST and SBT techniques are based on a simple technique using one stent. This is the best technique in bifurcation lesions with a small side branch that can be ignored or in lesions without significant side branch ostial involvement. Therefore, these techniques are best suitable for BC (close to bifurcation) and BN (not a significant side branch) lesions or B1m lesions when the side branch ostia are not involved (as the risk of side branch occlusion is small when side branch is not diseased).¹⁸ After initial stenting of the main vessel, the side branch will be left alone or in the case of side branch plaque shift, the side branch ostia will be ballooned if the side branch is large.

Indications and technical features of two stents techniques

We will start with the KST technique that requires simultaneous advancement of two stents which are positioned side by side into each bifurcation branch with the creation of a new carina in the main branch. This technique is also known as V stenting.^{5,15,30} The major advantage of this technique is the ability to maintain access to both branches at all times. However, the occurrence of an edge dissection can be problematic. Based on two recently reported studies,^{5,31} subacute stent thrombosis rate is acceptable. For this technique large

proximal segment is required. Therefore, BL lesions with the proximal healthy segment of at least 2/3 of the sum of the diameters of both bifurcation branches are best suitable for this technique. Steep angulations may cause difficulty in advancing two stents simultaneously make BT lesions more risky. The sequence of this technique is as following: First both stents will be implanted at low pressure (6-8 atmospheres) simultaneously. Next, both stent balloons are deflated and each balloon is inflated sequentially to high pressure inflations (14-16 atmospheres) with final inflation of both stent balloons at low pressure.

The TST technique requires positioning of two stents in a 'T' fashion in both branches. This technique has many other names.^{22,24,25,32} The easiest approach is a pullback technique where a stent is placed in the side branch and a balloon in the main branch, which is inflated to low pressure during side branch stenting in order to avoid significant side branch stent protruding into the main branch with a risk of main branch compromise. A different approach is also described as mini crush. In this approach, after initial balloon predilatation, two stents are positioned simultaneously in both branches. Next the side branch stent is inflated with minimal stent overlap in the main branch. After the removal of the side branch stent balloon, main branch stenting is performed.

The loss of direct side branch access after main branch stenting is a main drawback of this technique in comparison with the KSK technique.

This technique can be best utilized in bifurcation lesions with small proximal segment, which are not suitable for the kissing stent technique.

The CRT technique, pioneered by Colombo et al.²⁴ lost initial enthusiasm due to high rate of subacute thrombosis and difficulty to rewire the side branch. It consists of advancing two stents simultaneously into both bifurcation branches. The proximal segment of side branch is deployed in the main branch and then is crushed to the main branch wall with stenting of the main branch.^{11,33} At the end of the procedure, the final simultaneous kissing balloon inflation is then performed. Although this technique can be utilized for most bifurcation lesions, steep angulations such as "T" lesions can make rewiring of the side branch difficult. Furthermore, subacute stent thrombosis and side branch restenosis rates have been high.^{7,8,11}

The CUT technique is also described as 'trouser legs'.^{22,32,34} This technique is gaining popularity again in the era of drug eluting stents. Recent trials have shown encouraging low restenosis rate in the era of DES.^{35,36} This technique is best useful as a bailout technique. In case of unsatisfactory side branch result after main branch stenting, the CUT technique can be utilized to resolve the problem. With this technique, the operator should first stent the less angulated or most diseased branch vessel, and then rewires the other branch through the stent struts. It is important that side

and main branch have similar size in order to use this technique. After the first stent, the second stent is positioned across the second branch with positioning of the proximal stent segment in the proximal part of the previously stented segment. Final simultaneous kissing balloon should be performed for better stent struts expansion. This technique is suitable for T or V lesions when both ostia are diseased.

Algorithmic approach to the treatment of bifurcation lesions based on the lesion characteristics

A recent algorithmic approach based on the anatomical features of coronary bifurcation lesions defined in the Movahed classification was published in order to guide interventionalists to bifurcation interventions (figure 4).³⁷

First, it is important to visualize the bifurcation branches and assess if a lesion is a true bifurcation. If there is a small space between the main and side branch, the lesion will be categorized as BC lesion (close to bifurcation), which is not a true bifurcation. In such a scenario, simple main branch stenting should be the easiest technique.

If the lesion is a true bifurcation lesion, then the next question is the importance of the side branch vessel. If the side branch vessel is small or supplies small territory, the lesion should be classified as BN (non significant

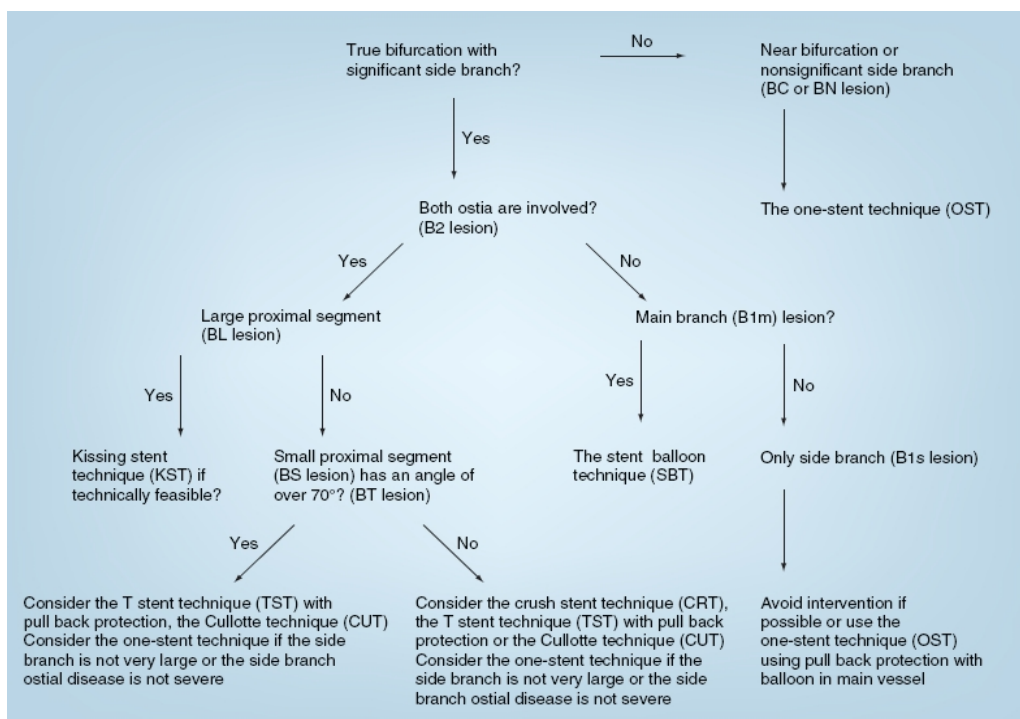


Figure 4: An algorithmic approach for the treatment of coronary artery bifurcation lesions based on the lesion type (Movahed MR. Coronary artery bifurcation lesion classifications, interventional techniques and clinical outcome. (With permission from Expert Rev Cardiovasc Ther. 2008;6:261-74) See Figure 2 and 3 for abbreviations).

bifurcation). In this case, the side branch can be ignored and stenting of the main vessel should be enough.

Next, when the side branch is found to be important, the operator needs to evaluate the involvement of the main and side branch ostia. If the main branch is not involved, the operator should reconsider intervening on the side branch with a potential risk of compromising the main branch with little benefit. Otherwise, a one stent technique with pullback protection of the main branch is the safest approach. If only main branch ostia is involved in, using one stent (OST technique) is also the preferred technique as the risk of side branch occlusion is low.

In the case of significant disease of both branch ostia, one stent techniques possess a high risk for side branch occlusion with one stent technique. The choice of two stent techniques depends on the operator's expertise and preference. Based on simplicity and good long term outcome, the kissing stent technique can be used in BL lesions with the advantage that access to the both branches maintained at all time during the procedure. Therefore, the proximal segment of a bifurcation lesion needs to be assessed. If the proximal segment is large enough to accommodate two stents in BL lesions, the kissing stent technique can be utilized. However, if the proximal healthy segment is small, other techniques should be considered.

If the branch angle is steep (over 70 degree), advancement of two stents into the side branch could be difficult. Furthermore, CRT is technically more challenging in angulated lesions and is associated with increased adverse outcome in these lesions.¹⁹ Therefore, the operator should avoid the CRT technique in angulated BT lesions. If the branch angulation is less than 70 degree, the TST technique runs the risk of missing the side branch ostium during main branch stenting. Therefore, the culotte stent technique or CRT should be initially considered in shallow lesions. If the TST technique is used, the pullback technique is the preferred choice in order to avoid missing the side branch ostium. Figure 4 shows an overview of this suggested algorithmic approach to bifurcation stenting based on the lesion characteristics.

Conflict of Interest: None declared

References

1 Al Suwaidi J, Berger PB, Rihal CS, et al. Immediate and long-term outcome of intracoronary stent implantation for true bifurca-

- tion lesions. *J Am Coll Cardiol* 2000; 35: 929-36.
- 2 Ryan TJ, Faxon DP, Gunnar RM, et al. Guidelines for percutaneous transluminal coronary angioplasty. A report of the American College of Cardiology/American Heart Association Task Force on Assessment of Diagnostic and Therapeutic Cardiovascular Procedures (Subcommittee on Percutaneous Transluminal Coronary Angioplasty). *Circulation* 1988; 78: 486-502.
- 3 Colombo A, Moses JW, Morice MC, et al. Randomized study to evaluate sirolimus-eluting stents implanted at coronary bifurcation lesions. *Circulation* 2004; 109: 1244-9.
- 4 Pan M, de Lezo JS, Medina A, et al. Rapamycin-eluting stents for the treatment of bifurcated coronary lesions: a randomized comparison of a simple versus complex strategy. *Am Heart J* 2004; 148: 857-64.
- 5 Sharma SK, Choudhury A, Lee J, et al. Simultaneous kissing stents (SKS) technique for treating bifurcation lesions in medium-to-large size coronary arteries. *Am J Cardiol* 2004; 94: 913-7.
- 6 Vigna C, Biondi-Zoccai G, Amico CM, et al. Provisional T-drug-eluting stenting technique for the treatment of bifurcation lesions: clinical, myocardial scintigraphy and (late) coronary angiographic results. *J Invasive Cardiol* 2007; 19: 92-7.
- 7 Jim MH, Ho HH, Chan AO, Chow WH. Stenting of coronary bifurcation lesions by using modified crush technique with double kissing balloon inflation (sleeve technique): Immediate procedure result and short-term clinical outcomes. *Catheter Cardiovasc Interv* 2007; 69: 969-75.
- 8 Iakovou I, Schmidt T, Bonizzoni E, et al. Incidence, predictors, and outcome of thrombosis after successful implantation of drug-eluting stents. *JAMA* 2005; 293: 2126-30.
- 9 Lefevre T, Louvard Y, Morice MC, et al. Stenting of bifurcation lesions: classification, treatments, and results. *Catheter Cardiovasc Interv* 2000; 49: 274-83.
- 10 Movahed MR, Vu J, Ahsan C. Simultaneous subacute stent thrombosis of two drug-eluting stents in the left anterior descending and the circumflex coronary arteries. Case report and review of the literature. *J Invasive Cardiol* 2006; 18: E198-202.
- 11 Ormiston JA, Currie E, Webster MW, et al. Drug-eluting stents for coronary bifurcations: insights into the crush technique. *Catheter Cardiovasc Interv* 2004; 63: 332-6.

- 12 Popma JJ, Leon MB, Topol EJ. Atlas of Interventional Cardiology. Philadelphia: Saunders, 1994.
- 13 Safian RD. Bifurcation Lesions. The Manual of Interventional Cardiology. Freed M (Eds). Physician's Press, MI, USA; 2001. p. 222.
- 14 Spokojny AM, Tm S. Strategic Approaches in Coronary Intervention. Williams and Wilkins. Philadelphia; 1996. p. 288.
- 15 Melikian N, Airoidi F, Di Mario C. Coronary bifurcation stenting. Current techniques, outcome and possible future developments. *Minerva Cardioangiol* 2004; 52: 365-78.
- 16 Movahed MR, Stinis CT. A new proposed simplified classification of coronary artery bifurcation lesions and bifurcation interventional techniques. *J Invasive Cardiol* 2006; 18: 199-204.
- 17 Baim DS, Cutlip DE, O'Shaughnessy CD, et al. Final results of a randomized trial comparing the NIR stent to the Palmaz-Schatz stent for narrowings in native coronary arteries. *Am J Cardiol* 2001; 87: 152-6.
- 18 Aliabadi D, Tilli FV, Bowers TR, et al. Incidence and angiographic predictors of side branch occlusion following high-pressure intracoronary stenting. *Am J Cardiol* 1997; 80: 994-7.
- 19 Dzavik V, Kharbanda R, Ivanov J, et al. Predictors of long-term outcome after crush stenting of coronary bifurcation lesions: importance of the bifurcation angle. *Am Heart J* 2006; 152: 762-9.
- 20 Tan K, Sulke N, Taub N, Sowton E. Clinical and lesion morphologic determinants of coronary angioplasty success and complications: current experience. *J Am Coll Cardiol* 1995; 25: 855-65.
- 21 Safian RD. Bifurcation Lesions. The Manual of Interventional Cardiology, 2001. p. 222.
- 22 Melikian N, Di Mario C. Treatment of bifurcation coronary lesions: a review of current techniques and outcome. *J Interv Cardiol* 2003; 16: 507-13.
- 23 Lefèvre T, Louvard Y, Morice MC, et al. Stenting of bifurcation lesions: a rational approach. *J Interv Cardiol* 2001; 14: 573-85.
- 24 Colombo A, Stankovic G, Orlic D, et al. Modified T-stenting technique with crushing for bifurcation lesions: immediate results and 30-day outcome. *Catheter Cardiovasc Interv* 2003; 60: 145-51.
- 25 Ge L, Iakovou I, Cosgrave J, et al. Treatment of bifurcation lesions with two stents: one year angiographic and clinical follow up of crush versus T stenting. *Heart* 2006; 92: 371-6.
- 26 Louvard Y, Thomas M, Dzavik V, et al. Classification of coronary artery bifurcation lesions and treatments: Time for a consensus. *Catheter Cardiovasc Interv* 2008; 71:175-83.
- 27 Steigen TK, Maeng M, Wiseth R, et al. Randomized study on simple versus complex stenting of coronary artery bifurcation lesions: the Nordic bifurcation study. *Circulation* 2006; 114: 1955-61.
- 28 Ge L, Airoidi F, Iakovou I, et al. Clinical and angiographic outcome after implantation of drug-eluting stents in bifurcation lesions with the crush stent technique: importance of final kissing balloon post-dilation. *J Am Coll Cardiol* 2005; 46: 613-20.
- 29 Hoye A, Iakovou I, Ge L, et al. Long-term outcomes after stenting of bifurcation lesions with the "crush" technique: predictors of an adverse outcome. *J Am Coll Cardiol* 2006; 47: 1949-58.
- 30 Gobeil F, Lefèvre T, Guyon P, et al. Stenting of bifurcation lesions using the Bestent: a prospective dual-center study. *Catheter Cardiovasc Interv* 2002; 55: 427-33.
- 31 Kim YH, Park DW, Suh IW, et al. Long-term outcome of simultaneous kissing stenting technique with sirolimus-eluting stent for large bifurcation coronary lesions. *Catheter Cardiovasc Interv* 2007; 70: 840-6.
- 32 Louvard Y, Lefevre T, Morice MC. Percutaneous coronary intervention for bifurcation coronary disease. *Heart* 2004; 90: 713-22.
- 33 Ormiston JA, Webster MW, El Jack S, et al. Drug-eluting stents for coronary bifurcations: Bench testing of provisional side-branch strategies. *Catheter Cardiovasc Interv* 2006;67:49-55
- 34 Chevalier B, Glatt B, Royer T, Guyon P. Placement of coronary stents in bifurcation lesions by the "culotte" technique. *Am J Cardiol* 1998; 82: 943-9.
- 35 Hoye A, van Mieghem CA, Ong AT, et al. Percutaneous therapy of bifurcation lesions with drug-eluting stent implantation: the Culotte technique revisited. *Int J Cardiovasc Intervent* 2005; 7: 36-40.
- 36 Kaplan S, Barlis P, Dimopoulos K, et al. Culotte versus T-stenting in bifurcation lesions: immediate clinical and angiographic results and midterm clinical follow-up. *Am Heart J* 2007; 154: 336-43.
- 37 Movahed MR. Coronary artery bifurcation lesion classifications, interventional techniques and clinical outcome. *Expert Rev Cardiovasc Ther* 2008; 6: 261-74.