

# Hemoperitoneum Caused by Placenta Percreta in the Third Trimester of Pregnancy

Roya Faraji Darkhaneh<sup>1</sup>,  
Maryam Asgharnia<sup>1</sup>,  
Sohrab Aghazadeh<sup>2</sup>

## Abstract

The placental adhesive disorders such as placenta accreta and placenta percreta are the rare causes of serious obstetric hemorrhages. They are associated with high maternal morbidity and mortality. Placenta percreta is usually diagnosed in the third trimester of pregnancy as a massive postpartum hemorrhage when an attempt to remove the placenta reveals lack of a cleavage plane. Here we report an unusual presentation of placenta percreta as hemoperitoneum and hemorrhagic shock in the third trimester of pregnancy. A 33-year-old woman was admitted to hospital at the 35th weeks of gestation with abdominal pain and hemorrhagic shock. Laparotomy was immediately performed because of intra-abdominal bleeding. Upon inspection, a posterior laceration of the uterus was noted. Pathologic investigation of the uterus showed placenta percreta. The patient recovered uneventfully. Spontaneous rupture of the uterus can be occurred in the absence of uterine trauma. In the differential diagnosis of a pregnant woman presenting with hypotension, abdominal pain, and fetal death, rupture of the uterus caused by placenta percreta should be considered. Rapid diagnosis, blood transfusion, and emergency laparotomy are the key steps in successful management.

**Iran J Med Sci 2009; 34(2): 145-148.**

**Keywords** • Hysterectomy • placenta percreta • hemoperitoneum • pregnancy

## Introduction

**P**lacenta percreta is a rare complication of pregnancy and is potentially life-threatening for both the mother and the fetus.<sup>1,2</sup> Although this complication was already known to the ancients, the first reported case in modern literature comes from Plater in 1588.<sup>3</sup> In general, absence or inadequate formation of the deciduas can lead to infiltration of trophoblast into the myometrium. The frequency of placenta accreta, increta, and percreta have been reported as 1:540 to 1:93000 with an average of 1 in 700 pregnancies.<sup>4,5</sup> It is strongly associated with placenta previa which is associated in turn with uterine scars. The incidence of uterine scars is rising in parallel with the high rate of caesarean sections.<sup>6,7</sup>

We report a case of placenta percreta which presented with intra-abdominal bleeding, shock, and fetal death.

## Case Report

A 33-year-old woman presented at the 35th weeks of gestation

<sup>1</sup>Department of Obstetrics and Gynecology,

<sup>2</sup>General Surgery, Guilan University of Medical Science, Rasht, Iran.

### Correspondence:

Roya Faraji Darkaneh MD,  
Department of Obstetrics and Gynecology,  
Guilan University of Medical Science,  
Rasht, Iran.

**Tel:** +98 131 2227020

**Fax:** +98 131 3228724

**Email:** [Royafaraji1371@yahoo.com](mailto:Royafaraji1371@yahoo.com)

Received: 17 May 2008

Revised: 28 October 2008

Accepted: 5 December 2008

of her second pregnancy, with abdominal pain and shock. Her first pregnancy, 8 years earlier, was uneventful except for cephalo-pelvic disproportion resulting in an uncomplicated caesarean section. She did not have any ultrasonography report in her current pregnancy.

The antenatal period was uneventful until her presentation at 35 weeks of gestation with severe abdominal pain, referred bilaterally to the shoulders. She reported a mild abdominal pain in the last night, which had resolved spontaneously.

On admission, she was very pale, ill looking, and hemodynamically unstable. Examination of her abdomen revealed generalized rebound tenderness and distension. It was difficult to define uterine tenderness and uterine height. Fetal heart rate was not detectable and she had not felt any fetal movements in the precedent 8 hours. The vaginal examination was normal without any dilation, effacement, or bleeding. She had tachypnea and other signs of respiratory distress.

The presumed clinical diagnosis was concealed placental abruption or uterine rupture and the decision was made to perform an emergency laparotomy.

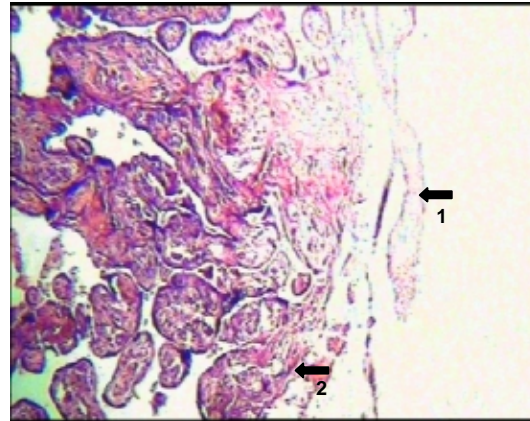
At the time of surgery, a significant hemoperitoneum was found. Two litres of fresh and clotted blood were removed from the peritoneal cavity. Lower segment caesarean section was done revealing clear amniotic fluid. A dead fetus was born. The placenta was densely adhered to the posterior aspect of the uterus. The myometrium and serosa were penetrated by placenta at the posterior aspect, with evidence of uterine laceration. The diagnosis of placenta percreta was made and the patient was treated by an emergency subtotal hysterectomy.

Five units of packed red blood cells and fresh frozen plasma were transfused intravenously. The postoperative hemoglobin level was 8.4g/dL. The patient recovered quickly and was discharged to home on the 4th postoperative day.

Histopathological investigation of the uterus revealed placenta percreta. There was marked villous penetration of the myometrium and serosa. Microscopically, multiple representative sections showed poorly developed deciduas basalis and villous penetration of the myometrium and serosa (figure 1).

## Discussion

Placenta percreta is the most extreme form of placenta accreta and is a rare but serious complication of pregnancy.<sup>8,9</sup> Three degrees of



**Figure 1:** The villous infiltration extends through the whole thickness of the myometrium, deep to serosal layer (1-serosa 2- villous).

the disease have been described: true placenta accreta, where villi are adherent to myometrial bed without invasion; placenta increta, where the villi invade the muscle; and placenta percreta, where there is full-thickness penetration of the myometrium.<sup>10-13</sup> Placenta percreta, the rarest form of placenta accreta, is believed to represent 5–7% of all abnormal placentations.<sup>14,15</sup>

Although the etiology of placenta percreta is unknown,<sup>16</sup> about 25% of women with placenta previa and one previous caesarean section have an accreta/percreta.<sup>17</sup> The increasing incidence of placenta accreta may be resulted from the increased rate of caesarean deliveries.<sup>18,19</sup> Other predisposing factors include: uterine curettage, manual removal of the placenta, and placenta previa.<sup>11</sup> In our patient, although she had a previous scar of caesarean section on the anterior wall of the uterus, we observed the placenta on posterior wall and previa was on the fundus. Despite the lack of the two risk factors, our patient had placenta percreta.

Placenta percreta may present in the antenatal period with intraperitoneal or intravesical bleeding. Intraperitoneal bleeding mimics placental abruption or uterine rupture, though subacute presentations have also been described.<sup>20</sup> Our patient had signs of intraperitoneal bleeding that mimicked uterine rupture. Sonographic evaluation can help diagnosing accurately. However, this information may not be conclusive and additional information must be required.<sup>21,22</sup> Diagnosis of the disease in advance permits a planned delivery and preparation for blood transfusions and planned caesarean hysterectomy, which is a common treatment and reduces maternal morbidity and mortality.<sup>9</sup>

The primary diagnosis is definitely constituted by the clinical suspicion. Among the diagnostic methods, ultrasonography is the routine,

cost-effective and popular one. However, occasionally the anatomic information might not be conclusive. Magnetic resonance imaging (MRI) provides crucial information in this situation. Information on the vascularization (angioresonance) of the anatomic planes and of the degree of invasion, modifies the surgical strategy. The contrasted study by MRI has allowed the correct clinical and radiological differentiation between the placenta accreta and percreta.<sup>23,24</sup> The information about the anatomical and vascular status provided by this technique, help more accurate decision making by the clinicians.

In the present report, because of the critical situation of the patients we could not use diagnostic tools; however we believe that all women with placenta previa and a previous caesarean section are at risk for placenta percreta and they should be investigated during routine ultrasonography.

In order to decrease the high morbidity and mortality associated with placenta percreta, a good management strategy is essential. In placenta percreta, uterine wall damage is massive and the risk of maternal and fetal complications increases notably after the 35th week of gestation and exceeds to 90% after the 36th week.<sup>25</sup>

Two types of management for placenta percreta have been proposed. Hemoperitoneum and uterine rupture caused by placenta percreta usually require surgical removal of the uterus and the surrounding tissues. Conservative therapy has also been described and includes localized resection of the placental implantation site, over sewing, blunt dissection, and packing techniques.<sup>26,27</sup>

In women whose families are not complete, a conservative approach might be more appropriate as long as they are aware of the risks. The choice between hysterectomy and conservative therapy is dependent on the severity of the placenta percreta and the type of additional complications.

Reported complications of placenta percreta include severe bleeding that can be life-threatening and invasion of neighboring organs by the placental villi such as the urinary bladder.<sup>28</sup>

We did not have enough facilities such as blood products for transfusion to perform conservative treatment. Meanwhile, the patient had a child and her family was near complete. So, subtotal hysterectomy with good hemostatic control for saving mother's life was performed.

## Conclusion

Placenta percreta is rare but might lead to life-

threatening conditions. Early diagnosis and prompt surgical management might reduce maternal mortality.

**Conflict of Interest:** None declared

## References

- Hussain M, Sarwar S, Bhutta SZ. Placenta percreta causing acute abdomen in the second trimester of pregnancy. *J Coll Physicians Surg Pak* 2004; 14: 244-6.
- Baloul SM, Al-Sayali AR, Basha AM, Gangoon NJ. Placenta percreta with painless uterine rupture at the 2nd trimester. *Saudi Med J* 2002; 23: 857-9.
- Harer WB. Placenta accreta; report of eight cases. *Am J Obstet Gynecol* 1956; 72: 1309-14.
- Baron F, Hill WC. Placenta previa, placenta abruptio. *Clin Obstet Gynecol* 1998; 41: 527-32.
- Breen JL, Neubecker R, Gregori CA, Franklin JE Jr. Placenta accreta, increta, and percreta. A survey of 40 cases. *Obstet Gynecol* 1977; 49: 43-7.
- Höpker M, Fleckenstein G, Heyl W, et al. Placenta percreta in week 10 of pregnancy with consecutive hysterectomy: case report. *Hum Reprod* 2002; 17: 817-20.
- Beukenholdt RW, Allman A. Undiagnosed placenta percreta. *J Obstet Gynaecol* 2002; 22: 688.
- Smith L, Mueller P. Abdominal pain and haemoperitoneum in the gravid patient: A case report of placenta percreta. *Am J Emerg Med* 1996; 14: 45-7.
- Henrich W, Fuchs I, Ehrenstein T, et al. Antenatal diagnosis of placenta percreta with planned in situ retention and methotrexate therapy in a woman infected with HIV. *Ultrasound Obstet Gynecol* 2002; 20: 90-3.
- Irving FC, Hertig AT. A study of placenta accreta. *Surg Gynaecol Obstet* 1937; 64: 178-200.
- Lamyman MJ, Connor H, Brown R. Abdominal pain and dysuria in pregnancy: urinary tract infection or life threatening haemorrhage? *Emerg Med J* 2005; 22: 918-9.
- Topuz S. Spontaneous uterine rupture at an unusual site due to placenta percreta in a 21-week twin pregnancy with previous cesarean section. *Clin Exp Obstet Gynecol* 2004; 31: 239-41.
- LeMaire WJ, Louisy C, Dalessandri K, Muschenheim F. Placenta percreta with spontaneous rupture of an unscarred uterus in the second trimester. *Obstet Gynecol* 2001; 98: 927-9.

- 14 Morken NH, Henriksen H. Placenta percreta-two cases and review of the literature. *Eur J Obstet Gynecol Reprod Biol* 2001; 100: 112-5.
- 15 Carlton SM, Zahn CM, Kendall BS, Natarajan S. Placenta increta/percreta associated with uterine perforation during therapy for fetal death. A case report. *J Reprod Med* 2001; 46: 601-5.
- 16 Haider P. Placenta percreta in early gestation. *J Pak Med Assoc* 1990; 40: 274-5.
- 17 Clark SL, Koonings PP, Phelan JP. Placenta previa/accreta and prior cesarean section. *Obstet Gynecol* 1985; 66: 89-92.
- 18 Liang HS, Jeng CJ, Sheen TC, et al. First-trimester uterine rupture from a placenta percreta. A case report. *J Reprod Med* 2003; 48: 474-8.
- 19 Ogawa M, Sato A, Yasuda K, et al. Cesarean section by transfundal approach for placenta previa percreta attached to anterior uterine wall in a woman with a previous repeat cesarean section: case report. *Acta Obstet Gynecol Scand* 2004; 83: 115-6.
- 20 Vyjayanthi S, Rajesh U, Bloomfield TH. Haemoperitoneum due to placenta percreta in the third trimester mimicking placental abruption. *J Obstet Gynaecol* 2002; 22: 690-1.
- 21 Oyelese Y, Smulian JC. Placenta previa, placenta accreta, and vasa previa. *Obstet Gynecol* 2006; 107: 927-41.
- 22 Finberg HJ, Williams JW. Placenta accreta: prospective sonographic diagnosis in patients with placenta previa and prior cesarean section. *J Ultrasound Med* 1992; 11: 333-43.
- 23 Marcos HB, Semelka RC, Worawattanakul S. Normal Placenta: gadolinium-enhanced, Dynamic MR Imaging. *Radiology* 1997; 205: 493-6.
- 24 Palacios JM, Claudio MB, Mario P. Differential Diagnosis of the Placental Adhesive Disorders by Contrasted Nuclear Magnetic Resonance & Ultrasound - Placenta Accreta and Percreta 2001. available at: <http://www.obgyn.net/ultrasound/?page=/ultrasound/placenta-accreta/placenta-accreta>
- 25 O'Brien JM, Barton JR, Donaldson ES. The management of placenta percreta: conservative and operative strategies. *Am J Obstet Gynecol* 1996; 175: 1632-8.
- 26 Baloul SM, Al-Sayali AR, Basha AM, Gangoo NJ. Placenta percreta with painless uterine rupture at the 2nd trimester. *Saudi Med J* 2002; 23: 857-9.
- 27 Kazandi M. Placenta percreta: report of two cases and review of the literature. *Clin Exp Obstet Gynecol* 2003; 30:70-2.
- 28 Abbas F, Talati J, Wasti S, et al. Placenta percreta with bladder invasion as a cause of life threatening hemorrhage. *J Urol* 2000; 164: 1270-4.