

# Tooth in Ethmoid Sinus: A Case Report

Mahmood Shishegar<sup>1</sup>, Akbar Bayat<sup>1</sup>,  
Tayebe Kazemei<sup>1</sup>

## Abstract

Ectopic eruption of teeth occurs in a variety of locations. Commonly seen in palate and maxillary sinus, they have also been reported in nasal cavity, orbit, mandibular condyle, coronoid process, and facial skin.

Here, we report a rare case of recurrent sinusitis caused by ectopic tooth in right ethmoid sinus and successful endoscopic removal of it. The symptoms of the patient disappeared after surgery. Such case has not been yet reported in the English literature.

Ectopic tooth is an uncommon cause of sinusitis. It should be considered in patients presenting with recurrent sinusitis unresponsive to medical treatment. Computed tomography of the sinuses is the modality of choice for diagnosis. Endoscopic sinus surgery is the best method for management of such cases.

**Iran J Med Sci 2009; 34(3): 220-222.**

**Keywords** • Ectopic tooth • ethmoid sinusitis • paranasal sinus

## Introduction

**E**ruption of teeth into the nasal cavity is a rare clinical entity. However, the identification of such teeth is important because they have the potential to cause considerable morbidity. Ectopic and supernumerary teeth may be present in many regions of the maxillofacial skeleton. Some common reported sites include the nasal cavity, maxillary sinus, palate, coronoid process, mandibular condyle, orbit, and skin.<sup>1,2</sup> Ectopic teeth may be supernumerary, deciduous, or permanent. Although etiology of the eruption of a tooth is unclear, developmental disturbances such as cleft palate, displacement of teeth by trauma or cyst, infection, genetic factors, crowding and dense bone are the suspected clinical conditions.<sup>2</sup>

We, here report a successful endoscopic removal of an ectopic tooth, which was located in the right ethmoid sinus.

## Case Report

A 20-year-old man referred to the Department of Otolaryngology, Head, and Neck Surgery of Khalili Hospital affiliated to Shiraz University of Medical Sciences in January 2008 because of recurrent sinusitis, dull facial pain in right side, and posterior nasal discharge. The symptoms persisted despite previous medical treatment (including different antibiotics such as oral high dose amoxicillin and cefixime, intranasal corticosteroid and decongestant) for 1 year.

General medical and family histories were unremarkable. His physical examination was normal but otolaryngologic examination showed nasal discharge in right side. Nasal endoscopy

<sup>1</sup>Department of Otolaryngology,  
Khalili Hospital,  
Shiraz University of Medical Sciences,  
Shiraz, Iran.

### Correspondence:

Mahmood Shishegar MD,  
Department of Otolaryngology,  
Khalili Hospital,  
Shiraz University of Medical Sciences,  
Shiraz, Iran.

**Tel/Fax:** +98 711 6471478

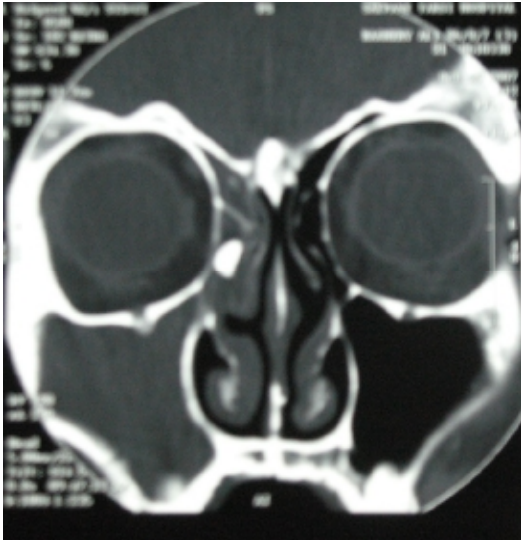
**Email:** [drshishegar@yahoo.com](mailto:drshishegar@yahoo.com)

Received: 29 September 2008

Revised: 3 January 2009

Accepted: 12 February 2009

revealed some polyps in right nasal cavity with purulent discharge in middle meatus. Computed tomography of paranasal sinuses showed a radiopaque mass resembling a tooth in right ethmoid sinus (figure 1).



**Figure 1:** Coronal computed tomography of paranasal sinus showing the mass in right ethmoid sinus.

Endoscopic removal of the mass with anterior and posterior ethmoidectomy was performed under general anesthesia using a 4-mm, 0 degree telescope. The mass was confirmed to be a tooth according to morphological and histological examinations. The patient's symptoms disappeared after the operation. He was prescribed oral amoxicillin with nasal saline irrigation for 2 weeks after operation. One-year follow-up showed no recurrence of symptoms. He did not need any other medication during the follow-up period.

## Discussion

Intranasal ectopic teeth are rare. Yeung and Lee reviewed the literature and found a total of 41 well-documented cases.<sup>1</sup> The age of the patients ranged from 3 to 62 years with mild male predominance. In regard to location, there was no side predilection in the literature.<sup>1,2</sup> The teeth in question were said to have arisen mostly from the permanent dentition or to have been supernumerary.<sup>3-5</sup> Ectopic eruption of teeth occurs in a variety of locations including the nasal cavity, maxillary sinus, coronoid process, mandibular condyle, facial skin, and orbit.<sup>2</sup> Although the cause of ectopic teeth remains unclear, some theories have been proposed. These theories include displacement of teeth by trauma to the oral cavity region,<sup>2</sup> osteomyelitis of maxilla,<sup>6</sup> incomplete

union of embryonic process as in cleft palate,<sup>1</sup> and space restriction caused by crowding of dentition.<sup>7</sup>

It has been postulated that a genetic defect may exist for some inherited dental anomalies and that a common defect may result in different phenotypic manifestations, including missing, malformed, or ectopic and malpositioned teeth.<sup>8</sup> Some ectopic teeth may also develop from aberrant, extraodontogenic epithelium.<sup>9</sup>

Ectopic teeth may be asymptomatic or may present with a variety of symptoms.<sup>2</sup> These include facial pain, nasal discharge, external deformities, recurrent epistaxis, foul-smelling rhinorrhea, and headaches.<sup>2</sup> Jude and co workers, reported a case with facial asymmetry because of bilateral ectopic third molars in the maxillary sinus causing osteomeatal complex obstruction.<sup>7</sup>

The diagnosis of an intranasal tooth can be made by either clinical examination or radiographic examination. Plain film imaging is inadequate for localizing the ectopic tooth but computed tomography is the modality of choice to confirm the diagnosis and to avoid unnecessary medical treatment.<sup>10,11</sup>

Complications of sinonasal teeth include bacterial sinusitis, aspergillosis, and naso-oral fistulas.<sup>9</sup> The differential diagnoses of intranasal teeth include rhinoliths, foreign bodies, bony sequestra, neoplasms, and exostoses. Surgical removal of symptomatic intranasal teeth is the preferred treatment.<sup>12</sup> Endoscopic surgery is effective, and is safer than the conventional open surgery.<sup>13</sup> This method can also yield to cosmetically satisfactory results.<sup>14</sup>

In the present report, endoscopic removal of the intraethmoid tooth resulted in complete resolution of symptoms of recurrent sinusitis and 12-month follow-up showed no recurrence of symptoms.

In summery, ectopic tooth is an uncommon cause of sinusitis. Some differential diagnoses of a radiopaque mass in sinuses are osteoma, foreign body, and rhinolithiasis. However otolaryngologists should be aware of this disease entity when encountering patients presenting with recurrent sinusitis unresponsive to medical treatment.

**Conflict of Interest:** None declared

## References

- 1 Yeung KH, Lee KH. Intranasal tooth in a patient with a cleft lip and alveolus. *Cleft Palate Craniofac J* 1996; 33: 157-9.
- 2 Smith RA, Gordon NC, De Luchi SF. Intranasal teeth: Report of two cases and

- review of the literature. *Oral Surg Oral Med Oral Pathol* 1979; 47: 120-2.
- 3 Lee FP. Endoscopic extraction of an intranasal tooth: a review of 13 cases. *Laryngoscope* 2001; 111: 1027-31.
  - 4 Carve DD, Peterson S, Owens T. Intranasal teeth: a case report. *Oral Surg Oral Med Oral Pathol* 1990; 70: 804-5.
  - 5 Lee GS, Lee GY, Hong SL, Shin JK. Supernumerary tooth in nasal cavity: report of 1 case. *Korean J Otolaryngols* 1998; 41: 949-51.
  - 6 Dayal PK, Dewan SK, Bihani VK, Dave CJ. Eruption of a tooth into the nasal cavity due to osteomyelitis. *J Laryngol Otol* 1981; 95: 509-12.
  - 7 Jude R, Horowitz J, Loree T. A case report. Ectopic molars that cause osteomeatal complex obstruction. *J Am Dent Assoc* 1995;126:1655-7.
  - 8 Kotsomitis N, Freer TJ. Inherited dental anomalies and abnormalities. *ASCD J Dent Child* 1997; 64: 405-8.
  - 9 El -Sayed Y. Sinonasal teeth. *J Otolaryngol* 1995; 24: 180-3.
  - 10 Baykul T, Doğru H, Yasan H, Cina Aksoy M. Clinical impact of ectopic teeth in the maxillary sinus. *Auris Nasus Larynx* 2006; 33: 277-81.
  - 11 Srinivasa Prasad T, Sujatha G , Niazi TM, Rajesh P. Dentigerous cyst associated with an ectopic third molar in the maxillary sinus: a rare entity. *Indian J Dent Res* 2007; 18: 141-3.
  - 12 Alexandrakis G, Hubbell RN, Aitken PA. Nasolacrimal duct obstruction secondary to ectopic teeth. *Ophthalmology* 2000; 107: 189-92.
  - 13 Buchanan MA, Prince SE, Prinsley PR. Frontal mucocele caused by an ectopic maxillary tooth. *J Laryngol Otol* 2008; 122: 384-5.
  - 14 Kim DH, Kim JM, Chae SW, et al. Endoscopic removal of an intranasal ectopic tooth. *Int J Pediatr Otorhinolaryngol* 2003; 67: 79-81.