

A Child with Intestinal Basidiobolomycosis

Reza Arjmand¹, Abdollah Karimi²,
Anahita Sanaei Dashti², Maryam
Kadivar³

Abstract

Fungal infections of the gastrointestinal tract are not common in children, especially in immunocompetent ones. In this case report we describe a child who was presented with abdominal pain and mass, bloody diarrhea and fever. He was treated for amebiasis, but due to treatment failure and deterioration of his condition, he underwent a laparotomy. Histologic examination of the excised bowel in the second look revealed Basidiobolomycosis, a fungus belonging to the order Entomophthorales. The signs, symptoms, treatment and diagnosis of the present case indicate that fungal infections must be considered not only in immunocompromised patients with abdominal pain and mass, but also in apparently immunocompetent ones.

Please cite this article as: R. Arjmand, A. Karimi, A. Sanaei Dashti, M. Kadivar. A Child with Intestinal Basidiobolomycosis. Iran J Med Sci. 2012;37(2):134-136.

Keywords • Mucormycosis • zygomycosis • gastrointestinal

Introduction

Zygomycosis, encompassing mucormycosis and entomophthoromycosis, are rare but important infections in children. Entomophthoromycosis, consist of both conidiobolomycosis and basidiobolomycosis. Historically, they have been known to cause skin and soft-tissue infections in otherwise healthy individuals in tropical areas of Africa, South America, and Asia. Visceral involvement is extremely unusual.¹ Although basidiobolomycosis is known through its skin lesions, its visceral involvement have been rarely reported.¹⁻³ Basidiobolomycosis of the gastrointestinal tract is an uncommon event, and less than 20 cases, mostly from Saudi Arabia, Kuwait, Nigeria, USA, and Brazil, have been reported worldwide.³ Basidiobolomycosis of the alimentary tract can manifest as abdominal pain, nausea, vomiting, diarrhea, or abdominal mass. Unfortunately, the clinical impressions are often neoplasm or chronic infections (rhabdomyosarcoma of pelvis, gastrointestinal stromal tumor and lymphoma as well as tuberculosis).³ In this report we present a case of intestinal basidiobolomycosis that was not diagnosed until after bowel resection.

Case Description

A 12-year-old boy presented with abdominal pain, bloody diarrhea, fever and vomiting that had started 1.5 months ago. He was treated with metronidazole with the impression of amebiasis. Due to lack of response, ceftriaxone and azithromycin were also prescribed, without any benefit. Abdominal sonography reported the presence of an intestinal abscess. Abdominal CT scan showed increased thickness of the descending colon and patchy enhancement and stranding of the surrounding peritoneal fat. Ameboma was diagnosed and he received metronidazole for the second time without any improvement. Due to aggravation of the abdominal pain and fever, he was re-admitted. His fever used to increase at nights, and was accompanied by chills,

¹Department of Pediatric Infectious Diseases, Pediatric Infections Research Center, Shahid Beheshti University of Medical Sciences, Tehran, Iran.

²Department of Pediatric Infectious Diseases, Pediatric Ward, Pediatric Infections Research Center, Shahid Beheshti University of Medical Sciences, Tehran, Iran.

³Department of Pathology, Pathology Ward, Tehran University of Medical Sciences, Tehran, Iran.

Correspondence:

Anahita Sanaei Dashti MD,
Pediatric Infections Research Center,
Mofid Children's Hospital,
Shahid Beheshti University of Medical
Sciences, Dr. Shariati Ave.
Tehran, Iran.

Tel/Fax: +98 21 22226941

Email: anahita_sam@yahoo.com

Received: 1 May 2011

Revised: 8 June 2011

Accepted: 24 July 2011

nausea and vomiting. He also had a remarkable loss of appetite, and lost about eight kilograms during a two months period.

Clinical and laboratory data were as follows:

Vital signs: Temp=37°C, respiratory rate (RR)=28/min, pulse rate (PR)=105/min, Systolic blood pressure (SBP)=90 mm Hg).

Abdomen was soft, without any organomegaly or tenderness.

WBC=28100/mm³, PMN=65%, Lymph=16%, Eos=16%, Band=2%, Mono=1%

Hgb=10.4 g/dl, RBC=4.51million/mm³, MCV=76.5 fl, Platelets=520000/mm³

ESR=14mm/hr, CRP=3+

Stool examination: mucus=3+, RBC=40-45/hpf, WBC=10-15hpf/, Cyst or ova: negative.

Abdominal Sonography: Diffuse and severe thickening of the descending colon wall was present, seen as a 105x54x35 mm mass with a 19x8 mm-sized fluid collection in the upper part of the thickened portion of the colon. Wall thickness was 17-22 mm on each side of the lumen. With primary diagnosis of intestinal tumor, laparotomy and resection of part of the involved colon was done. The reported pathology was in favor of Toxocariasis, but on another review of the specimen, diffuse granulomatous inflammation of the pericolic fat with marked eosinophilia and vascular involvement, in favor of mucormycosis was

reported (figures 1, 2). The report was confirmed by a 3rd pathologist. Amphotericin B was started but due to lack of defervescence after one week it was discontinued and posaconazole was started.

Discussion

Zygomycetes causing zygomycosis are alienated into two orders, the Mucorales and the Entomophthorales. It is relatively rare, with an annual rate of 1.7 infections per 1 million inhabitants in the United States.⁴ Contrary to mucormycosis, entomophthoromycosis is usually a chronic nonangioinvasive infection in those who are immunocompetent. Case series of this invasive disease have been reported in both immunocompromised and immunocompetent patients.^{5,6} Infections caused by Entomophthorales include both conidiobolomycosis and basidiobolomycosis, with the latter being the most common cause of the disease.³ It seems that Entomophthoromycosis is age related. Conidiobolomycosis is uncommon in children, but 88% of basidiobolomycosis cases occur in patients younger than 20 years.⁷ Historically, they have been known to cause skin and soft-tissue infections in otherwise healthy individuals in tropical areas of Africa, South America, and Asia. Visceral involvement is extremely unusual and so far has been reported only in association with Basidiobolus. *B. ranarum* was first isolated in 1955 from decaying plants in the United States, and was subsequently found in soil and vegetation throughout the world. *B. ranarum* may also be present as a commensal in the intestinal tracts of frogs, toads, turtles, chameleons, horses, and dogs. The first human case of infection caused by *B. ranarum* was one of subcutaneous mycosis, reported in 1956 in Indonesia, and other cases subsequently occurred in India, Africa, and South America. In 1978 the first culture-proven case of invasive basidiobolomycosis of the maxillary sinus was reported in the United States, and reports of visceral involvement followed afterwards.¹ Basidiobolomycosis can involve any region of gastrointestinal tract including stomach, duodenum, pancreas, liver, terminal ileum, cecum, ascending colon, transverse colon, rectum, and biliary system. The site of involvement in the present case was descending colon.⁸

Yousef describe six cases of gastrointestinal basidiobolomycosis of stomach and intestine. Specimens were characterized by marked mural thickening with fibrosis, prominent tissue eosinophil infiltration and palisading granulomatous inflammation around pale fungal hyphae. There was colonic perforation in two cases. According to their report, Basidiobolus *ranarum* hyphae (associated with spore-like spherules in four cases) were identified within tissue sections; the irregularly branched, thin-walled, occasionally septated

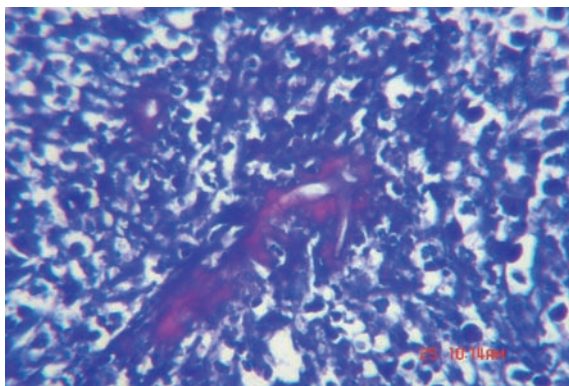


Figure 1: A Splendore-Hoeppli phenomenon, consisting of hyphae surrounded by eosinophilic material.

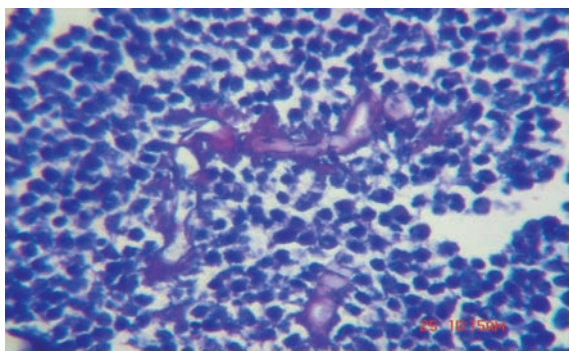


Figure 2: Histopathologic examination of affected tissues shows areas of acute and chronic inflammation in association with broad hyphal elements that display septations. No necrosis is seen. (PAS stain x40).

hyphae were typically surrounded by a thick eosinophilic cuff (Splendore-Hoepli phenomenon).²

Geramizadeh et al reported three cases with complaints of constipation, rectal bleeding, abdominal distension and intestinal obstruction. Other symptoms reported in the literature include fever, sweats, diarrhea, memory loss, rectal pain, constipation, anorexia, fatigue, mucus discharge, nausea and vomiting.³

Owing to vague complaints, the disease is generally confused with gastrointestinal malignancies, inflammatory bowel diseases, amebiasis or dysentery. Due to rarity of the disease, diagnosis is often made with some delay and after tissue resection and microscopic examination. Our patient was sometimes treated for amebic colitis and at other times as a case of bacterial dysentery; he eventually underwent bowel resection with the impression of intestinal tumor.

Typically histopathologic findings show areas of acute and chronic inflammation together with broad hyphal elements that may or may not display septations. The hyphae are more visible with hematoxylin and eosin staining than with more specific fungal stains. The tendency for vascular invasion typical of mucormycosis does not occur with entomophthoromycosis, however, and necrosis is uncommon. Characteristic findings include broad, sparsely septated hyphae surrounded by eosinophilic granular material (Splendore-Hoepli phenomena). Tissue eosinophilia and granulomatous inflammation are usual. Peripheral eosinophilia may also be present, but cultures from the infected site are often negative.^{2,4,7-9} Owing to the lack of reliable serological markers and difficulties in culturing the fungus, the diagnosis of mucormycosis is often through histopathologic assessment of the excised tissue.^{10,11} Our patient's pathologic report of the excised bowel pointed to toxocara, but a more meticulous review by two other experts revealed the accurate diagnosis. After starting posaconazole, patients's symptoms gradually subsided, and he got afebrile within about a few weeks. In follow-up visits he did not have any complaint.

Conflict of interest: None declared.

References

- 1 Zavasky DM, Samowitz W, Loftus T, Segal H, Carroll K. Gastrointestinal zygomycotic infection caused by *Basidiobolus ranarum*: case report and review. *Clin Infect Dis*. 1999;28:1244-8. doi: 10.1086/514781. PubMed PMID: 10451160.
- 2 Yousef OM, Smilack JD, Kerr DM, Ramsey R, Rosati L, Colby TV. Gastrointestinal basidiobolomycosis. Morphologic findings in a cluster of six cases. *Am J Clin Pathol*. 1999;112:610-6. PubMed PMID: 10549247.
- 3 Geramizadeh B, Modjalal M, Nabai S, Banani A, Forootan HR, Hooshdaran F, et al. Gastrointestinal zygomycosis: a report of three cases. *Mycopathologia*. 2007;164:35-8. doi: 10.1007/s11046-007-9022-y. PubMed PMID: 17554638.
- 4 Zaoutis TE, Steinbach WJ. Zygomycosis. In: Feigin RD, Cherry J, Demmler-Harrison GJ, editors. *Textbook of pediatric infectious diseases*. 6th ed. Philadelphia: Saunders; 2009. p. 2813-21.
- 5 Walker SD, Clark RV, King CT, Humphries JE, Lytle LS, Butkus DE. Fatal disseminated *Conidiobolus coronatus* infection in a renal transplant patient. *Am J Clin Pathol*. 1992;98:559-64. PubMed PMID: 1334363.
- 6 Bigliazzi C, Poletti V, Dell'Amore D, Saragoni L, Colby TV. Disseminated basidiobolomycosis in an immunocompetent woman. *J Clin Microbiol*. 2004;42:1367-9. doi: 10.1128/JCM.42.3.1367-1369.2004. PubMed PMID: 15004122; PubMed Central PMCID: PMC356830.
- 7 Kontoyiannis DP, Lewis RE. Agents of mucormycosis and entomophthoromycosis. In: Mandell GL, Bennett JE, Dolin R. *Principles and practice of infectious diseases*. 7th ed. Philadelphia: Churchill livingstone; 2010. p. 3257-69.
- 8 Khan ZU, Khoursheed M, Makar R, Al-Waheeb S, Al-Bader I, Al-Muzaini A, et al. *Basidiobolus ranarum* as an etiologic agent of gastrointestinal zygomycosis. *J Clin Microbiol*. 2001;39:2360-3. doi: 10.1128/JCM.39.6.2360-2363.2001. PubMed PMID: 11376094; PubMed Central PMCID: PMC88148.
- 9 Ribes JA, Vanover-Sams CL, Baker DJ. Zygomycetes in human disease. *Clin Microbiol Rev*. 2000;13:236-301. doi: 10.1128/CMR.13.2.236-301.2000. PubMed PMID: 10756000; PubMed Central PMCID: PMC100153.
- 10 Eucker J, Sezer O, Graf B, Possinger K. Mucormycoses. *Mycoses*. 2001;44:253-60. doi: 10.1046/j.1439-0507.2001.00656.x. PubMed PMID: 11714058.
- 11 Farhadieh R, Salardini A. Free perforation of sigmoid colon secondary to invasive mucormycosis in a Critically Ill patient. *Iran J Med Sci*. 2008;33:180-2.