

Immunohistochemistry Study in a Case of Nephrogenic Adenoma of Bladder

Akbar Safaei¹, Mohamad Reza Farzaneh¹, Ali Reza Amin Sharifi²

Abstract

Nephrogenic adenoma is a rare benign lesion of bladder that may be confused with malignant lesions. There is a strong relation with urinary tract irritation and intravesicle instrumentations. Nephrogenic adenoma was initially thought to originate from urothelial metaplasia; however, no solid proof is available. We present a case of 55-year-old lady with urinary problem. Cystoscopic examination showed a sessile mass, and biopsy revealed circumscribed proliferation of tubules, cysts, and papillae that were lined by low cuboidal to columnar epithelial cells. Nephrogenic adenoma can be a significant diagnostic pitfall due to the presence of certain histological features such as the presence of enlarged nuclei with prominent nucleoli. Immunohistochemistry study was strongly positive for CK7, P504S, CD10, and EMA, but negative for CK20, PSA, and P63.

Please cite this article as: A. Safaei, M.R. Farzaneh, A.R. Amin Sharifi. Immunohistochemistry Study in a Case of Nephrogenic Adenoma of Bladder. Iran J Med Sci. 2012;37(2):137-140.

Keywords • Bladder tumor • renal stone • immunohistochemistry

Introduction

Nephrogenic adenoma is a rare lesion of the urinary bladder that may arise and induced by many inflammatory insults such as recurrent infections, recurrent renal stone, intravesical therapy, bladder diverticula, renal transplantation, foreign bodies, chemical agents, radiation therapy, and other chronic irritative factors.¹ In 1954, Mostofi reported that the urinary bladder epithelium had the ability to transform into several morphologic types under appropriate stimulation and suggested that squamous and glandular metaplasia of the urothelium is seen frequently in association with chronic infection.¹

Nephrogenic adenoma (nephrogenic metaplasia) shows a male predominance with a male to female ratio of 2:1, and occurs over a wide age range (4-81 years). Although most common in adults, approximately 10% of nephrogenic adenomas have been observed in children.² In 1950 Friedman and Kuhlenbeck described eight such cases as nephrogenic adenoma resembling aberrant tubules of the kidney.³ The exact pathogenesis of the disease is uncertain. It may be a metaplastic lesion, or originate from embryonic tissue. It may also be a metaplasia that occasionally coexists with multifocal urothelial carcinoma.⁴⁻⁶ The origin of the tumor is uncertain, and many believed that it might originate from embryonic mesonephroid tissue.⁷ The majority of reports indicate that this type of lesion is due to urothelial injury as a result of previous surgery or long-term inflammation. Immunosuppressive therapy as in renal transplantation and intravesical drug (BCG) infusion are suspected causes in nephrogenic adenoma.

The clinical and cystoscopic characteristics of nephrogenic

¹Department of Pathology, Molecular Pathology and Cytogenetic Ward, School of Medicine, Shiraz University of Medical Science, Shiraz, Iran.

²Department of Urology, School of Medicine, Shiraz University Medical Science, Shiraz, Iran.

Correspondence:

Mohamad Reza Farzaneh MD,
Department of Pathology, Molecular Pathology and Cytogenetic Ward, School of Medicine, Zand Avenue, Shiraz, Iran.

Tel/ Fax: +98 711 2301784

Email: Mrfarzaneh@yahoo.com

Received: 21 August 2011

Revised: 23 October 2011

Accepted: 13 November 2011

adenoma are not diagnostic so cytomorphology, and immunohistochemistry study are needed to differentiate nephrogenic adenoma from malignant lesions, and to avoid erroneous therapeutic approach. There are few reports about using immunohistochemistry technique in diagnosis of nephrogenic adenoma. Nephrogenic adenoma is typically positive for cytokeratin 7 (CK7), α -methylacyl CoA racemase (AMACR) (P504S), PAX2 and epithelial membrane antigen (EMA), and are usually negative for P63, cytokeratin 20 (CK20), and prostatic specific antigen (PSA).

Case Description

A 55-year-old female was admitted to Shahid Faghihi Hospital, Shiraz, Iran with chief complaint of irritative lower urinary tract symptoms and intermittent gross hematuria. Four years ago she had developed renal stone, and had been subjected to percutaneous nephrolithotomy. Her urine analysis showed red urine containing a large number of red and white blood cells, and few bacteria. Ultrasonographic study showed a lesion at left lateral wall of bladder. Cystoscopic examination revealed a sessile 3x3 centimeters lesion in the left lateral wall of bladder.

She was scheduled for transurethral resection. The procedure and its recovery were uneventful. Biopsy specimen was sent to our laboratory. Microscopic examinations of hematoxylin eosin-stained slides showed irregular proliferation of small tubules, which were lined by single-layer low cuboidal epithelium in myxoid and inflammatory background in the lamina propria (figure 1). There were also some cord-like structures and single cell proliferation. Immunohistochemistry analysis was performed on formalin fixed and paraffin embedded 4- μ m sections. The tissue sections deparaffinized and treated with 3% hydrogen peroxide and antigen retrieval was done. The slides were then stained with a polymer-based detection system (Dako's EnVision system).

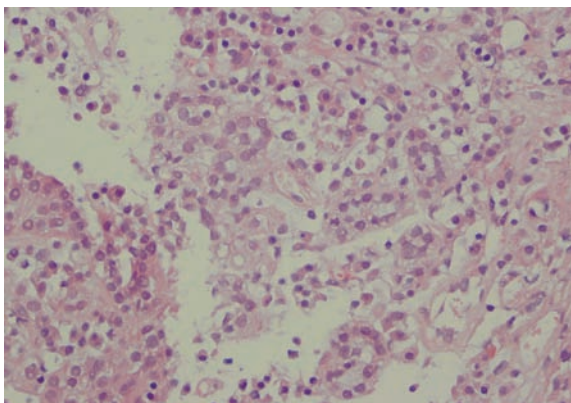


Figure 1: Hematoxylin-eosin staining of bladder lesion from a 25-year-old man. It shows benign looking tubular structures indicative of nephrogenic adenoma.

Immunohistochemistry study showed positive reactivity for P504, CD10, EMA and CK7 (figures 2, 3, 4), but negative reactivity for PSA, P63 and CK20 (figures 5, 6). After five months follow up the patient showed decreased complaints, but she did not completely recovered and she did not come back for treatment either.

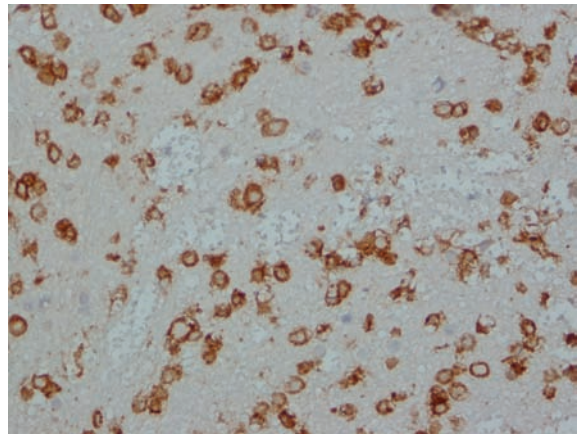


Figure 2: Nephrogenic adenoma. Immunohistochemistry test on paraffin embedded tissue revealed positive reaction for CD10 antibody.

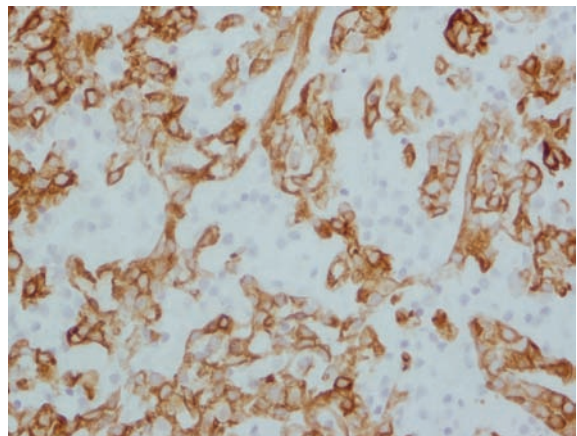


Figure 3: Nephrogenic adenoma. Immunohistochemistry test on paraffin embedded tissue revealed positive reaction for CK7 antibody.

Discussion

Nephrogenic adenoma is a rare bladder lesion presented with well-defined mass located mostly beneath the epithelium. In the past, it was believed that nephrogenic adenoma represented metaplasia of the urinary epithelium in response to inflammatory process. However, it has been demonstrated to result from urothelial shedding, and implant in injured area.

Adenocarcinoma of the bladder was reported to occur two year after nephrogenic adenoma in a 25-year-old man.⁸ Few reports have examined the use of immunohistochemical findings in the diagnosis of nephrogenic adenoma. Alsanjary et al. studied the morphological and

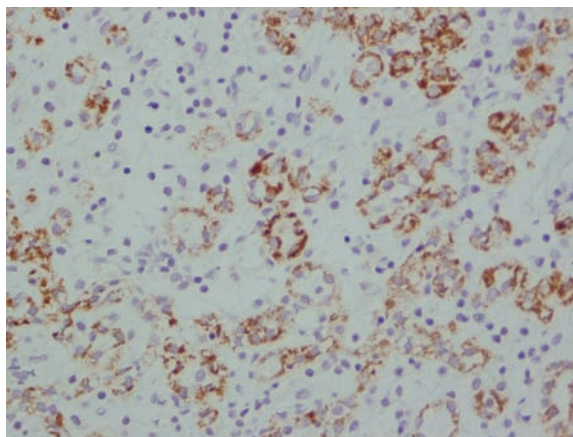


Figure 4: Nephrogenic adenoma. Immunohistochemistry test on paraffin embedded tissue revealed positive reaction for P504 antibody.

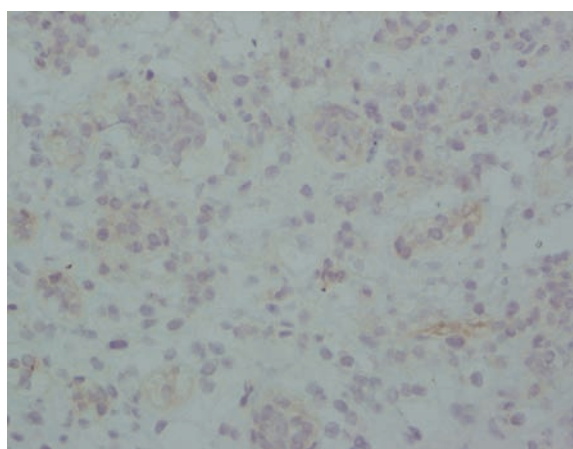


Figure 5: Nephrogenic adenoma. Immunohistochemistry test on paraffin embedded tissue revealed negative reaction for P63 antibody.

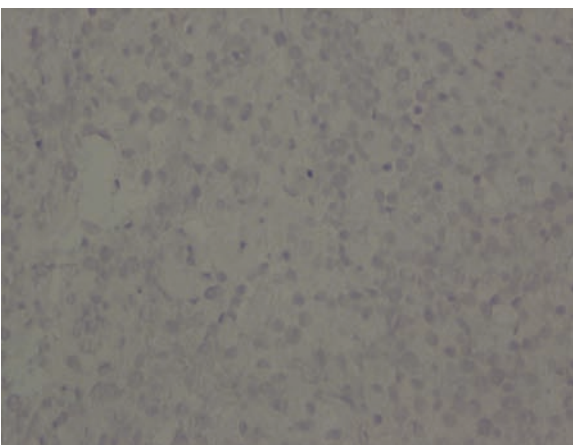


Figure 6: Nephrogenic adenoma. Immunohistochemistry test on paraffin embedded tissue revealed negative reaction for PSA antibody.

immunohistochemical features for differential diagnosis of nephrogenic adenoma from clear cell adenocarcinoma.⁹ Immunohistochemical study can differentiate nephrogenic adenoma from malignant process, and define the origin of adenoma. Immunohistochemistry studies have shown that PAX2 was positive only in remnant of

fetal renal tubules and nephrogenic adenoma, and negative in malignant process such as prostatic adenocarcinoma.¹⁰ Cytoplasmic staining for CK7 and absence of staining for PSA is in favor of nephrogenic adenoma. Alpha-methylacyl-CoA racemase (AMACR, P504S), which is the most useful marker for the diagnosis of prostatic adenocarcinoma, is detected in nephrogenic adenoma of urinary bladder.^{10,11} There are some problems in the differential diagnosis of nephrogenic adenoma from clear cell carcinoma of bladder, because it shows foci with tubular, cystic and papillary configuration, but no dysplastic changes. Nephrogenic adenoma can be differentiated from clear cell carcinoma by PAX2 marker.¹² Reporting eight patients with nephrogenic adenoma, Chen et al. found high postoperative recurrence, and recommended careful long-term follow up.¹³ Olivia and Young reviewed 80 cases of nephrogenic adenoma, which showed a trend of male predominance.¹⁴ Koirala et al. reported a case of ureter nephrogenic adenoma with intraluminal PAS positive material.¹⁵ Jalpota reported an extensive involvement of bladder by nephrogenic adenoma in patient with renal allograft transplant.¹⁶

Nephrogenic adenoma is a benign metaplastic response to urothelial injury, and may mimic malignant process. In the present case bladder biopsy was done with high suspicion for malignant lesion. However, immunohistochemical examination of the biopsy revealed positive findings for CK7, EMA, CD10 and AMACR, and negative findings for PSA, P63 and CK20. Such findings are in favor of nephrogenic adenoma as benign lesion.

The clinical and cystoscopic characteristics of nephrogenic adenoma are not diagnostic so cytology, and immunohistochemistry study are needed to differentiate nephrogenic adenoma from malignant lesions and to avoid erroneous therapeutic approach.

Conclusion

Nephrogenic adenoma is a benign metaplastic lesion with a broad histological variant. Some cases of nephrogenic adenoma are associated with diagnostic difficulty using certain histologic features, since they may mimic some features of malignant lesions. Therefore, immunohistochemical study can be used as ancillary test for definite diagnosis.

Conflict of interest: None declared.

References

- 1 Mostofi FK. Potentialities of bladder epithelium. *J Urol.* 1954; 71:705-14. PubMed PMID: 13163977.

- 2 Kunju LP. Nephrogenic adenoma: report of a case and review of morphologic mimics. *Arch Pathol Lab Med.* 2010;134:1455-9. PubMed PMID: 20923300.
- 3 Heidenreich A, Zirbes TK, Wolter S, Engelmann UH. Nephrogenic adenoma: A rare bladder tumor in children. *Eur Urol.* 1999;36:348-53. doi: 10.1159/000019998. PubMed PMID: 10473997.
- 4 Verit A, ILBEY O, Akalin T, Bayrak O. Nephrogenic Adenoma of the bladder. *Eastern Journal of Medicine.* 1999;4:42-3.
- 5 Yaldiz M, Uzunlar Ak, Ozdmemir E, Ozaydin M. Nephrogenic adenoma of bladder: A case report. *Nagoya Med J.* 2000;44:13-5.
- 6 Franke EI, Misseri R, Cain MP, Kaefer M, Meldrum KK, Fan R, et al. Nephrogenic adenoma in augmented bladder. *J Urol.* 2011;186:1586-89. doi: 10.1016/j.juro.2011.04.015. PubMed PMID: 21862049.
- 7 Mazal PR, Schaufler R, Altenhuber-Müller R, Haitel A, Watschinger B, Kratzik C, et al. Derivation of nephrogenic adenomas from renal tubular cells in kidney-transplant recipients. *N Engl J Med.* 2002;347:653. doi: 10.1056/NEJMoa013413. PubMed PMID: 12200552.
- 8 Hungerhuber E, Bach E, Hartmann A, Frimberger D, Stief C, Zaak D. Adenocarcinoma of the bladder following nephrogenic adenoma: a case report. *J Med Case Reports.* 2008;2:164-8. doi: 10.1186/1752-1947-2-164. PubMed PMID: 18485239.
- 9 Alsanjari N, Lynch MJ, Fisher C, Parkinson MC. Vesical clear cell adenocarcinoma. V. Nephrogenic adenoma: a diagnostic problem. *Histopathology.* 1995;27:43-9. doi: 10.1111/j.1365-2559.1995.tb00289. PubMed PMID: 7557905.
- 10 Tong GX, Melamed J, Mansukhani M, Memeo L, Hernandez O, Deng FM, et al. PAX2: a reliable marker for nephrogenic adenoma. *Mod Pathol.* 2006;19:356-63. doi: 10.1038/modpathol.3800535. PubMed PMID: 16400326.
- 11 Xiao GQ, Burstein DE, Miller LK, Unger PD. Nephrogenic adenoma: immunohistochemical evaluation for its etiology and differentiation from prostatic adenocarcinoma. *Arch Pathol lab Med.* 2006;130:805-10. PubMed PMID: 16740031
- 12 Hansel DE, Nadasdy T, Epstein JI. Fibromyxoid nephrogenic adenoma: a newly recognized variant mimicking mucinous adenocarcinoma. *Am J Surg Pathol.* 2007;31:1231-7. doi: 10.1097/PAS.0b013e31802e290d. PubMed PMID: 17667548
- 13 Chen CS, Cheng CL. Nephrogenic adenoma of the urinary bladder: clinical experience and review of the literature. *J Chin Med Assoc.* 2006;69:166-8. doi: 10.1016/S1726-4901(09)70199-6. PubMed PMID: 16689198
- 14 Oliva E, Young RH. Nephrogenic adenoma of the urinary tract: a review of the microscopic appearance of 80 cases with emphasis on unusual features. *Mod Pathol.* 1995;8:722-30. PubMed PMID: 8539229.
- 15 Koirala TR, Aftabuddin M, Chen HL, Islam N, Ishimastu T. Nephrogenic adenoma of the ureter--a case report. *Indian J Pathol Microbiol.* 1997;40:61-2. PubMed PMID: 9145615.
- 16 Jalpota Y, Tewari V, Madan R. Recurrent nephrogenic adenoma of urinary bladder in a renal allograft recipient--a case report. *Indian J Pathol Microbiol.* 2006;49:261-3. PubMed PMID: 16933732