

Pulmonary Embolism as a Rare Complication of Liver Hydatid Cyst: Report of Two Cases

Omar Toumi¹, MD;
Randa Salem², MD;
Sadok Ben Jabra¹, MD;
Ghedira Abdesslem¹, MD;
Faouzi Noomen¹, PhD;
Abdel Aziz Hamdi¹, PhD

¹Department of General Surgery,
Fattouma Bourguiba Hospital, Faculty
of Medicine, University of Monastir,
Monastir, Tunisia;

²Department of Radiology, Fattouma
Bourguiba Hospital, Faculty of Medicine,
University of Monastir, Monastir, Tunisia

Correspondence:

Omar Toumi, MD;
Department of General Surgery,
Fattouma Bourguiba Hospital, Faculty
of Medicine, University of Monastir,
Monastir, 5000.Tunisia
Tel: +21 69 4080808
Fax: +21 67 3460678
Email: toumiomar2010@yahoo.com
Received: 22 October 2016
Revised: 26 December 2016
Accepted: 15 January 2017

Abstract

Hydatid cyst is a helminth infection. The rupture of a hepatic hydatid cyst in inferior vena cava is a rare and lethal complication. Pulmonary embolism is the commonest manifestation. The diagnosis of hydatid cyst is made by histopathological or serological examination, and imaging may suggest the probability of hydatid cyst. Surgical treatment should be performed with caution and always under vascular control. We present two cases of hydatid cyst ruptured into the inferior vena cava. The patients also presented with dyspnea, hemoptysis, and intermittent cough at the time of admission. This presentation will be accompanied by a brief review of the literature. The radiological findings suggested the diagnosis. The first patient had a fatal hydatid pulmonary embolism and death occurred on the second day of hospitalization. The second patient refused surgery. These cases also exemplify the clinical and radiographic findings as well as the management of this complication.

Please cite this article as: Toumi O, Salem R, Jabra SB, Abdesslem G, Noomen F, Hamdi AA. Pulmonary Embolism as a Rare Complication of Liver Hydatid Cyst: Report of Two Cases. *Iran J Med Sci*. 2018;43(2):214-217.

Keywords • Echinococcus • Echinococcosis • Pulmonary embolism • Vena cava • Inferior • Tomography

What's Known

- The rupture of a hepatic hydatid cyst (HHC) in the inferior vena cava (IVC) is a rare and lethal complication.
- Clinical and radiological signs of HHC are not specific.

What's New

- There are difficulties in diagnosing hydatid cyst of the liver open into the inferior vena cava.
- Therapeutic strategy is used to prevent some intra-operative fatal accidents.
- Pre-operative imaging is helpful to detect complications related to all hydatid cyst of the liver.

Introduction

Hydatid cyst is a helminth infection caused by the development of the larval form of dog taenia "Echinococcus granulosus"¹ in humans. Its severity is mainly due to its complications, especially vascular ones, such as an occlusion of the pulmonary arteries. The latter are extremely rare and lethal.² The cardiovascular hydatid cyst complications vary between 0.02% to 2%.³ It is a surgical emergency with high morbidity and mortality rates.² The diagnosis can be confused with a pulmonary embolism due to the similarity in clinical symptoms such as cough, hemoptysis, and acute onset of chest pain.⁴

We report two cases of hydatid cyst embolization to pulmonary arteries. The diagnosis was clinical and confirmed by radiological and biological findings. The objective of the current study was to evaluate the clinical and radiological findings of this rare complication.

Case Presentation

Herein, we report two cases for which patients' written consent and permission to publish this article have been obtained.

Case 1

A 35-year-old male farmer was referred to our hospital with mild dyspnea, hemoptysis, abdominal pain, and intermittent cough. He denied both weight loss and fever. He had no medical history. Physical examination revealed tenderness on the right upper quadrant. All blood investigations were normal except for total counts (15,600 cells/cum), presence of anti-hydatid cyst antibody (measured by ELISA), and blood eosinophilia (>5%). The radiography of the chest was normal. The abdominal ultrasound (US) revealed a hepatic cyst with multiple daughter cysts in the right lobe of the liver and multiple cystic structures in the inferior vena cava (IVC) secondary to the spread of the liver hydatid disease (figures 1 and 2). The CT scan confirmed multiple cystic structures within the IVC and pulmonary artery embolism. The diagnosis was an infected hydatid cyst associated with partial thrombosis of the IVC. The patient was given an anticoagulant with a curative dose; a medical treatment (albendazole) was prescribed.

The indication for surgery was retained for the hydatid cyst of the infected liver, which ruptured in the IVC. During his hospitalization, a fatal hydatid pulmonary embolism occurred and the patient was quickly intubated. Death occurred on the second day of hospitalization.

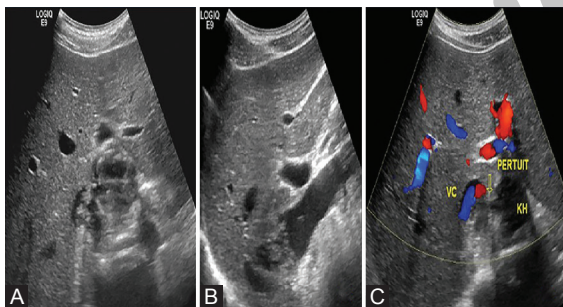


Figure 1: Axial (A) and sagittal (B) sonograms focusing on the liver shows hydatid cyst in the segment I ruptured into the vena cava and the hydatid materials in the light of the vena cava. The Doppler (C) shows the sluice of communication between the cyst and the vena cava and the circulating light is left of the vena cava.

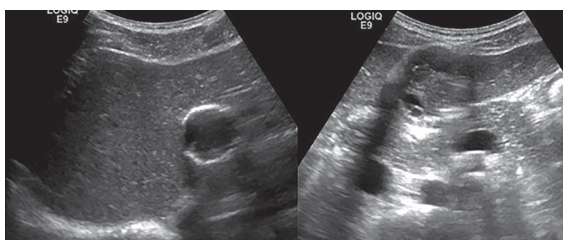


Figure 2: Sonograms focused on the hepatic parenchyma shows two different locations of the hydatid cyst in the left liver.

Case 2

A 30-year-old male butcher was admitted to our department for dyspnea, cough, and severe right upper quadrant pain. He had no medical history. Physical examination revealed tenderness on the right upper quadrant. The laboratory findings were normal except for an elevated liver function (alkaline phosphatase 432, U/L gamma glutamyl transpeptidase 252 U/L) and the presence of anti-hydatid cyst antibody (measured by ELISA). The abdominal ultrasonography (US) showed a hydatid cyst lesion in the liver, compressing the portal and hepatic veins. On Doppler US, a germinal membrane of the cyst was found to be extending into the inferior vena cava. A contrast-enhanced CT of the abdomen and chest was performed to delineate the extension of the germinal membrane of the cyst. It confirmed the findings of the ultrasound, and showed more enhancement defects of the segmental and subsections segmental pulmonary arteries filled with the material corresponding to hydatid embolism. The hydatid cyst was opened in the retrohepatic vena cava and remained only passing sluices enhancing after injection (figures 3 and 4). There was no hydatid cyst in the lung parenchyma.

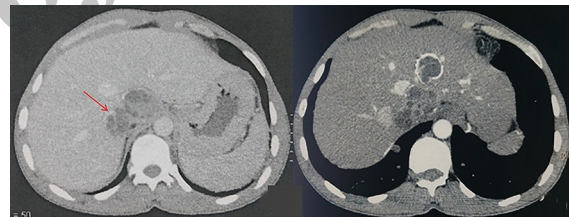


Figure 3: Axial CT section performed after intravenous injection of contrast agent confirms the findings of ultrasound. The hydatid cyst was opened in the retrohepatic vena cava and remained only passing sluices, which are enhanced after injection (arrow).

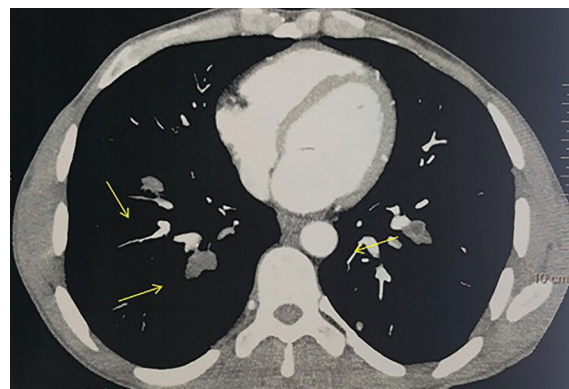


Figure 4: Axial CT section performed after intravenous injection of a contrast agent shows more enhancement defects (arrows) of the segmental and sub-sections segmental pulmonary arteries filled with the material corresponding to hydatid embolism.

During hospitalization, curative doses of anticoagulation were prescribed. After confirming the diagnosis, a surgery was indicated but was refused by the patient. Therefore, a medical treatment was initiated (albendazole) and taken for 9 months. A CT scan was performed after 9 months and showed no regression in the hydatid cyst size.

Discussion

Hydatid cyst is a helminth infection caused by the development of the larval form of dog taenia "Echinococcus granulosus"¹ in humans. It is very common in sheep raising Mediterranean countries. After ingestion, the embryos in the eggs are released and migrate frequently to the liver, lungs and rarely to any other organs in the body.^{2,5} Its severity is mainly due to its complications.¹ The most frequent one is rupture into the biliary tract leading to infection. Intravascular rupture is very rare and considered as a lethal emergency.³ The cardiovascular hydatid cyst complications vary between 0.02% to 2%.³ Only a few case reports of ruptured hepatic hydatid cyst in the IVC are reported in the literature.

Pulmonary embolism can occur either after a cardiac involvement by the cyst or after a fistulization of a hepatic hydatid cyst in the IVC or hepatic veins.^{6,7} Hence causing the migration of replicate vesicles in the venous to the right atrium as well as the right ventricle and finally to the pulmonary artery.³ In our cases, we believe that the starting point of hydatid cystic embolism was the daughter cysts migration from the liver, since, in both cases, there was a hepatic hydatid cyst attached to the IVC with intraluminal vesicle without any other localization.

Three types of clinical outcomes from pulmonary hydatid embolism have been reported in the literature: (i) acute fatal embolism, (ii) sub-acute embolism resulting in pulmonary hypertension and death in less than 1 year, and (iii) chronic pulmonary hypertension.⁸ The symptoms may range from simple discomfort associated with minor signs of allergy to anaphylactic shock.² In the acute period of ruptured cyst, the clinical presentation may simulate symptoms of thromboembolic disease.² Hemoptysis results from vascular invasion of the bronchial and pulmonary arteries.⁶ The risk of sudden death is important during this period (29% of cases) by massive pulmonary embolism and anaphylactic shock.³ Other symptoms are described in the literature, such as chest pain, cough, dyspnea.⁹ In our cases, the main symptoms were dyspnea, hemoptysis, and

intermittent cough.

The thoracic imaging may have an important income to guide the diagnosis, especially the helical CT, angiography, and MRI.⁸ They can locate the hydatid cysts, study their morphologies, and show their extension to the vascular branches. They may indicate endoluminal defects at the level of the pulmonary artery and/or its branches.⁸ On CT scan, the complicated intra-arterial embolism appears as a fluid mass density with limited enhancement of the wall after contrast injection.⁸ This was the case in our patients. The differential diagnoses in such cases are pulmonary thromboembolism and primary arterial tumors.⁶ In our cases, the hydatid pulmonary embolism confirmation was the result of combined CT scan results and serological data.¹⁰

Conclusion

Hydatid pulmonary embolism is a rare and lethal complication of hepatic hydatid cyst. The symptoms are not specific. The confirmation of its diagnosis remains difficult, but a combination of radiological results and serological data might be helpful. The surgical treatment is stringent and the efficiency of the medical treatment is still controversial.

Conflict of Interest: None declared.

References

1. Toumi O, Noomen F, Salem R, Rabeh H, Jabra SB, Korbi I, et al. Intraperitoneal rupture of hydatid cysts. *Eur J Trauma Emerg Surg.* 2016. doi: 10.1007/s00068-016-0662-9. PubMed PMID: 27084544.
2. Aribas OK, Kanat F, Turk-Aribas E, Erayman I, Yuksek T. Embolisation of hydatid cysts in the pulmonary artery presenting with haemoptysis. *Neth J Med.* 2007;65:109-11. PubMed PMID: 17387237.
3. Serraj M, Smahi M, Kamaoui I, El Houari A, Sahnoune F, Ouadnoui Y, et al. [Hydatid pulmonary embolism: A rare complication of hepatic hydatid cyst]. *Rev Mal Respir.* 2013;30:215-21. doi: 10.1016/j.rmr.2012.06.004. PubMed PMID: 23497931.
4. Lahdhili H, Hachicha S, Ziadi M, Thameur H. Acute pulmonary embolism due to the rupture of a right ventricle hydatid cyst. *Eur J Cardiothorac Surg.* 2002;22:462-4. PubMed PMID: 12204747.
5. Sirmali M, Gezer S, Yol S, Kaya S. Hydatid cyst of the pulmonary artery secondary to

- hepatic hydatid cyst embolism. *Acta Chir Belg.* 2006;106:441-2. PubMed PMID: 17017704.
6. Akgun V, Battal B, Karaman B, Ors F, Deniz O, Daku A. Pulmonary artery embolism due to a ruptured hepatic hydatid cyst: Clinical and radiologic imaging findings. *Emerg Radiol.* 2011;18:437-9. doi: 10.1007/s10140-011-0953-8. PubMed PMID: 21494880.
 7. Gilsanz V, Campo C, Cue R, Estella J, Estrada RV, Perez-oteiza C, et al. Recurrent pulmonary embolism due to hydatid disease of heart. Study of 3 cases, one with intermittent tricuspid valve obstruction (atrial pseudomyxoma). *Br Heart J.* 1977;39:553-8. PubMed PMID: 861098; PubMed Central PMCID: PMC483274.
 8. Herek D, Karabulut N. CT demonstration of pulmonary embolism due to the rupture of a giant hepatic hydatid disease. *Clin Imaging.* 2012;36:612-4. doi: 10.1016/j.clinimag.2011.10.020. PubMed PMID: 22920374.
 9. Smith GJ, Irons S, Schelleman A. Hydatid pulmonary emboli. *Australas Radiol.* 2001;45:508-11. PubMed PMID: 11903187.
 10. Karantanas AH, Bitsios G, Karaïskou E. Echinococcus of the pulmonary artery: CT, MRI and MRA findings. *Comput Med Imaging Graph.* 2000;24:265-7. PubMed PMID: 10842051.

Archive of SID