

Turner Syndrome: A Unique Mosaic Case with 45,X/47,XX,+21/46,XX Cell Lines

Mirela Mačkić-Đurović¹, PhD;
Melih Stomornjak-Vukadin², MD;
Slavka Ibrulj¹, PhD

¹Center for Genetics, Faculty of Medicine, University of Sarajevo, Sarajevo, Bosnia and Herzegovina;
²Laboratory of Human Genetics, Department of Pathology, Cytology and Human Genetics, University Clinical Center Sarajevo, Sarajevo, Bosnia and Herzegovina

Correspondence:

Mirela Mačkić-Đurović, PhD;
Center for Genetics, Faculty of Medicine,
University of Sarajevo, Čekaluša 90,
71000 Sarajevo,
Bosnia and Herzegovina
Tel/Fax: +38 733665949
Email: mirelamd@yahoo.com
Received: 03 April 2017
Revised: 15 May 2017
Accepted: 28 May 2017

What's Known

- Much is known about Turner and Down syndromes, but the literature refers to only a few cases with mosaicism consisting of 45,X/47,XX,+21.

What's New

- We describe a female with triple mosaicism (45,X/47,XX,+21/46,XX), who phenotypically did not seem to have Turner syndrome. Not until amniocentesis during her second natural pregnancy revealed that her fetus had Down syndrome did she know that she had Turner syndrome.

Abstract

We report an extremely rare case of Turner syndrome mosaicism in a 30-year-old woman. At least 100 metaphases were observed and analyzed through GTG banding with over 550 band resolutions observed. G-banded chromosome analysis revealed a mosaic female karyotype involving 3 different cell lines. One cell line (90% of the analyzed metaphases) presented monosomy X, while 6% of the cells showed trisomy of chromosome 21 and 4% of the cells exhibited a normal female karyotype. Fluorescence in situ hybridization with a locus-specific probe for trisomy 21 and CEP X for monosomy X substantiated the results obtained from karyotyping. Our patient had 2 natural pregnancies, both of which produced children with Down syndrome. In our patient, as is the case with other women with infertility, the necessary routine is cytogenetic analysis (together with genetic counseling). The same analysis can be helpful in implementing assisted reproductive techniques.

Please cite this article as: Mačkić-Đurović M, Stomornjak-Vukadin M, Ibrulj S. Turner Syndrome: A Unique Mosaic Case with 45,X/47,XX,+21/46,XX Cell Lines. *Iran J Med Sci*. 2018;43(4):436-439.

Keywords • Turner syndrome • Down syndrome • Mosaicism
• In situ hybridization • Fluorescence

Introduction

This study describes a rare mosaic of a woman with Turner syndrome. This syndrome is a common form of hypogonadism in women; 1 in every 2,500 female neonates is born with monosomy X. Monosomy X according to chromosomal analysis is comprised of homogeneous monosomy X (53.33% of cases), monosomy X mosaicism (22.52% of cases), partial monosomy X (20.36% of cases), and other forms (3.79% of cases).¹

Down syndrome is one of the most common chromosome abnormalities in humans in that it occurs in about 1 per 1,000 babies born each year.² The coexistence of double aneuploidy is extremely rare. The first reports on mosaicism related to 2 or more cell lines were published by Down–Turner, and the first case was reported in 1971.³ The actual number of such cases is not clear from the literature but is estimated to be from 22 to over 100. Reports on trisomy 21 combined with Turner syndrome have demonstrated different cytogenetic variants, the most frequent of which is the mosaicism of 2 clonal lines: 1 clone with trisomy 21 and 1 with monosomy X, with an incidence of 1 in 2,000,000 births.⁴ Since the same mechanisms resulting in the non-disjunction of both chromosomes can be proposed, it is unlikely that the occurrence of such double aneuploidy events is totally independent of each other. The most common features of Turner syndrome are short stature, gonadal dysgenesis, and somatic

stigmata. Individuals with Turner syndrome have normal intelligence.

Case Presentation

The patient was a 30-year-old woman, who was referred to our center for karyotype analysis. She had a history of 2 pregnancies. The first child died at birth and after cytogenetic analysis, it was established that the child had Down syndrome. During her second pregnancy, the patient underwent amniocentesis and the result showed that the child had Down syndrome.

On physical examination, it was observed that the patient had short stature (152 cm) and a short neck. Hormone findings revealed a rise in the estradiol level (340 pg/mL), while the other hormones such as progesterone (15 ng/mL) and follicle-stimulating hormone (7.3 mIU/mL) were within the limits of reference values.

The patient claimed that she had had problems with menstrual cycles up to age 18 but following hormonal therapy, she began to have a regular, normal cycle. She granted written consent to the publication of her case without revealing her personal data and images.

Cytogenetic analysis was conducted according to the standardized protocols for processing and analyzing peripheral blood samples. At least 100 metaphases were observed and analyzed through GTG banding with over 550 band resolutions observed. Karyotype was designated as per the International System for human Cytogenetic Nomenclature (ISCN).⁵ The analysis of the 100 metaphases showed the presence of 3 different cell lines. About 90% of the cells exhibited monosomy of chromosome X (45,X), 6% of the cells presented trisomy of chromosome 21 (47,XX, +21), and 4% of the cells presented 46,XX. According to the current literature, this is the first case with this mosaicism in a woman who became pregnant twice and on both occasions gave birth to children with Down syndrome. The final karyotype was identified as 45,X/47,XX,+21/46,XX.

The cytogenetic analysis was followed by the molecular analysis, fluorescence in situ hybridization (FISH). FISH was performed with an AneuVysion assay kit (Abbott-Vysis, USA). The protocol involved direct culture of the cells obtained from the blood sample. The cells were analyzed using a fluorescent microscope (Olympus BX61, Germany) with CytoVision software (CytoVision, AB Imaging, Germany). For each analyzed sample, at least 500 interphase nuclei were counted. FISH was carried out on the interphase cells using an LSI 21 (21q22.13-q22.2) probe for chromosome

21 and a CEP X (Xp11.1-q11.1) probe for the X chromosome. The LSI 21 probe identified 3 copies of the chromosome in 6% of the interphase nuclei, and the CEP X probe of 90% of the interphase nuclei found 1 X chromosome. The results of FISH are depicted in figures 1 and 2.

Discussion

Different X chromosome abnormalities, from the loss of 1 X chromosome in all or part of the cell lines to the abnormalities of the second X chromosome, are crucial to diagnose. Most girls are diagnosed during infancy or childhood on the basis of stigmata, heart malformations, and/or growth retardation in adolescence when there is no onset of puberty and in adulthood because of premature ovarian failure or infertility.⁶

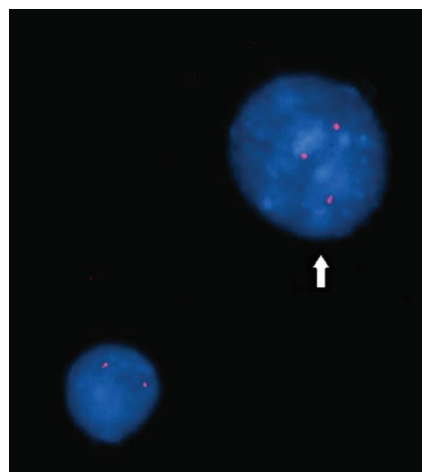


Figure 1: Interphase fluorescence in situ hybridization (FISH) result of the patient using the LSI 21 probe shows 2 cells. The cell with 3 red signals of the LSI 21 probe indicates trisomy 21.

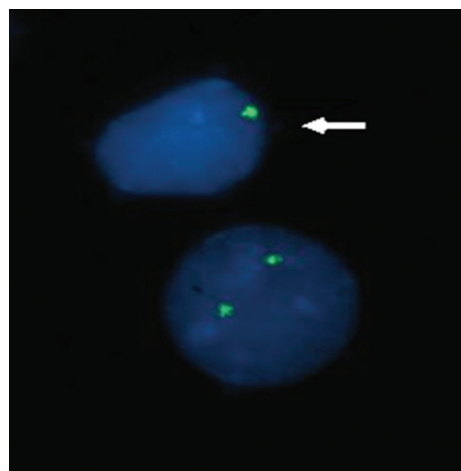


Figure 2: Interphase fluorescence in situ hybridization (FISH) result of the patient using the CEP X probe shows 2 cells. The cell with 1 green signal of CEP X indicates monosomy X.

People with a mosaic type Turner syndrome have diverse combinations and presentations of cell lines (when compared to others) and show a wide spectrum of different phenotypic expressions ranging from normal females and females with mixed gonadal dysgenesis and male pseudohermaphroditism to almost normal males. This may explain the difficulty in the diagnosis of Turner syndrome mosaicism.

Our patient's physical appearance (apart from her short stature and irregular menstrual cycle) did not call for cytogenetic analysis. She underwent karyotyping only after amniocentesis revealed signs of Down syndrome during her second pregnancy. One of the main characteristics of Turner syndrome is low reproductive potential, which correlates with ovarian dysgenesis induced by monosomy X. The case of our patient, who has 90% of her cells with monosomy X and has been pregnant twice, indicates that people with Turner syndrome can become pregnant, especially when it comes to the mosaic type. Women with Down syndrome are less fertile and often suffer miscarriages. According to the literature, few women with Down syndrome have had healthy children. In most cases, the children of this group of women also have Down syndrome. That was exactly the case with our patient. Aside from our patient's short stature and irregular menstrual cycle (she had her first cycles when she was 16), she never had any phenotypic marks of Down syndrome and Turner syndrome. Consequently, neither pediatricians nor gynecologists ever thought of any syndrome. Studies on patients with Turner syndrome have shown that pubertal development and ovarian function can sometimes be normal, with the development of mammary glands in 25% of the patients and spontaneous menarche in 3% of the cases with homogeneous monosomy X and 10% of the cases with monosomy X mosaicism. These women usually present secondary amenorrhea, with progressive degradation of functional ovarian tissue.¹

Hewitt et al.⁷ indicated that the ovaries of women with Turner syndrome could produce the oocyte only if they contain germ cells with the 46,XX chromosomal formula, and this situation is likely even if the blood karyotype is 45,X. The majority of women with Turner syndrome present a somatic mosaicism with the absence of the second gonosome in their blood cell line. Spontaneous conception among patients with Turner syndrome is extremely rare; such cases have been reported mainly in mosaics because mosaic Turner syndrome is associated with infertility, secondary amenorrhea, and recurrent abortions.⁸ About 30% of these pregnancies

have a normal outcome, while the rest become complicated by chromosomal abnormalities such as the recurrence of X chromosome defect in female offspring, trisomy 21, stillbirths, fetal malformations, and recurrent abortions.⁹ This information supports the case of our patient, who had 2 natural pregnancies and gave birth to 2 children with Down syndrome. One of the reasons why some women with Turner syndrome can have natural births is the genetic factor, genes or alleles on the autosomal genes, which can compensate for the deletion of a sex chromosome. There are also a few reports that there is a difference in egg cells and the peripheral blood karyotype.¹⁰ However, 80% of women with Turner syndrome do not have ovarian functions and menstrual cycles and thus need hormonal therapy. It is also possible to donate egg cells in order to help women with Turner syndrome to conceive.¹¹ It is, therefore, necessary that patients with Turner syndrome receive prenatal diagnosis and benefit from all the advantages of artificial fertilization techniques.

The pregnancy rate after receiving donated ovarian cells in women with Turner syndrome is high, but there is a risk of cardiovascular problems during pregnancy as well as low birth weight and other complications. Accordingly, meticulous assessment is required before and during pregnancy so as to reduce complications in this high-risk group of women with Turner syndrome. Further, given the problems with which women with Turner syndrome are faced vis-à-vis fertility and pregnancy, it is advisable that they receive genetic counseling at an earlier stage of their life.

Conclusion

Because of her history of 2 natural pregnancies resulting in 2 children with Down syndrome, our patient has decided to undergo preimplantation genetic diagnosis (PGD) in future. For this patient, as well as for other women with Turner syndrome, the necessary routine is cytogenetic analysis (together with genetic counseling). The same analysis can be helpful in implementing assisted reproductive techniques.

Conflict of Interest: None declared.

References

1. Gorduza V, Petrariu F. Outcome of spontaneous pregnancy in turner syndrome. *Acta Endocrinologica*. 2015;11:348-55.
2. Weijerman ME, de Winter JP. Clinical practice. The care of children with Down

- syndrome. *Eur J Pediatr*. 2010;169:1445-52. doi: 10.1007/s00431-010-1253-0. PubMed PMID: 20632187; PubMed Central PMCID: PMCPMC2962780.
3. Ryu SW, Lee G, Baik CS, Shim SH, Kim JT, Lee JS, et al. Down-Turner syndrome (45,X/47,XY,+21): case report and review. *Korean J Lab Med*. 2010;30:195-200. doi: 10.3343/kjlm.2010.30.2.195. PubMed PMID: 20445340.
 4. Manassero-Morales G, Alvarez-Manassero D, Merino-Luna A. Down-Turner Syndrome: A Case with Double Monoclonal Chromosomal Abnormality. *Case Rep Pediatr*. 2016;2016:8760504. doi: 10.1155/2016/8760504. PubMed PMID: 27672470; PubMed Central PMCID: PMCPMC5031876.
 5. Shaffer LG, McGowan-Jordan J, Schmid M. *ISCN 2013: An International System for Human Cytogenetic Nomenclature*. Basel: Karger; 2013.
 6. Hagman A, Kallen K, Bryman I, Landin-Wilhelmsen K, Barrenas ML, Wennerholm UB. Morbidity and mortality after childbirth in women with Turner karyotype. *Hum Reprod*. 2013;28:1961-73. doi: 10.1093/humrep/det113. PubMed PMID: 23578947.
 7. Hewitt JK, Jayasinghe Y, Amor DJ, Gillam LH, Warne GL, Grover S, et al. Fertility in Turner syndrome. *Clin Endocrinol (Oxf)*. 2013;79:606-14. doi: 10.1111/cen.12288. PubMed PMID: 23844676.
 8. Kammoun I, Chaabouni M, Trabelsi M, Ouertani I, Kraoua L, Chelly I, et al. [Genetic analysis of Turner syndrome: 89 cases in Tunisia]. *Ann Endocrinol (Paris)*. 2008;69:440-5. doi: 10.1016/j.ando.2008.01.007. PubMed PMID: 18541220.
 9. Rizk DE, Deb P. A spontaneous and uneventful pregnancy in a Turner mosaic with previous recurrent miscarriages. *J Pediatr Adolesc Gynecol*. 2003;16:87-8. PubMed PMID: 12742142.
 10. Hreinsson JG, Ojala M, Fridstrom M, Borgstrom B, Rasmussen C, Lundqvist M, et al. Follicles are found in the ovaries of adolescent girls with Turner's syndrome. *J Clin Endocrinol Metab*. 2002;87:3618-23. doi: 10.1210/jcem.87.8.8753. PubMed PMID: 12161485.
 11. Conway GS. Disorders of sex development (DSD): an overview of recent scientific advances. *Psychology & Sexuality*. 2014;5:28-33. doi:10.1080/19419899.2013.831213.