

Ascaridial Volvulus: An Uncommon Cause of Ileal Perforation

C Danny Darlington¹, MBBS, MS;
G Fatima Shirly Anitha², MBBS, MD

¹Department of Surgery, Jawaharlal Institute of Postgraduate Medical Education & Research, Puducherry, India;

²Department of Pediatrics, CSI Kalyani Multispeciality Hospital, Mylapore, Chennai, India

Corresponding Author:

C Danny Darlington, MBBS, MS;
No 49, G3 Ananti Apartment,
Santhome High Road,
Santhome Chennai -4, Tamil Nadu, India
Tel: +91 770 8313920

Email: dannycarbin2@gmail.com

Received: 6 May 2017

Revised: 14 June 2017

Accepted: 2 July 2017

Abstract

Ascariasis is a common worm infestation in developing and under-developed countries. It is caused by the ingestion of food contaminated with *Ascaris* eggs from faeces and is more common in places with poor sanitation. Almost 25% of the world population is infested by *Ascaris lumbricoides*. Although ascariasis is a chronic disease, it can present as acute abdomen rarely. The wandering nature of *Ascaris* in and out of the bowel causes various abdominal complications such as intestinal obstruction, perforation, biliary ascariasis, pancreatic ascariasis, liver abscess, appendicitis, and Meckel's diverticulitis. Intestinal obstruction is the most common complication seen in children and is usually due to mechanical bowel obstruction, volvulus or intussusception. Mechanical obstruction by a bolus of worms is the most common cause of bowel obstruction. Perforation of bowel is rarely reported and it usually occurs in the diseased segment of bowel or following trauma. Perforation of an ileal volvulus secondary to ascariasis has been reported rarely. We present a 4-year-old boy who presented to the emergency room with features of bowel perforation and sepsis, after unsuccessful management for intestinal obstruction in another hospital. On laparotomy, the small bowel was teeming with *Ascaris* worms. Ileum showed a volvulus with closed loop obstruction and perforation. Peritoneal lavage with resection and ileostomy was done, which was closed at a later date. Anti-helminthic agents were started postoperatively and the boy recovered uneventfully.

Please cite this article as: Darlington CD, Anitha GFS. Ascaridial Volvulus: An Uncommon Cause of Ileal Perforation. *Iran J Med Sci*. 2018;43(4):432-435.

Keywords • Ascariasis • Ileum • Intestinal perforation • Intestinal volvulus

What's Known

- Ascariasis causes bowel obstruction, but rarely perforates because the worms lack teeth. Perforation usually occurs in predisposed bowel as in typhoid fever or following trauma. It is rare without these factors.

What's New

- The present report describes a rare case of a patient that did not have any trauma or typhoid, but had ileal volvulus with perforation.

Introduction

Ascariasis is the most common helminthic infestation in the world, affecting one fourth of the world population.¹ It is more common among pre-school children of lower socioeconomic status and is caused by the nematode *Ascaris lumbricoides*. Poor hygiene and warm climate favour the faeco-oral transmission of *Ascaris lumbricoides*. Ascariasis is endemic in India.¹ Ascariasis presents with chronic symptoms like diarrhoea, abdominal pain and anaemia. Acute presentations are common when the worm load is high. A myriad of complications such as intestinal obstruction, perforation, biliary ascariasis, appendicitis and volvulus are possible in ascariasis due to the wandering nature of *Ascaris* worms.² Intestinal obstruction is the most common acute abdominal complication of ascariasis in developing countries, occurring in 50% to 65% of cases.² Bowel perforation is relatively rare.² Perforation

usually occurs in ileum or jejunum affected by other disease processes such as typhoid.³ Cases of ileal perforations with associated enteric ileitis, trauma, etc., have been reported in the literature.³ Herein, we report a case of ileal perforation with volvulus due to *Ascaris lumbricoides* in a 4-year-old boy without any history of trauma or pre-existing bowel disease.

Case Report

A 4-year-old boy presented to the emergency department with complaints of abdominal distension and pain for five days. He had a history of bilious vomiting with worms in the vomitus for past four days. There was a history of constipation for four days. The boy did not have fever or trauma to the abdomen. He was from a rural area in India, with frequent day to day contact with cattle. His parents were farmers by occupation and were illiterates. He weighed 14 kg and never had a previous history of passing worms in stools. He had a history of pica. There was no history of loss of appetite until recently for past one week. He was managed conservatively in another hospital for three days and referred to us for further management. On examination, the child was febrile, pulse rate 120 per minute, and blood pressure: 90/60 mm Hg. The abdomen was distended with few visible dilated bowel loops. On palpation, there was guarding and rigidity in the centre of the abdomen; no organomegaly. Bowel sounds were sluggish. Digital rectal examination revealed an empty rectum.

Blood investigations were as follows: Haemoglobin 10 g/dl, total counts 20,000/mm³; differential count: Neutrophils 76%, lymphocytes 16%, eosinophils 10%. Renal function tests were normal, Widal test result was negative and blood culture was reported as "no growth". Chest X-ray erect showed no free air under the diaphragm. Abdominal X-ray revealed dilated gas filled small bowel loops. In view of abdominal signs and hypotension, written informed consent was obtained from the child's parents and the boy underwent emergency laparotomy after adequate resuscitation.

On laparotomy, the entire small bowel was dilated and filled with worms. Distal ileal volvulus (figure 1) was present with a single 1 cm sized perforation in the antimesenteric border of the ileum and a worm was seen protruding out through the perforation (figure 2). The rest of the bowel was healthy. As the ileum containing the bolus of worms was thinned out, an enterotomy was performed to extract the worms. After removing all the worms (figure 3) through the enterotomy, resection of the ileum with ileostomy

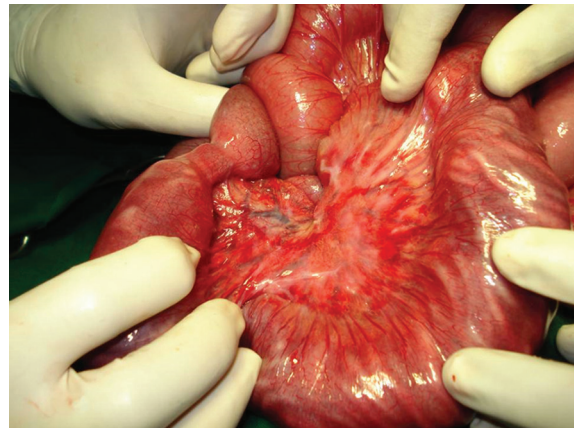


Figure 1: Intraoperative photograph of the ileal volvulus.

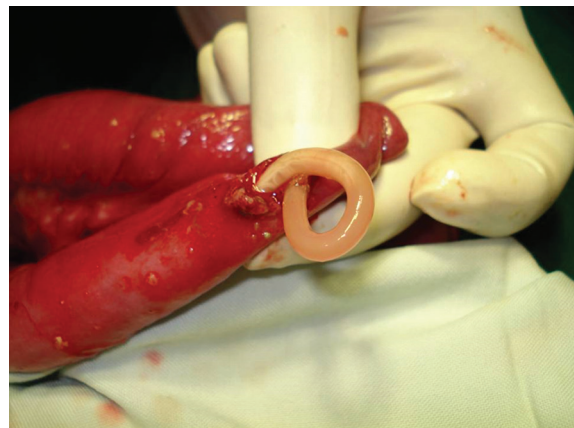


Figure 2: Ascaris protruding out through the perforation.



Figure 3: The extracted Ascaris worms.

was done. Postoperatively, the patient was started on the anti-helminthic drug mebendazole and had an uneventful recovery. Follow-up stool examination revealed no *Ascaris* eggs or worms. The ileostomy was closed at a later date.

Discussion

Paediatric intestinal obstruction can be caused by a variety of etiological factors. Ascariasis must

be suspected in children from endemic regions of the world presenting with acute abdomen. Ascariasis is common in tropical and subtropical areas where unhygienic disposal of human wastes is common. The mode of infection is by ingestion of embryonated eggs in uncooked vegetables or water. The fertilized eggs hatch in the duodenum and larvae penetrate the bowel wall to reach the heart, pulmonary circulation, and alveoli. The larvae are coughed by the host, swallowed back into the intestine, and develop into adult worms. Since adults do not multiply in humans, symptoms depend on the worm load in the intestine.⁴ Infections may be asymptomatic when the worm load is less. In patients with high worm load, it can cause symptoms. Due to the wandering nature of the worms, they can cause penetrate cavities and cause a wide range of complications. Abdominal complications include acute pancreatitis, acute cholecystitis, appendicitis, liver abscess, intestinal obstruction, perforation, massive gastrointestinal bleeding, and gangrene of the bowel. They may even migrate into the common bile duct and cause obstructive jaundice.² Intestinal obstruction is the most common complication occurring in 50% to 65% of cases in Indian studies. In a study involving 207 cases of paediatric intestinal obstruction by Baba et al., ascariasis accounted for 63% of intestinal obstruction in children.⁵ This probably reflects on the high incidence of ascariasis in India. Mortality in intestinal obstruction due to ascariasis is 5.7% in children less than ten years of age.⁶ The incidence of volvulus is reported to be 24-36%.²

Ascaris worm bolus causes intra-luminal mechanical obstruction near ileocecal valve and spasticity of distal ileum by releasing endotoxins and host inflammatory reactions. Intestinal perforation is rare because of distensibility of the bowel and usually occurs in blind-ending structures, such as appendix or Meckel's diverticulum. It can also result from ischemic necrosis secondary to volvulus. *Ascaris* lack teeth and stay in the intestinal lumen.² Coexistent bowel pathologies such as typhoid, amebiasis, intestinal ulcers, and trauma usually provide exit sites for *Ascaris*.⁷ Perforation occurs most commonly in the ileum but rarely even duodenal⁸ and jejunal perforations have been reported. Perforation can also occur rarely secondary to volvulus and not the worms per se. The present case is peculiar in that there was no predisposing diseased bowel (enteritis, typhoid, trauma) and the heavy worm load caused local ileal volvulus and perforation. A study done in India by Ramareddy et al. reported four cases of

intestinal perforation in ascariasis, of which two were primary ascaridial perforations without any co-existing bowel pathology. The same study also reported five children presenting with ileal volvulus. All the five with ileal volvulus underwent resection of the ileum with the extraction of the worms, followed by anastomosis.² In the present case, ileostomy was done considering the poor general condition of the child and the disparity in size of the bowel lumen.

Although plain X-ray of the abdomen may show radiolucent areas, cigar bundle appearance² or pneumoperitoneum in a case of perforation, and multiple air fluid levels in case of heavy worm infestation, these were absent in our case. Hence, a high index of suspicion is needed in diagnosing and planning for surgery, especially in paediatric patients. Ultrasonography can visualize the worms inside the bowel lumen. On ultrasonography, each worm appears to have two pairs of parallel lines representing the worms outer margin and digestive tract.⁹

Conservative management of ascaridial intestinal obstruction using nasogastric decompression, hypertonic saline enema, and supportive measures can be tried in the absence of abdominal guarding or rigidity.¹⁰ In a 5-year study by Mishra et al., 103 children with ascaridial intestinal obstruction were managed conservatively with hypertonic saline enema and intravenous fluid resuscitation. The aim of this treatment was to starve the worm and hydrate the patient. In total, 85% of the children in the study were relieved of obstruction by conservative treatment alone. Only the remaining 15% who developed abdominal guarding and rigidity underwent surgical intervention. Thus, immediate surgical treatment in ascariasis is indicated in the presence of peritonitis and persistent intestinal obstruction. Surgical options include milking or enterotomy to remove the worms or resection and anastomosis of the bowel.¹¹ In an Indian study by Baba et al., 131 children with intestinal obstruction due to ascariasis were included. Nearly two-third of the study population required enterotomy or resection of the bowel. Milking of the worms into the colon was successful in only 14 % of the children.⁵ In the present case, resection of the ileum with ileostomy was done due to the poor general condition of the child. Villamizar et al. have reported one case of ascaridial intestinal obstruction managed by ileostomy. The ileostomy was closed successfully after stabilisation and anti-helminthic drug treatment with minimal morbidity.¹¹ Complications such as wound infection, burst abdomen, and fecal fistula have been reported in almost 20% of

children with ascariasis who underwent surgical interventions.⁵

Conclusion

This case has been presented for its rarity and to emphasize that bowel perforation can occur in ascariasis even in the absence of pre-existing bowel pathology. Most of the morbidity and mortality in acute presentation of ascariasis is usually seen in children presenting with volvulus and peritonitis. Hence, close monitoring and early surgical intervention in those with toxemia and peritonitis is the rule.

Conflict of Interest: None declared.

References

- Mukhopadhyay M. Biliary ascariasis in the Indian subcontinent: a study of 42 cases. *Saudi J Gastroenterol.* 2009;15:121-4. doi: 10.4103/1319-3767.48970. PubMed PMID: 19568577; PubMed Central PMCID: PMCPMC2702965.
- Ramareddy RS, Alladi A, Siddapa OS, Deepti V, Akthar T, Mamata B. Surgical complications of *Ascaris lumbricoides* in children. *J Indian Assoc Pediatr Surg.* 2012;17:116-9. doi: 10.4103/0971-9261.98130. PubMed PMID: 22869977; PubMed Central PMCID: PMCPMC3409899.
- Ihekwa FN. *Ascaris lumbricoides* and perforation of the ileum: a critical review. *Br J Surg.* 1979;66:132-4. PubMed PMID: 420985.
- Das AK. Hepatic and biliary ascariasis. *J Glob Infect Dis.* 2014;6:65-72. doi: 10.4103/0974-777X.132042. PubMed PMID: 24926166; PubMed Central PMCID: PMCPMC4049042.
- Baba AA, Ahmad SM, Sheikh KA. Intestinal ascariasis: the commonest cause of bowel obstruction in children at a tertiary care center in Kashmir. *Pediatr Surg Int.* 2009;25:1099-102. doi: 10.1007/s00383-009-2486-8. PubMed PMID: 19760197.
- Yetim I, Ozkan OV, Semerci E, Abanoz R. Rare cause of intestinal obstruction, *Ascaris lumbricoides* infestation: two case reports. *Cases J.* 2009;2:7970. doi: 10.4076/1757-1626-2-7970. PubMed PMID: 19830032; PubMed Central PMCID: PMCPMC2740073.
- Ahi KS, Munghate A, Chauhan M, Singh H, Kumar A. *Ascaris* intestinal perforation after trivial trauma. *Int J Case Rep Imag.* 2014;5:165-8.
- Sarmast AH, Parray FQ, Showkat HI, Lone YA, Bhat NA. Duodenal perforation with an unusual presentation: a case report. *Case Rep Infect Dis.* 2011;2011:512607. doi: 10.1155/2011/512607. PubMed PMID: 22567473; PubMed Central PMCID: PMCPMC3336218.
- Chawla A, Patwardhan V, Maheshwari M, Wasnik A. Primary ascaridial perforation of the small intestine: sonographic diagnosis. *J Clin Ultrasound.* 2003;31:211-3. doi: 10.1002/jcu.10152. PubMed PMID: 12692830.
- Mishra PK, Agrawal A, Joshi M, Sanghvi B, Shah H, Parelkar SV. Intestinal obstruction in children due to Ascariasis: a tertiary health centre experience. *Afr J Paediatr Surg.* 2008;5:65-70. doi: 10.4103/0189-6725.44178. PubMed PMID: 19858669.
- Villamizar E, Mendez M, Bonilla E, Varon H, de Onatra S. *Ascaris lumbricoides* infestation as a cause of intestinal obstruction in children: experience with 87 cases. *J Pediatr Surg.* 1996;31:201-4. PubMed PMID: 8632280.