

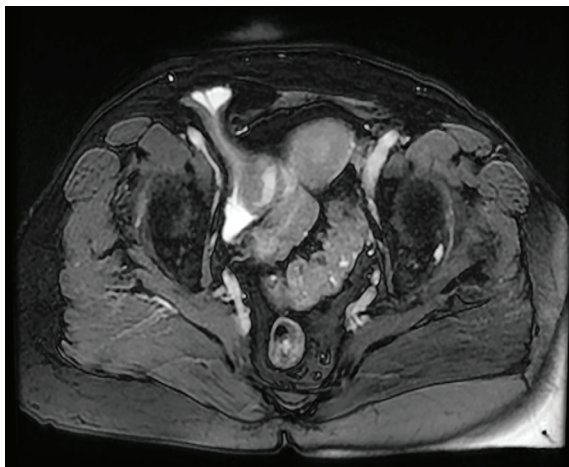
## Inguinal Bladder Hernia in Female Patient

The inguinal hernia affects 3-8% of the general population; and 80-83% of all hernias are located in the inguinal area.<sup>1</sup> Approximately, 75-85% of the patients are men. The herniation of the bladder into the inguinal canal is very rare and the incidence is 1-3% among men over the age of fifty. Inguinal bladder herniation was first described by Lavigne in 1951.<sup>2</sup> There are three forms of bladder herniation including para-peritoneal, intraperitoneal, and extraperitoneal.<sup>3</sup> Most of the patients are asymptomatic and diagnosed incidentally. The clinical presentations of the patients are dysuria, hematuria, urinary obstruction symptoms, and inguinal swelling. Imaging modalities are intravenous urography, cystography, ultrasonography, computed tomography, and magnetic resonance. Cystography is the gold standard method for the diagnosis.<sup>3</sup>

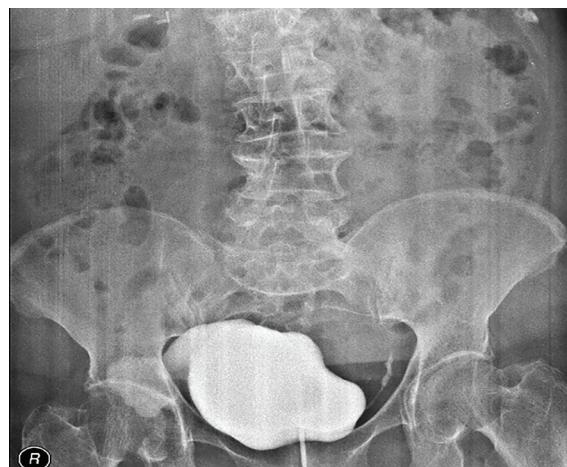
A 72-year-old woman presented to Hitit University, Çorum Training and Research Hospital, Department of Urology, with micturition difficulty for one year. The medical history of the patient was unremarkable and laboratory results were within normal ranges. Body mass index of the patient was 24 kg/m<sup>2</sup>. The urinary ultrasonography revealed a cystic lesion in the right inguinal area suggesting bladder hernia. The magnetic resonance imaging confirmed the lesion as bladder herniation (figure 1). The patient was consulted with a general surgeon and diagnosed with inguinal bladder hernia. Cystography confirmed the diagnosis (figure 2). The patient was referred to the surgery; direct intraperitoneal bladder hernia was detected and the open inguinal hernia operation was performed using prolene mesh. The patient's consent form was signed by the patient.

The inguinal bladder herniation is rarely seen in female patients. The inguinal bladder herniation should be considered when the female patients are presented with micturition difficulty. The inguinal bladder herniation is one of the causes of micturition difficulty in elderly patients.

**Conflict of Interest:** None declared.



**Figure 1:** Magnetic resonance imaging showed the cystic lesion in the right inguinal area.



**Figure 2:** The cystography revealed the bladder herniation.

Please cite this article as: Çalışkan S, Türkmen M, Sungur M. Inguinal Bladder Hernia in Female Patient. Iran J Med Sci. 2018;43(6):671-672.

Selahattin Çalışkan<sup>1</sup>, MD; Musa Türkmen<sup>2</sup>, MD; Mustafa Sungur<sup>3</sup>, MD

<sup>1</sup>Department of Urology, Kanuni Sultan Süleyman Training and Research Hospital, Health Sciences University, İstanbul, Turkey;

<sup>2</sup>Department of Surgery, Çorum Training and Research Hospital, Hitit University, Çorum, Turkey;

<sup>3</sup>Department of Urology, Çorum Training and Research Hospital, Hitit University, Çorum, Turkey

### Correspondence:

Selahattin Çalışkan, MD;

Atakent Mahallesi, 1. Sk. No:46, PC:34303 Küçükçekmece/İstanbul, Turkey

Tel: +90 55 47846552

Email: dr.selahattin@gmail.com

Received: 19 February 2018

Revised: 19 March 2018

Accepted: 15 April 2018

## References

- 1 Ersoz F, Culcu S, Duzkoylu Y, Bektas H, Sari S, Arikan S, et al. The Comparison of Lichtenstein Procedure with and without Mesh-Fixation for Inguinal Hernia Repair. *Surg Res Pract*. 2016;2016:8041515. doi: 10.1155/2016/8041515. PubMed PMID: 27200411; PubMed Central PMCID: PMC4856896.
- 2 Levine B. Scrotal cystocele. *J Am Med Assoc*. 1951;147:1439-41. PubMed PMID: 14873708.
- 3 Bacigalupo LE, Bertolotto M, Barbiera F, Pavlica P, Lagalla R, Mucelli RS, et al. Imaging of urinary bladder hernias. *AJR Am J Roentgenol*. 2005;184:546-51. doi: 10.2214/ajr.184.2.01840546. PubMed PMID: 15671377.