



Antimalarial Drugs-Induced Hepatic Injury in Rats and the Protective Role of Carnosine

Akram Jamshidzadeh^{1,2}, Reza Heidari^{1*}, Farzaneh Abazari², Maral Ramezani², Forouzan Khodaei², Mohammad Mehdi Ommati³, Maryam Ayarzadeh², Roya Firuzi², Arastoo Saedi², Negar Azarpira⁴, Asma Najibi²

¹Pharmaceutical Sciences Research Center, Shiraz University of Medical Sciences, Shiraz, Iran.

²Department of Pharmacology and Toxicology, Shiraz University of Medical Sciences, Shiraz, Iran.

³Department of Animal Science, School of Agriculture, Shiraz University, Shiraz, Iran.

⁴Transplant Research Center, Shiraz University of Medical Sciences, Shiraz, Iran.

Article Info

Article History:

Received: 18 January 2016

Accepted: 7 June 2016

ePublished: 30 September 2016

Keywords:

- Antimalarial agents
- Drug-induced liver injury
- Hepatoprotection
- Malaria
- Peptide

ABSTRACT

Background: Chloroquine and amodiaquine are used in the prophylaxis and treatment of malaria. However, hepatic injury is associated with malaria drug therapy. On the other hand, there is no promising hepatoprotective agent for prophylaxis or treatment of antimalarial drugs-induced liver injury. Carnosine is a naturally occurring peptide with pleiotropic protective properties in different tissues. This investigation aimed to evaluate the effect of carnosine administration in antimalarial drugs-induced hepatic injury in rats.

Methods: Animals were treated with amodiaquine (180 mg/kg, oral) or chloroquine (970 mg/kg, oral). Carnosine (250, 500 and 1000 mg/kg, i.p) was administered as the hepatoprotective agent against antimalarial drugs liver injury.

Results: Liver injury was manifested biochemically by a significant increase in serum level of ALT, LDH, and AST. In addition, hepatic tissue from antimalarial drugs-treated rats showed a significant increase in reactive oxygen species (ROS), lipid peroxidation and protein carbonylation along with a decrease in hepatic glutathione reservoirs and total antioxidant capacity. Moreover, the liver histopathologic evaluation revealed significant congestion, inflammation, and necrosis in amodiaquine and/or chloroquine-treated animals. Carnosine administration significantly alleviated antimalarial drugs-induced pathologic changes in serum biochemistry and liver tissue.

Conclusion: Our data suggest that carnosine possesses protective properties against amodiaquine and/or chloroquine-induced liver injury possibly through mitigation of drug-induced oxidative stress and its consequent events.

Introduction

Drug-induced liver injury (DILI) is a serious adverse drug reaction associated with many pharmaceuticals. Drugs are able to affect liver function which in some cases it leads to liver failure and even patients death.¹ Hepatic injury is a serious adverse effect associated with malaria drug therapy.^{2,3}

Chloroquine is an antimalarial agent used in the treatment and prophylaxis of this disease.⁴ This drug is also used in the management of lupus erythematosus and rheumatoid arthritis.^{5,6} Chloroquine is also one of the most effective disease-modifying antirheumatic drugs (DMARDs).⁵ On the other hand, chloroquine

administration is associated with liver injury in humans. Several cases of chloroquine-induced liver injury are reported.^{2,3,7-9} Although the precise mechanism(s) of chloroquine-induced hepatotoxicity is not clear, some investigations indicated the role of reactive metabolites and oxidative stress in chloroquine hepatotoxicity.¹⁰⁻¹³ Amodiaquine is another antimalarial drug used in the prophylaxis and treatment of malaria especially against chloroquine-resistant isolates of *Plasmodium falciparum*.^{4,14} However, the clinical use of this drug is associated with hepatotoxicity.^{2,15,16} The exact mechanism of amodiaquine-induced hepatotoxicity is not clear yet, but this adverse effect might be attributed to

*Corresponding Author: Reza Heidari, E-mail: rezaheidari@hotmail.com

©2016 The Authors. This is an open access article and applies the Creative Commons Attribution (CC BY), which permits unrestricted use, distribution, and reproduction in any medium, as long as the original authors and source are cited. No permission is required from the authors or the publishers.

the bioactivation of the drug to a quinone imine metabolite.¹⁷ Oxidative stress has been suggested to be involved in the development of amodiaquine-induced hepatotoxicity due to the ability of redox cycling induction by the quinone imine metabolite of amodiaquine.^{18,19} Hence, antioxidant molecules seems to have protective properties against antimalarial drugs-induced liver injury.

Carnosine (beta-alanyl-L-histidine) is a naturally occurring dipeptide, distributed in several animal tissues.²⁰ Carnosine is a safe molecule with pleiotropic protective properties in different organs.^{21,22} The protective properties of carnosine are widely investigated in different diseases as well as in xenobiotics-induced liver injury.^{21,23-27} Several investigations indicated that carnosine serves as an antioxidant with marked free radical scavenging capacity.^{28,29} Carnosine is also a good carbonyl trap and protects intracellular proteins and organelles against toxic insults.³⁰⁻³²

The current investigation was designed to examine the potential protective properties of carnosine on the liver of amodiaquine and/or chloroquine-treated rats.

Experimental

Chemicals

Carnosine was obtained from Acros (New Jersey, USA). Trichloroacetic acid (TCA), Thiobarbituric acid (TBA), Ethylenediaminetetraacetic acid (EDTA), orthophosphoric acid (OPA), Ferric chloride hexahydrate, 2-Amino-2-hydroxymethylpropane-1, 3-diol (Tris), and Sucrose were obtained from Merck (Darmstadt, Germany). Hydroxychloroquine, 2,4,6-tri-(2-pyridil)-s-triazine (TPTZ), Dithiothreitol (DTT), and amodiaquine were purchased from Sigma (St.Louis, USA). Kits for evaluating biomarkers of liver injury were obtained from Pars Azmun® (Tehran, Iran). All salts used for preparing buffer solutions were of reagent grade and obtained from Merck (Darmstadt, Germany).

Animals

Male Sprague-Dawley rats (200-300 g, n=72), were obtained from the animal breeding center of Comparative and Experimental Medicine of Shiraz University of Medical Sciences (Shiraz, Iran). Animals were housed in cages on wood bedding at a temperature of 23±2 °C. Rats had free access to food and water. The animals received humane care and use and were handled according to the animal handling protocol approved by a local ethics committee at Shiraz University of Medical Sciences.

Study procedures

Animals were randomly divided in 12 groups

(n=6). The treatments were as follow: **A)** Control (vehicle-treated); **B)** Carnosine (1000 mg/kg, i.p); **D)** Amodiaquine (180 mg/kg, oral); **E)** Amodiaquine (180 mg/kg, oral) + Carnosine (250 mg/kg, i.p), **F)** Amodiaquine (180 mg/kg, oral) + Carnosine (500 mg/kg, i.p), **G)** Amodiaquine (180 mg/kg, oral) + Carnosine (1000 mg/kg, i.p), **H)** Chloroquine (970 mg/kg, oral), **I)** Chloroquine (970 mg/kg, oral) + Carnosine (250 mg/kg, i.p), **J)** Chloroquine (970 mg/kg, oral) + Carnosine (500 mg/kg, i.p), **K)** Chloroquine (970 mg/kg, oral) + Carnosine (1000 mg/kg, i.p), **L)** One week pre-treatment with carnosine (1000 mg/kg, i.p) + Amodiaquine (180 mg/kg, oral), **M)** One week pre-treatment with carnosine (1000 mg/kg, i.p) + Chloroquine (970 mg/kg, oral), **N)** Carnosine (1000 mg/kg, i.p). Carnosine was administered 2 hours after antimalarial drugs. Biomarkers of liver injury were monitored 24 hours after antimalarial drugs administration.

Serum biochemistry

Rats were anesthetized (pentobarbital, 50 mg/kg) and blood samples were collected from abdominal *vena cava*. Serum was prepared by centrifugation (3000 g, 10 minutes, 4°C). A Mindray BS-200® auto analyzer and standard kits were used to measure alanine aminotransferase (ALT), aspartate aminotransferase (AST), lactate dehydrogenase (LDH), alkaline phosphatase (ALP), bilirubin, and protein in animals' serum.

Liver lipid peroxidation

The thiobarbituric acid reactive substances (TBARS) were assessed in liver tissue as an index of lipid peroxidation.³³ Briefly, the reaction mixture consisted of thiobarbituric acid (0.375%, w/v), phosphoric acid (1% w/v, pH=2), and 500 µM of tissue homogenate (10% w/v in KCl, 1.15% w/v). The mixture was incubated at 100 °C for 45 minutes. After the incubation period, 2 mL of n-butanol was added and vigorously mixed. Finally, Samples were centrifuged (3000 g for 5 minutes) and the absorbance of developed pink color in the n-butanol phase was measured at 532 nm using an Ultrospec 2000®UV spectrophotometer (Pharmacia Biotech, Uppsala, Sweden).³⁴

Hepatic glutathione (GSH) content

Liver GSH levels were assessed with the Ellman reagent (DTNB).³⁵ Briefly, samples of the liver (200 mg) were homogenized in 8 mL of ice-cooled EDTA solution (20 mM). Then, 5 mL of liver homogenate was mixed with 4 mL of cooled distilled water and 1 mL of trichloroacetic acid (50%, w/v). The mixture was vortexed and then centrifuged (765 g, 15 minutes, 4°C). Afterward, 2 mL of supernatant was added to 4 mL of Tris buffer (pH= 8.9) and 100 µl of DTNB solution

(0.01 M in methanol).^{31,36} The absorbance of developed yellow color was read at 412 nm using an Ultrospec 2000[®]UV spectrophotometer (Pharmacia Biotech, Uppsala, Sweden).

Protein carbonylation in liver tissue

Total protein-bound carbonyl content was measured by a spectrophotometric assay after derivatizing the protein carbonyl adducts with 2,4-dinitrophenyl hydrazine (DNPH).³⁷ Briefly, 500 mg of liver tissue was homogenized in a Phosphate buffer (pH=7.4) containing 0.1% Triton-X100. An aliquot of the liver homogenate (0.5 mL) was added to an equivalent volume (0.5 mL) of 0.1% DNPH (w/v in 2.0 N HCl) and incubated for 1 hour at room temperature in the dark. This reaction was terminated and total cellular protein precipitated by the addition of an equivalent volume of TCA (20%, w/v). Cellular protein was rapidly pelleted by centrifugation at 10,000 g, and the supernatant was discarded. Excess unincorporated DNPH was extracted three times using an excess volume (0.5 mL) of ethanol: ethyl acetate (1:1 v/v) solution. Following the extraction procedure, the recovered pellet was dissolved in 1 mL of Tris-HCl buffer (Containing 8.0 M guanidine-HCl, pH 7.2). The resulting solubilized hydrazones were measured at 380 nm by an Ultrospec2000[®] spectrophotometer (Pharmacia Biotech, Uppsala, Sweden).^{38,39}

Reactive oxygen species (ROS) formation in liver

Reactive oxygen species in liver was assessed using 2', 7'-dichlorofluorescein diacetate (DCF) as a ROS probe.⁴⁰ Liver tissues was homogenized in ice-cold Tris-HCl buffer (40 mM, pH=7.4) (1:10 w/v). Samples of the resulted tissue homogenate (100 µL) were mixed with Tris-HCl buffer (1 mL) and 5 µL of DCF (Final concentration of 10 µM). The mixture was incubated for 30 minutes in 37°C in dark. Finally, the fluorescence intensity of the samples were assessed using a FLUOstar Omega[®] multifunction microplate reader (BMG LABTECH) ($\lambda_{\text{excitation}}=485 \text{ nm}$ and $\lambda_{\text{emission}}=525 \text{ nm}$).^{40,41}

Ferric reducing antioxidant power (FRAP) of liver tissue

FRAP assay measures the formation of a blue colored Fe²⁺-tripirydyltriazine complex from the colourless oxidized Fe³⁺ form by the action of electron-donating antioxidants.⁴² Briefly, the working FRAP reagent was prepared by mixing 10 volumes of 300 mmol/L acetate buffer (pH 3.6) with 1 volume of 10 mmol/L TPTZ (2,4,6-tripirydyl-s-triazine) in 40 mmol/L hydrochloric acid and with 1 volume of 20 mmol/L ferric chloride. All solutions were used on the day of

preparation. Liver tissue was homogenized in cooled-Tris buffer (0.25M, containing 0.2M sucrose and 5mM DTT, pH 7.4). Then, 50µL of tissue homogenate and 150µL of deionized water was added to 1.5 mL of the FRAP reagent. The reaction mixture was incubated at 37°C for 5 minutes. Finally, the absorbance of developed blue color was measured at 593 nm by an Ultrospec2000[®] spectrophotometer (Pharmacia Biotech, Uppsala, Sweden).⁴²

Liver histopathology

For tissue histopathological evaluation, samples of liver were fixed in buffered formalin solution (0.4% sodium phosphate monobasic, NaH₂PO₄, 0.64% sodium phosphate dibasic, Na₂HPO₄, and 10% formaldehyde in distilled water).⁴³ Paraffin-embedded sections of liver were prepared and stained with haematoxylin and eosin (H&E) before viewing by an Olympus CX21[®] light microscope (Tokyo, Japan).

Statistical analysis

Results are shown as Mean±SEM (n=6). Comparisons between multiple groups were made by a one-way analysis of variance (ANOVA) followed by Tukey's *post hoc* test. Differences were considered significant when P<0.05.

Results

Antimalarial drugs caused liver injury in rats as judged by changes in animals serum biochemistry (Figures 1 and 2). It was found that amodiaquine and chloroquine caused an elevation in serum ALT, LDH, and AST (Figure 1). There were no significant changes in serum ALP level when animals received amodiaquine and/or chloroquine (Figure 1). Furthermore, we found no significant changes in serum bilirubin and protein after amodiaquine and/or chloroquine administration to rats (Figure 2). Carnosine (250, 500 and 1000 mg/kg, i.p), significantly mitigated pathological changes of serum biomarkers of liver injury in amodiaquine and/or chloroquine-treated animals (Figure 1). Rats were also pre-treated with carnosine (1000 mg/kg, i.p) for one week. On day 8th, animals were challenged with amodiaquine (180 mg/kg, oral) or chloroquine (970 mg/kg, oral). Serum level of liver injury biomarkers were also significantly lower in carnosine pre-treated animals after antimalarial drug administration (Figure 1). A significant amount of reactive oxygen species (ROS) was detected in the liver of amodiaquine and/or chloroquine-treated rats (Figure 3). Furthermore, the total antioxidant capacity of liver tissue was compromised in drug-treated animals (Figure 3).

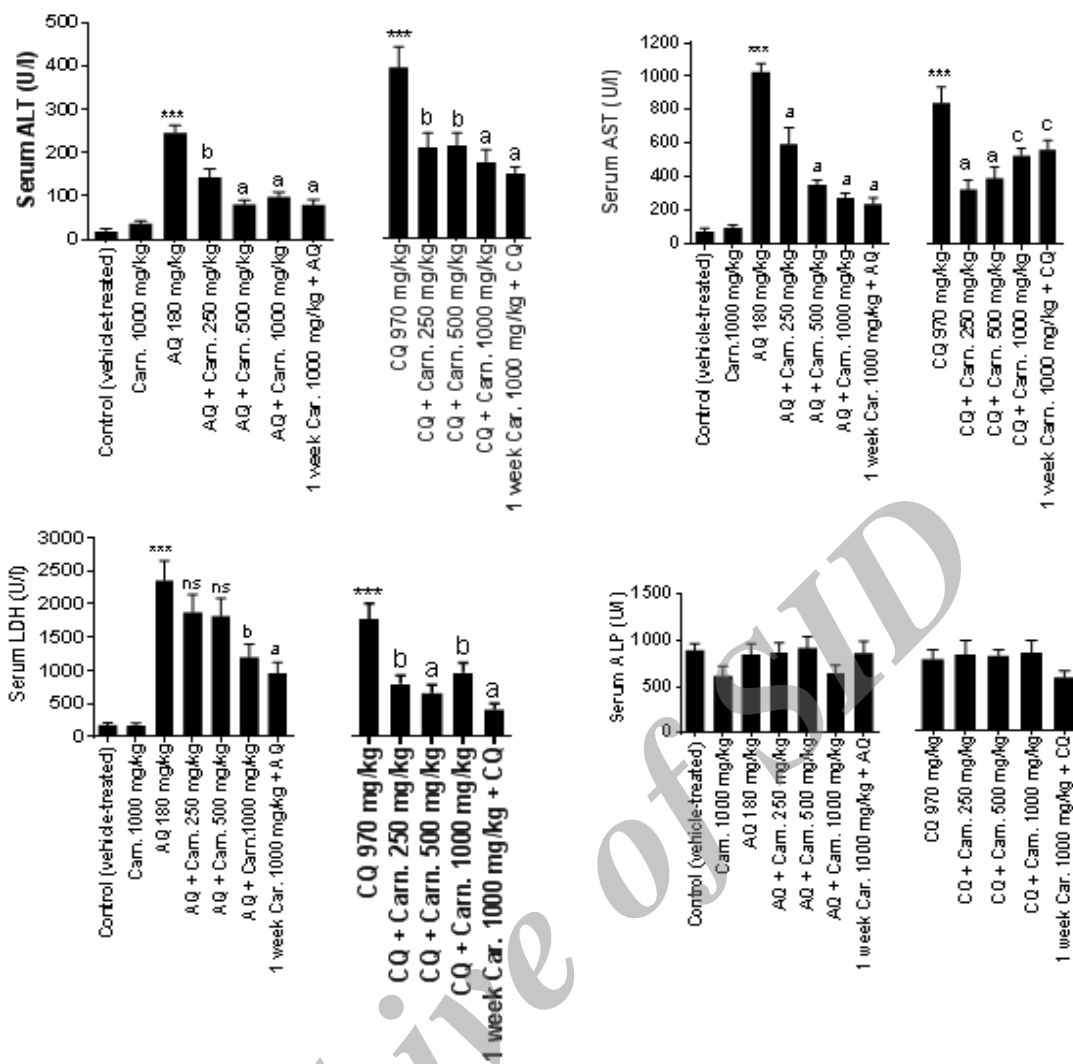


Figure 1. Serum biomarkers of liver injury after antimalarial drugs administration and the role of carnosine therapy. AQ: Amodiaquine, CQ: Chloroquine, Carn: Carnosine. Data are given as Mean±SEM for six animals in each group. *** Indicates significantly different as compared with control animals (P<0.001). ns: not significant as compared to AQ-treated animals. ^a Indicates significantly different as compared with AQ-treated group (P<0.001). ^b Shows significant difference when compared with CQ-treated group (P<0.001). ^c Indicates significant difference as compared with CQ-treated animals (P<0.05).

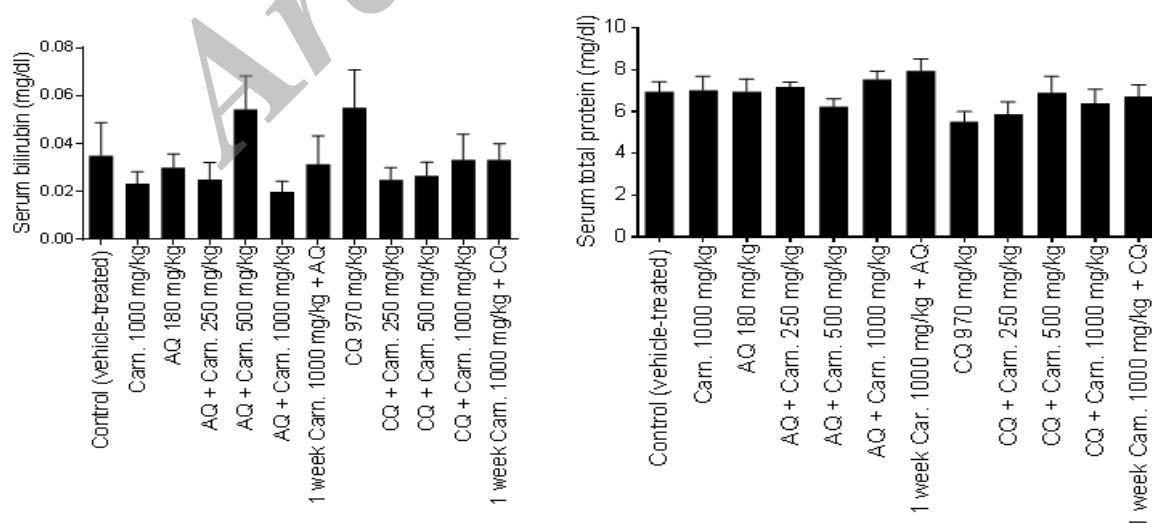


Figure 2. Serum total protein and bilirubin in antimalarial and carnosine-treated groups. AQ: Amodiaquine, CQ: Chloroquine, Carn: Carnosine. Data are given as Mean±SEM for six animals in each group. There were no significant differences between drug-treated and control animals in serum levels of bilirubin and protein.

We found that carnosine (250, 500 and 1000 mg/kg) effectively alleviated ROS formation and antioxidant depletion induced by antimalarial drugs (Figure 3).

Amodiaquine, as well as chloroquine administration, was accompanied by a significant tissue lipid peroxidation, protein carbonylation, and glutathione reservoirs depletion in rat liver (Table 1). It was found that carnosine (250, 500 and 1000 mg/kg, i.p), prevented hepatic glutathione depletion and reduced the level of lipid peroxidation and protein carbonylation in the liver of antimalarial drugs-treated rats (Table 1).

Liver histopathological evaluation revealed a significant tissue necrosis, in addition to sinusoidal congestion and tissue inflammation in drug-treated groups (Figure 4). Carnosine (250, 500 and 1000 mg/kg, i.p) significantly alleviated liver histopathological changes induced by chloroquine and/or amodiaquine (Figure 4).

Discussion

Antimalarial drugs administration is accompanied with liver injury.^{2,3} There is no promising hepatoprotective agent against the liver injury induced by these drugs.

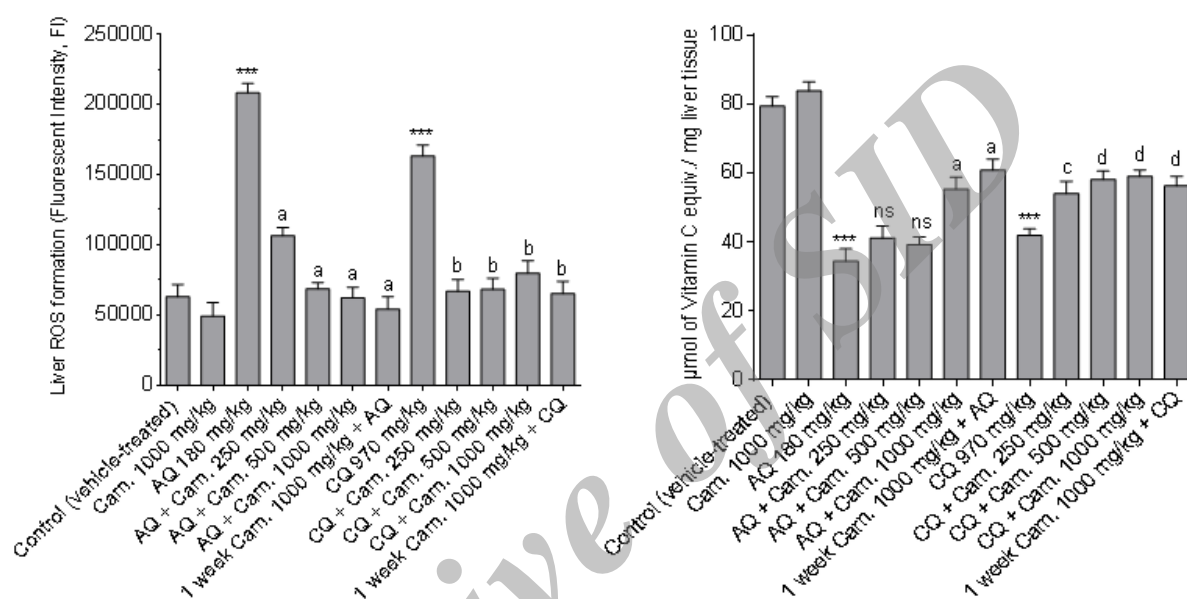


Figure 3. Reactive oxygen species (ROS) formation and total antioxidant capacity (FRAP assay) of the liver after antimalarial drugs administration. AQ: Amodiaquine, CQ: Chloroquine, Carn: Carnosine. Data are given as Mean±SEM (n=6). *** Indicates significantly different as compared with control animals (P < 0.001). ns: not significant as compared to AQ-treated animals. ^a Indicates significantly different as compared with AQ-treated group (P < 0.001). ^b Shows significant difference when compared with CQ-treated group (P < 0.001). ^c Indicates significant difference as compared with CQ-treated rats (P < 0.05). ^d Indicates significantly different from CQ-treated animals (P < 0.01).

Table 1. Liver tissue glutathione content, lipid peroxidation and protein carbonylation in antimalarial drugs-treated animals.

Treatment	Liver GSH ($\mu\text{mol}/\text{mg}$ wet tissue)	Lipid peroxidation (nmol of TBARS/mg wet tissue)	Protein carbonylation (OD at 370 nm)
Control	56.57±2.50	1.87±0.18	0.15±0.02
Carnosine 1000 mg/kg	54.53±2.33	1.68±0.20	0.13±0.01
AQ 180 mg/kg	12.03±1.57***	7.22±0.53***	0.32±0.05***
AQ + Carn. 250 mg/kg	10.45±0.81	4.27±0.23 ^a	0.22±0.02 ^a
AQ + Carn. 500 mg/kg	13.65±0.66	2.10±0.25 ^a	0.18±0.02 ^a
AQ + Carn. 1000 mg/kg	24.59±1.06 ^a	3.14±0.21 ^a	0.21±0.01 ^a
1 week Carn.+ AQ	33.20±4.68 ^a	2.97±0.20 ^a	0.17±0.01 ^a
CQ 970 mg/kg	18.72±1.45***	7.60±0.60***	0.22±0.08
CQ + Carn. 250 mg/kg	12.84±3.10	4.88±0.58 ^b	0.18±0.06
CQ + Carn. 500 mg/kg	15.59±1.88	3.22±0.29 ^b	0.22±0.05
CQ + Carn. 1000 mg/kg	34.93±2.96 ^b	3.06±0.39 ^b	0.18±0.03
1 week Carn.+ CQ	34.79±2.33 ^b	3.31±0.25 ^b	0.18±0.02

AQ: Amodiaquine, CQ: Chloroquine, Carn: Carnosine. Data are given as Mean±SEM (n=6). *** Indicates significantly different as compared with control animals (P<0.001). ns: not significant as compared to AQ-treated animals. ^a Indicates significantly different as compared with AQ-treated group (P<0.001). ^b Shows significant difference when compared with CQ-treated group (P<0.001).

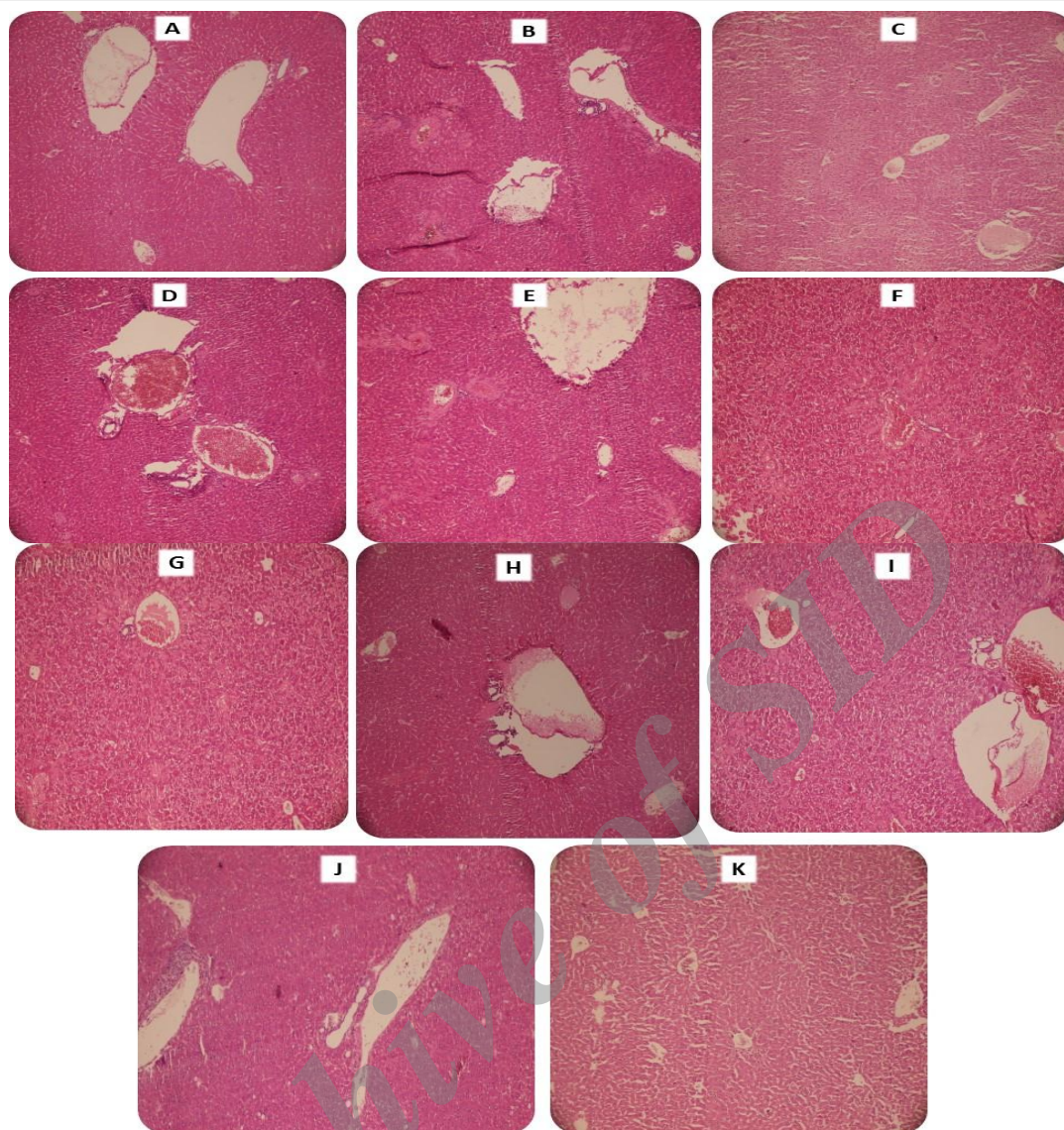


Figure 4. Photomicrographs of liver tissue from antimalarial drugs-treated animals (H&E staining). **A:** Control (Vehicle-treated animals). **B:** Amodiaquine-treated group; animals received amodiaquine (180 mg/kg, oral) and sacrificed 24 hours after drug administration). Liver sinusoidal congestion, in addition to inflammation, was detected in this group. **C:** Chloroquine-treated animals; rats were treated with chloroquine (970 mg/kg, oral) and tissue samples were taken 24 hours after drug administration. Significant tissue necrosis, in addition to sinusoidal congestion, hepatocytes vacuolization and inflammation were detected in this group. **D, E and F:** AQ (180 mg/kg)-treated rats which received carnosine 250, 500 and 1000 mg/kg, i.p; respectively. **G, H, and I:** CQ (970 mg/kg)-treated rats which received carnosine 250, 500 and 1000 mg/kg, i.p; respectively. **J:** One-week pre-treatment with carnosine + AQ (180 mg/kg). **K:** One week pre-treated with carnosine + CQ (970 mg/kg). Carnosine administration significantly alleviated antimalarial drugs hepatic lesions (D-K).

Hence, finding safe hepatoprotective agents against antimalarial hepatotoxicity might have clinical value. The current investigation was designed to evaluate the potential protective properties of carnosine against amodiaquine and chloroquine-induced liver injury.

Although there is no precise mechanism of liver injury for amodiaquine and chloroquine, but several investigations indicated the role of oxidative stress and its consequent events in this complication.^{10-12,44} Oxidative stress is the mechanism of cellular injury induced by many xenobiotics.⁴⁵ Oxidative stress is also previously reported after amodiaquine,⁴⁴ and chloroquine

administration.¹⁰⁻¹² Amodiaquine is converted to a quinone imine metabolite, which is capable of inducing oxidative stress in liver (Figure 5).⁴⁶ Although no such reactive metabolite(s) is reported for chloroquine, but it has been shown that chloroquine administration is associated with oxidative stress in hepatocytes.¹⁰ Chloroquine-induced oxidative stress has been mitigated by inhibiting some cytochrome enzyme isoforms (Figure 6).¹⁰ Hence, antioxidative effects of carnosine,²² might play a major role in its protective properties against antimalarial drugs-induced liver injury.

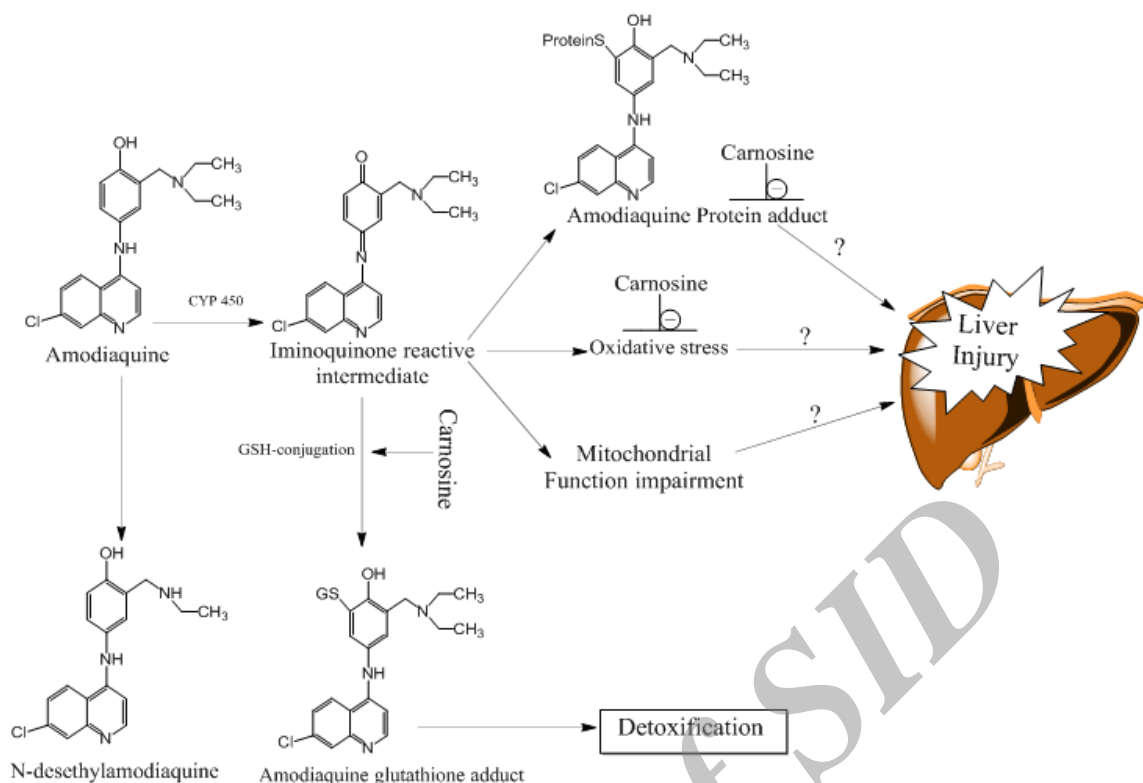


Figure 5. The proposed mechanism(s) of hepatoprotection against amodiaquine-induced liver injury provided by carnosine. The antioxidant properties in addition to carbonyl trapping characteristics of carnosine might be implicated in the protective properties of carnosine against antimalarial drugs-induced hepatotoxicity.

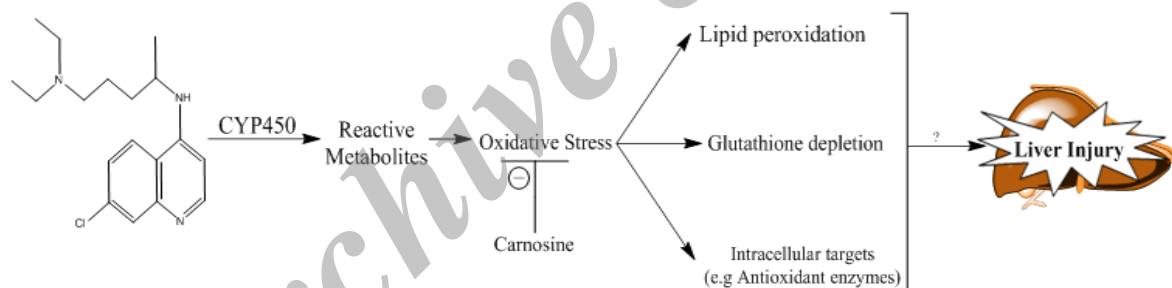


Figure 6. The proposed mechanism(s) of hepatoprotective properties of carnosine against chloroquine-induced liver injury. The antioxidant properties of carnosine might attribute in its hepatoprotective properties against chloroquine-induced liver injury.

Increased ROS level affect some potential targets in cells including membrane lipids and cellular proteins.⁴⁷ Cellular glutathione (GSH) depletion is also a common event after oxidative stress.⁴⁸ Glutathione has an important role in hepatocyte defense against toxicity.⁴⁸ Severe glutathione depletion leaves the liver vulnerable to oxidative damage which causes progressive deterioration of macromolecules and finally organ injury. As mentioned, amodiaquine is metabolized through CYP450 in liver and forms a quinone imine reactive metabolite (Figure 5) which can irreversibly bind to proteins and lead to toxicity by disrupting cell functions (Figure 5). Since reactive intermediates are formed during amodiaquine metabolism, amodiaquine toxicity mechanism could involve protein carbonylation (Figure 5). On

the other hand, lipid peroxidation is a consequence of oxidative stress.⁴⁹ It has been shown that lipid peroxidation occurred after amodiaquine treatment.^{50,51} It has also been found that glutathione reservoirs have a critical role in preventing amodiaquine hepatotoxicity.⁵² Carnosine is a good antioxidant and also prevent cellular proteins injury.^{30,31} Hence, this peptide is able to prevent amodiaquine-induced oxidative stress, glutathione depletion, and protein adducts formation and finally protect liver (Figure 5). Hepatocytes mitochondria also seem to be a target for amodiaquine to induce cytotoxicity (Figure 5).⁴⁴ It has been shown that carnosine effectively protects mitochondria against injury.^{53,54} Although not evaluated in the current investigation, the effect of carnosine on liver mitochondria might also be

involved in its hepatoprotective mechanisms against amodiaquine-induced liver injury (Figure 5).

Chloroquine is metabolized in liver through CYP2C8 and CYP3A4 (Figure 6).⁵⁵ It has been found that chloroquine-induced hepatotoxicity is also associated with oxidative stress in liver (Figure 6).¹¹⁻¹³ In the current study, we found that carnosine effectively alleviated chloroquine-induced oxidative stress, lipid peroxidation, and glutathione reservoirs consumption (Figure 6).

We found that treatment with carnosine protects the liver through attenuation of lipid peroxidation and decreased the production of free radical derivatives, as evident from the decreased levels of liver TBARS (lipid peroxidation) (Figure 3) and ROS formation (Figure 4), and enhancement of the total antioxidant capacity of the liver (Figure 4). As also reported in previous investigations, carnosine offered protection against oxidative stress by scavenging of free radicals.^{56,57} It has also been reported that carnosine boosts cellular antioxidant defense mechanisms and replenish glutathione level.²⁴ Hence, the antioxidant capacity of carnosine along with its ability to protect intracellular targets such as different proteins might be involved in its mechanism of hepatoprotection against antimalarial drugs (Figure 6).

The elevation in serum ALP and bilirubin levels indicates the cholestatic nature of hepatic injury induced by xenobiotics.^{58,59} As serum ALP and bilirubin didn't significantly change in the current investigation, the antimalarial drugs-induced liver injury might be mostly of hepatocellular type rather than cholestatic. Serum total protein is usually decreased in cases of chronic liver injury.⁶⁰ As toxicity markers were assessed 24 hours after antimalarial drugs administration, the short time period of the current investigation might be responsible for the insignificant changes in serum protein level (Figure 2).

Conclusion

In conclusion, our data suggest that carnosine possesses protective properties against amodiaquine and/or chloroquine-induced liver injury possibly through mitigation of drug-induced oxidative stress and its consequent events. A risk assessment study has been shown that carnosine is a safe molecule and cause no significant adverse effects even at very high doses.⁶¹ High doses of carnosine have also been applied in different experiments.^{62,63} We might be able to suggest that carnosine could be administered as a supplementary agent with chloroquine and amodiaquine to reduce their adverse effects toward the liver. Chloroquine is also widely administered as a disease-modifying antirheumatic drug (DMARD) in patients with rheumatoid arthritis.⁵

Hence, carnosine might be beneficial as an adjuvant therapy with chloroquine to reduce the risk of chloroquine-induced adverse effects in these patients.

Clearly, the possible interaction(s) of carnosine with malaria/rheumatoid arthritis drug therapy should be considered and must be evaluated in future investigations. Carnosine might also be considered as a therapeutic option for a range of drugs and other xenobiotics-induced oxidative stress and liver injury.

Acknowledgement

This paper was derived from a Pharm D. Thesis for Mrs Farzaneh Abazari. The current investigation was financially supported by the vice-chancellor for research affairs of Shiraz University of Medical Sciences (Grant number: 93-01-36-7610).

Conflict of interests

The authors claim that there is no conflict of interest.

References

1. Kaplowitz N. Drug-induced liver disorders. *Drug Saf.* 2001;24(7):483-90. doi: 10.2165/00002018-200124070-00001
2. Taylor WRJ, White NJ. Antimalarial drug toxicity. *Drug Saf.* 2004;27(1):25-61. doi: 10.2165/00002018-200427010-00003
3. AlKadi HO. Antimalarial drug toxicity: a review. *Chemotherapy.* 2007;53(6):385-91. doi: 10.1159/000109767
4. Laloo DG, Shingadia D, Pasvol G, Chiodinid PL, Whitty CJ, Beeching NJ, et al. UK malaria treatment guidelines. *J Infect.* 2007;54(2):111-21. doi: 10.1016/j.jinf.2006.12.003
5. Smolen JS, Landewé R, Breedveld FC, Maya B, Burmester G, Dougados M, et al. EULAR recommendations for the management of rheumatoid arthritis with synthetic and biological disease-modifying antirheumatic drugs: 2013 update. *Ann Rheum Dis.* 2014;73:492-509. doi: 10.1136/annrheumdis-2013-204573
6. Rainsford KD, Parke AL, Clifford-Rashotte M, Kean WF. Therapy and pharmacological properties of hydroxychloroquine and chloroquine in treatment of systemic lupus erythematosus, rheumatoid arthritis and related diseases. *Inflammopharmacology.* 2015;23(5):231-69. doi: 10.1007/s10787-015-0239-y
7. Liu AC. Hepatotoxic reaction to chloroquine phosphate in a patient with previously unrecognized porphyria cutanea tarda. *West J Med.* 1995;162(6):548-51.
8. Wielgo-Polanin R, Lagarce L, Gautron E, Diquet B, Lainé-Cessac P. Hepatotoxicity

- associated with the use of a fixed combination of chloroquine and proguanil. *Int J Antimicrob Agents*. 2005;26(2):176-8. doi: 10.1016/j.ijantimicag.2005.04.019
9. Stalke P, Sikorska K, Michalska Z, Stolarczyk J, Trocha H. Hepatotoxicity of chloroquine treatment in patient with porphyria cutanea tarda. *Amr J Case Rep*. 2006;7:18-22.
 10. Jamshidzadeh A, Niknahad H, Kashafi H. Cytotoxicity of chloroquine in isolated rat hepatocytes. *J Appl Toxicol*. 2007;27(4):322-6. doi: 10.1002/jat.1194
 11. Pari L, Murugavel P. Protective effect of α -lipoic acid against chloroquine-induced hepatotoxicity in rats. *J Appl Toxicol*. 2004;24(1):21-6. doi: 10.1002/jat.940
 12. Pari L, Amali DR. Protective role of tetrahydrocurcumin (THC) an active principle of turmeric on chloroquine induced hepatotoxicity in rats. *J Pharm Pharm Sci*. 2005;8(1):115-23.
 13. Kumar Mishra S, Singh P, Rath SK. Protective effect of quercetin on chloroquine-induced oxidative stress and hepatotoxicity in mice. *Malar Res Treat*. 2013;2013:1-10. doi: 10.1155/2013/141734
 14. White NJ. The treatment of malaria. *N Engl J Med*. 1996;335(11):800-6. doi: 10.1056/NEJM199609123351107
 15. Larrey D, Castot A, Pessayre D, Merigot P, Machayekhy JP, Feldmann G, et al. Amodiaquine-induced hepatitis. A report of seven cases. *Ann Intern Med*. 1986;104(6):801-3. doi: 10.7326/0003-4819-104-6-801
 16. Markham LN, Giostra E, Hadengue A, Rossier M, Rebsamen M, Desmeules J. Emergency liver transplantation in amodiaquine-induced fulminant hepatitis. *Am J Trop Med Hyg*. 2007;77(1):14-5.
 17. Jewell H, Maggs JL, Harrison AC, O'Neill PM, Ruscoe JE, Park BK. Role of hepatic metabolism in the bioactivation and detoxication of amodiaquine. *Xenobiotica*. 1995;25(2):199-217. doi: 10.3109/00498259509061845
 18. Park BK, Pirmohamed M, Tingle MD, Madden S, Kitteringham NR. Bioactivation and bioinactivation of drugs and drug metabolites: Relevance to adverse drug reactions. *Toxicol In Vitro*. 1994;8(4):613-21. doi: 10.1016/0887-2333(94)90029-9
 19. Tafazoli S, O'Brien PJ. Amodiaquine-induced oxidative stress in a hepatocyte inflammation model. *Toxicology*. 2009;256(1-2):101-9. doi: 10.1016/j.tox.2008.11.006
 20. Crush KG. Carnosine and related substances in animal tissues. *Comp Biochem Physiol*. 1970;34(1):3-30. doi: 10.1016/0010-406X(70)90049-6
 21. Hipkiss AR. Carnosine, diabetes and Alzheimer's disease. *Expert Rev Neurother*. 2009;9(5):583-5. doi: 10.1586/ern.09.32
 22. Boldyrev AA. Carnosine: new concept for the function of an old molecule. *Biochemistry*. 2012;77(4):313-26. doi: 10.1134/S0006297912040013
 23. Bellia F, Vecchio G, Cuzzocrea S, Calabrese V, Rizzarelli E. Neuroprotective features of carnosine in oxidative driven diseases. *Mol Aspects Med*. 2011;32(4-6):258-66. doi: 10.1016/j.mam.2011.10.009
 24. Yan S-l, Wu S-t, Yin M-c, Chen H-t, Chen H-c. Protective effects from carnosine and histidine on acetaminophen-induced liver injury. *J Food Sci*. 2009;74(8):H259-65. doi: 10.1111/j.1750-3841.2009.01330.x
 25. Fouad AA, El-Rehany MA-A, Maghraby HK. The hepatoprotective effect of carnosine against ischemia/reperfusion liver injury in rats. *Eur J Pharmacol*. 2007;572(1):61-8. doi: 10.1016/j.ejphar.2007.06.010
 26. Fouad AA, Qureshi HA, Yacoubi MT, Al-Melhim WN. Protective role of carnosine in mice with cadmium-induced acute hepatotoxicity. *Food Chem Toxicol*. 2009;47(11):2863-70. doi: 10.1016/j.fct.2009.09.009
 27. Kuloglu N, Sönmez MF. A biochemical and immunohistochemical study of the protective effects of carnosine for carbon tetrachloride induced liver injury in rats. *Biotech Histochem*. 2015;90(8):608-14. doi: 10.3109/10520295.2015.1044565
 28. Fu H, Katsumura Y, Lin M, Muroyaa Y, Hataa K, Fujii K, et al. Free radical scavenging and radioprotective effects of carnosine and anserine. *Radiat Phys Chem*. 2009;78(12):1192-7. doi: 10.1016/j.radphyschem.2009.07.023
 29. Salim-Hanna M, Lissi E, Videla LA. Free radical scavenging activity of carnosine. *Free Radic Res Commun*. 1991;14(4):263-70. doi: 10.3109/10715769109088955
 30. Aldini G, Facino RM, Beretta G, Carini M. Carnosine and related dipeptides as quenchers of reactive carbonyl species: from structural studies to therapeutic perspectives. *BioFactors*. 2005;24(1-4):77-87. doi: 10.1002/biof.5520240109
 31. Heidari R, Niknahad H, Jamshidzadeh A, Azarpira N, Bazyari M, Najibi A. Carbonyl traps as potential protective agents against methimazole-induced liver injury. *J Biochem Mol Toxicol*. 2015;29(4):173-81. doi: 10.1002/jbt.21682
 32. Noori S, Mahboob T. Antioxidant effect of carnosine pretreatment on cisplatin-induced renal oxidative stress in rats. *Indian J Clin*

- Biochem. 2010;25(1):86-91. doi: 10.1007/s12291-010-0018-x
33. Janero DR. Malondialdehyde and thiobarbituric acid-reactivity as diagnostic indices of lipid peroxidation and peroxidative tissue injury. *Free Radic Biol Med.* 1990;9(6):515-40. doi: 10.1016/0891-5849(90)90131-2
34. Heidari R, Jamshidzadeh A, Keshavarz N, Azarpira N. Mitigation of Methimazole-Induced Hepatic Injury by Taurine in Mice. *Sci Pharm.* 2015;83(1):143-58. doi: 10.3797/scipharm.1408-04
35. Heidari R, Babaei H, Roshangar L, Eghbal MA. Effects of Enzyme Induction and/or Glutathione Depletion on Methimazole-Induced Hepatotoxicity in Mice and the Protective Role of N-Acetylcysteine. *Adv Pharm Bull.* 2014;4(1):21-8. doi: 10.5681/apb.2014.004
36. Sedlak J, Lindsay R. Estimation of Total, Protein-Bound, and Nonprotein Sulfhydryl Groups in Tissue with Ellman's Reagent. *Anal Biochem.* 1968;25(1):192-205.
37. Shacter E. Quantification and Significance of Protein Oxidation in Biological Samples. *Drug Metab Rev.* 2000;32(3-4):307-26. doi: 10.1081/DMR-100102336
38. Mehta R, Wong L, O'Brien PJ. Cytoprotective mechanisms of carbonyl scavenging drugs in isolated rat hepatocytes. *Chem Biol Interact.* 2009;178(1-3):317-23. doi: 10.1016/j.cbi.2008.10.026
39. Mostafalou S, Eghbal MA, Nili-Ahmadabadi A, Baeeri M, Abdollahi M. Biochemical evidence on the potential role of organophosphates in hepatic glucose metabolism toward insulin resistance through inflammatory signaling and free radical pathways. *Toxicol Ind Health.* 2012;28(9):840-51. doi: 10.1177/0748233711425073
40. Gupta R, Dubey DK, Kannan GM, Flora SJS. Concomitant administration of Moringa oleifera seed powder in the remediation of arsenic-induced oxidative stress in mouse. *Cell Biol Int.* 2007;31(1):44-56. doi: 10.1016/j.cellbi.2006.09.007
41. Heidari R, Taheri V, Rahimi HR, Shirazi Yeganeh B, Niknahad H, Najibi A. Sulfasalazine-induced renal injury in rats and the protective role of thiol-reductants. *Ren Fail.* 2016;38(1):137-41. doi: 10.3109/0886022X.2015.1096731
42. Alía M, Horcajo C, Bravo L, Goya L. Effect of grape antioxidant dietary fiber on the total antioxidant capacity and the activity of liver antioxidant enzymes in rats. *Nutr Res.* 2003;23(9):1251-67. doi: 10.1016/S0271-5317(03)00131-3
43. Moezi L, Heidari R, Amirghofran Z, Nekooeian AA, Monabati A, Dehpour AR. Enhanced anti-ulcer effect of pioglitazone on gastric ulcers in cirrhotic rats: The role of nitric oxide and IL-1b. *Pharmacol Rep.* 2013;65(1):134-43. doi: 10.1016/S1734-1140(13)70971-X
44. Heidari R, Babaei H, Eghbal MA. Amodiaquine-induced toxicity in isolated rat hepatocytes and the cytoprotective effects of taurine and/or N-acetyl cysteine. *Res Pharm Sci.* 2014;9(2):97-105.
45. Jaeschke H, McGill MR, Ramachandran A. Oxidant stress, mitochondria, and cell death mechanisms in drug-induced liver injury: lessons learned from acetaminophen hepatotoxicity. *Drug Metab Rev.* 2012;44(1):88-106. doi: 10.3109/03602532.2011.602688
46. Farombi EO. Influence of Amodiaquine treatment on microsomal lipid peroxidation and antioxidant defense systems of rats. *Pharmacol Toxicol.* 2000;87:249-54. doi: 10.1034/j.1600-0773.2000.pto870601.x
47. Jaeschke H, Gores GJ, Cederbaum AI, Hinson JA, Pessayre D, Lemasters JJ. Mechanisms of Hepatotoxicity. *Toxicol Sci.* 2002;65(2):166-76. doi: 10.1093/toxsci/65.2.166
48. Reed DJ. Glutathione: toxicological implications. *Annu Rev Pharmacol Toxicol.* 1990;30:603-31. doi: 10.1146/annurev.pa.30.040190.003131
49. Yokoyama H, Horie T, Awazu S. Oxidative stress in isolated rat hepatocytes during naproxen metabolism. *Biochem Pharmacol.* 1995;49(7):991-6. doi: 10.1016/0006-2952(94)00542-T
50. Farombi EO, Olowu BI, Emerole GO. Effect of three structurally related antimalarial drugs on liver microsomal components and lipid peroxidation in rats. *Comp Biochem Physiol C Toxicol Pharmacol.* 2000;126(3):217-24. doi: 10.1016/s0742-8413(00)00116-x
51. Farombi EO, Adoro S, Uhunmwangho S. Antimalarial drugs exacerbate rat liver microsomal lipid peroxidation in the presence of oxidants. *Biosci Rep.* 2001;21(3):353-9. doi: 10.1023/A:1013242401009
52. Shimizu S, Atsumi R, Itokawa K, Iwasaki M, Aoki T, Ono C, et al. Metabolism-dependent hepatotoxicity of amodiaquine in glutathione-depleted mice. *Arch Toxicol.* 2009;83:701-7. doi: 10.1007/s00204-009-0436-9
53. Corona C, Frazzini V, Silvestri E, Lattanzio R, Sorda RL, Piantelli M, et al. Effects of dietary supplementation of carnosine on mitochondrial dysfunction, amyloid pathology, and cognitive deficits in 3xTg-AD mice. *PLoS One.* 2011;6(3):e17971. doi: 10.1371/journal.pone.0017971
54. Hipkiss AR. Aging, proteotoxicity, mitochondria, glycation, NAD+ and carnosine:

- possible inter-relationships and resolution of the oxygen paradox. *Front Aging Neurosci.* 2010;2(10):1-6. doi:10.3389/fnagi.2010.00010
55. Kim K-A, Park J-Y, Lee J-S, Lim S. Cytochrome P450 2C8 and CYP3A4/5 are involved in chloroquine metabolism in human liver microsomes. *Arch Pharm Res.* 2003;26(8):631-7. doi:10.1007/BF02976712
56. Lee JW, Miyawaki H, Bobst EV, Hester JD, Ashraf M, Bobst AM. Improved functional recovery of ischemic rat hearts due to singlet oxygen scavengers histidine and carnosine. *J Mol Cell Cardiol.* 1999;31(1):113-21. doi:10.1006/jmcc.1998.0850
57. Chan WKM, Decker EA, Lee JB, Butterfield DA. EPR spin-Trapping studies of the Hydroxyl radical scavenging activity of carnosine and related dipeptides. *J Agric Food Chem.* 1994;42(7):1407-10. doi:10.1021/jf00043a003
58. Ramaiah SK. A toxicologist guide to the diagnostic interpretation of hepatic biochemical parameters. *Food Chem Toxicol.* 2007;45(9):1551-7. doi:10.1016/j.fct.2007.06.007
59. Ozer J, Ratner M, Shaw M, Bailey W, Schomaker S. The current state of serum biomarkers of hepatotoxicity. *Toxicology.* 2008;245(3):194-205. doi:10.1016/j.tox.2007.11.021
60. Heidelbaugh JJ, Sherbondy M. Cirrhosis and chronic liver failure: part II. Complications and treatment. *Am Fam Physician.* 2006;74(5):767-76.
61. Bae O-N, Serfozo K, Baek S-H, Lee KY, Dorrance A, Rumbelha W, et al. Safety and efficacy evaluation of carnosine, an endogenous neuroprotective agent for ischemic. *Stroke.* 2013;44:205-12. doi:10.1161/STROKEAHA.112.673954
62. Aydın AF, Küçükgergin C, Özdemirler-Erata G, Koçak-Toker N, Uysal M. The effect of carnosine treatment on prooxidant-antioxidant balance in liver, heart and brain tissues of male aged rats. *Biogerontology.* 2009;11(1):103-9. doi:10.1007/s10522-009-9232-4
63. Wu X-h, Ding M-p, Zhu-Ge Z-B, Zhu Y-Y, Jin C-l, Chen Z. Carnosine, a precursor of histidine, ameliorates pentylenetetrazole-induced kindled seizures in rat. *Neurosci Lett.* 2006;400(1-2):146-9. doi:10.1016/j.neulet.2006.02.031