



Research Article

Amino Acid-Containing Krebs-Henseleit Buffer Protects Rat Liver in a Long-Term Organ Perfusion Model

Reza Heidari^{1*}, Mohammad Mehdi Ommati¹, Sanya Alahyari^{2,3}, Negar Azarpira⁴, Hossein Niknahad^{1,2*}¹Pharmaceutical Sciences Research Center, Shiraz University of Medical Sciences, Shiraz, Iran.²Pharmacology and Toxicology Department, Shiraz University of Medical Sciences, Shiraz, Iran.³Students Research Committee, Shiraz University of Medical Sciences, International Branch, Shiraz, Iran.⁴Transplant Research Center, Shiraz University of Medical Sciences, Shiraz, Iran.

Article Info

Article History:

Received: 29 April 2018

Revised: 16 May 2018

Accepted: 23 May 2018

ePublished: 23 September 2018

Keywords:

- Amino Acids
- Hepatic Failure
- Liver Injury
- Organ Transplantation
- Oxidative stress

ABSTRACT

Background: The liver is vulnerable to the toxicity induced by xenobiotics. On the other hand, it has been found that several endogenously-found amino acids have hepatoprotective properties. The current study was designed to evaluate the effect of taurine, glycine, and histidine on the liver function in an *ex vivo* model of prolonged organ perfusion.

Methods: Rat liver was isolated and perfused with a hemoglobin- and albumin-free Krebs-Henseleit buffer (KBH). Liver injury biomarkers were monitored at scheduled time intervals.

Results: The perfusate level of lactate dehydrogenase (LDH), alanine aminotransferase (ALT), aspartate aminotransferase (AST), and the potassium ion (K⁺) were gradually increased in control (Only KBH) group. The histopathological evaluation also revealed significant necrosis, sinusoidal dilation, and pyknosis in control liver. Moreover, significant increase in lipid peroxidation and depletion of hepatic glutathione stores were detected in the control group. It was found that taurine (5, 10 and 20 mM) and glycine (5, 10 and 20 mM)-containing KBH buffer significantly decreased the perfusate level of liver injury biomarkers. Furthermore, lower liver tissue pathological changes, decreased lipid peroxidation, and higher glutathione content was detected in amino acid-treated groups. Histidine administration showed no significant protective effect on liver injury in the current study. On the other hand, combination amino acid administration (glycine and taurine) showed a better hepatoprotective profile.

Conclusion: The data obtained from the current study might help to provide safe hepatoprotective agents against xenobiotics-induced hepatotoxicity or preserve liver functionality outside the body.

Introduction

Due to its dominant role in chemicals metabolism and the high blood volume received to, the liver is the most vulnerable organ to xenobiotics-induced injury.¹ Hence, finding safe and effective hepatoprotective agents with therapeutic capability could have tremendous clinical value. In this regard, different chemicals are tested for their potential hepatoprotective properties.^{2,3} Among these, several amino acids revealed hepatoprotective properties in different experimental models.⁴⁻¹³

Taurine is one of the most abundant non-protein amino acids in the human body.¹⁴ Many physiological properties are attributed to this amino acid.¹⁵ Cell volume regulation, membrane stabilization, mitochondrial protection, and antioxidant effect are essential roles of taurine in various biological systems.^{9,12,15-17} On the other hand, several pharmacological properties including anti-emetic, antiepileptic, gastroprotective, and anti-inflammatory

effects are also attributed to taurine.^{11,18-21} Taurine also has several beneficial properties in the liver and hepatocytes.^{7,9,12,22-24} It has been reported that taurine administration could ameliorate xenobiotics-induced liver injury.^{5,6,8,10,25-29} Moreover, daily taurine intake in humans is high in some counties, and the risk assessment studies revealed that taurine is a safe amino acid without any undesirable effect even at very high doses.^{30,31} In the current study, the amino acid taurine has been used to preserve liver function in a normothermic recirculating isolated perfused liver model.

Glycine is the simplest amino acid incorporated in the structure of body proteins. This amino acid is also included into the structure of the tripeptide glutathione (GSH). Previous investigations revealed several beneficial effects of glycine in liver and hepatocytes.^{4,32-34} The protective properties of glycine in other disorders also have been documented.³⁵⁻³⁸ It has been shown that

*Corresponding Author: Reza Heidari, E-mail: rezaheidari@hotmail.com and Hossein Niknahad, E-mail: niknahadh@sums.ac.ir

©2018 The Authors. This is an open access article and applies the Creative Commons Attribution (CC BY), which permits unrestricted use, distribution and reproduction in any medium, as long as the original authors and source are cited. No permission is required from the authors or the publishers.

this amino acid efficiently counteracted xenobiotics-induced liver injury.^{39,40} Different concentrations of the amino acid glycine has been applied in the current study to protect liver in a long term perfusion model.

Histidine is one of the most common natural amino acids with several biological functions. Histidine, in addition to a regular metabolic role as a protein-building block, is an efficient scavenger of toxic oxygen species.⁴¹ Direct interactions of the histidine imidazole ring with reactive oxygen species or interfering of this amino acid with the redox reactions, involving metal ions that produce the hydroxyl radical, are the postulated mechanisms by which histidine counteracts oxidative stress and its subsequent events.⁴¹ The protective properties of this amino acid have been documented in several investigations.⁴²⁻⁴⁵ In the carrageenan-induced inflammation model, histidine reduced paw edema as well as neutrophil infiltration in paw tissues.⁴⁴ Histidine also attenuated the colon histopathological changes in a rat model of acetic acid-induced colitis.⁴⁶ Several studies have reported that histidine possessed marked antioxidant activities such as scavenging free radicals, binding divalent metal ions, and anti-glycating action.^{42,43} Histidine is also reported to protect the liver against xenobiotics.⁴⁵ In the current study, different concentrations of histidine were applied to evaluate its potential hepatoprotective properties in an *ex vivo* model of rat liver perfusion.

As mentioned, finding safe hepatoprotective agents against xenobiotics hepatotoxicity of preserving liver function outside the body has clinical value. Therefore, the current investigation was designed to evaluate the effects of different amino acids (alone and in combination) with a previously reported hepatoprotective profile on the liver function in an *ex vivo* model of long-term organ perfusion.

Materials and Methods

Chemicals

5,5'-dithionitrobenzoic acid (DTNB), Taurine (2-aminoethane sulfonic acid), Glycine (Aminoethanoic acid), and Histidine (2-Amino-3-(1H-imidazole-4-yl) propanoic acid), were purchased from Sigma-Aldrich (St. Louis, USA). Thiobarbituric acid (TBA), Methanol, Trichloroacetic acid (TCA), n-Butanol, and hydroxymethyl aminomethane hydrochloride (Tris-HCl), were purchased from Merck (Dardamstd, Germany). All salts for preparing buffer solutions were of the highest grade commercially available and prepared from Merck (Dardamstd, Germany). Kits for liver perfusate biochemistry assessments were prepared from Pars Azmun® (Tehran, Iran).

Isolated perfused rat liver preparation

Male Sprague-Dawley rats (200-250 g) were purchased from the Center for Comparative and Experimental Medicine of Shiraz University of Medical Sciences and allowed free access to a standard chow diet (Behparvar®, Tehran, Iran) and tap water. The animals received human care and were handled according to the animal handling

protocol approved by an ethics committee in Faculty of Pharmacy, Shiraz University of Medical Sciences, Shiraz, Iran (95-01-36-12164). Rats were anesthetized (Thiopental, 70 mg/kg, i.p.) and liver was cannulated via the portal vein and isolated.⁴⁷⁻⁴⁸ The liver was perfused with hemoglobin- and albumin-free Krebs-Henseleit buffer (KBH) (118 mmol/l NaCl, 6 mmol/l KCl, 1.1 mmol/l MgSO₄, 1.2 mmol/l KH₂PO₄, 25 mmol/l NaHCO₃ and 1.25 mmol/l CaCl₂, pH=7.4, 37°C), continuously gassed with carbogen (95% O₂, 5% CO₂). The perfusate was pumped through the liver with a peristaltic pump (Heidolph, Germany) at a constant flow rate of 3 mL/min/g liver weight, in a recirculating mode. The perfusate buffer volume was 200 mL in all experiments.^{24,49}

Study procedure

Rat liver was perfused with simple KBH and amino acid containing KBH for 12 consecutive hours. Hepatic injury was assessed at scheduled time intervals (every 3 hours). The experimental groups were **A)** Control (Only KBH buffer); **B)** KBH + Taurine 5 mM; **C)** KBH + Taurine 10 mM; **D)** KBH + Taurine 20 mM; **E)** KBH + Glycine 5 mM; **F)** KBH + Glycine 10 mM; **G)** KBH + Glycine 20 mM; **H)** KBH + Histidine 5 mM; **I)** KBH + Histidine 10 mM; **J)** KBH + Histidine 20 mM; **K)** KBH + Glycine 10 mM+ Taurine 10 mM; **L)** KBH + Glycine 20 mM+ Taurine 20 mM.

Perfusate biochemistry and liver histopathological evaluation

A Mindray BS-200® autoanalyzer (Guangzhou, China) and standard enzymatic methods (Pars Azmun® kits, Tehran, Iran) were employed to assess the level of alanine aminotransferase (ALT), aspartate aminotransferase (AST), and lactate dehydrogenase (LDH) in liver perfusate.⁵⁰ The perfusate potassium ion (K⁺) content was measured using a flame photometer (IL943 Flame Photometer, Sysmedlabs®).⁵¹

Samples of liver were fixed in buffered formalin solution (0.4% sodium phosphate monobasic, NaH₂PO₄, 0.64% sodium phosphate dibasic, Na₂HPO₄, and 10% formaldehyde in double distilled water).⁵² Paraffin-embedded sections of liver (5 μm) were prepared and stained with hematoxylin and eosin (H&E) before light microscope viewing.

Liver glutathione content

Hepatic glutathione content was assessed using the Ellman reagent (DTNB).⁵³ Briefly, liver tissue samples (200 mg) were homogenized in 8 ml of ice-cooled EDTA solution (20 mM, 4°C). Then, 5 mL of liver homogenate was mixed with 4 mL of distilled water and 1 mL of trichloroacetic acid (TCA; 50% w/v in distilled water, 4°C). The mixture was vortexed and centrifuged (10,000 g, 15 minutes, 4°C).^{49,54} Then, 2 mL of the supernatant was added to 4 mL of Tris-HCl buffer (40 mM, pH = 8.9) and 100 μl of freshly-prepared DTNB solution (10 mM in methanol).^{53,55} The absorbance of developed yellow color

was measured ($\lambda = 412 \text{ nm}$ using an EPOCH[®] plate reader (Highland park, USA).

Lipid peroxidation

The level of lipid peroxidation in the isolated perfused liver was assessed by thiobarbituric acid reactive substances (TBARS) test.⁵⁶ The reaction mixture was consisted of 0.5 mL of liver homogenate (10%, w/v), 3 ml of meta-phosphoric acid 1% (w/v), and 1 mL of 1% (w/v) thiobarbituric acid (TBA).^{49,54,57} The mixture was vortexed and heated (100°C, 45 min). Afterward, 4 mL of n-butanol was added and vigorously mixed. After centrifugation (10,000 g, 5 min), the absorbance of developed pink color in the n-butanol phase was read at $\lambda = 532 \text{ nm}$ using an EPOCH[®] plate reader (Highland park, USA).⁵⁶

Statistical analysis

Data are shown as the Mean \pm SD. The one-way analysis of variance (ANOVA) with Tukey's multiple comparison test as a *post hoc* was employed for data sets comparison. Differences were considered statistically significant when $P < 0.05$.

Results

The perfusate level of liver injury biomarkers in control group (only KBH buffer) gradually increased until the end of the experiment (Figure 1-3).

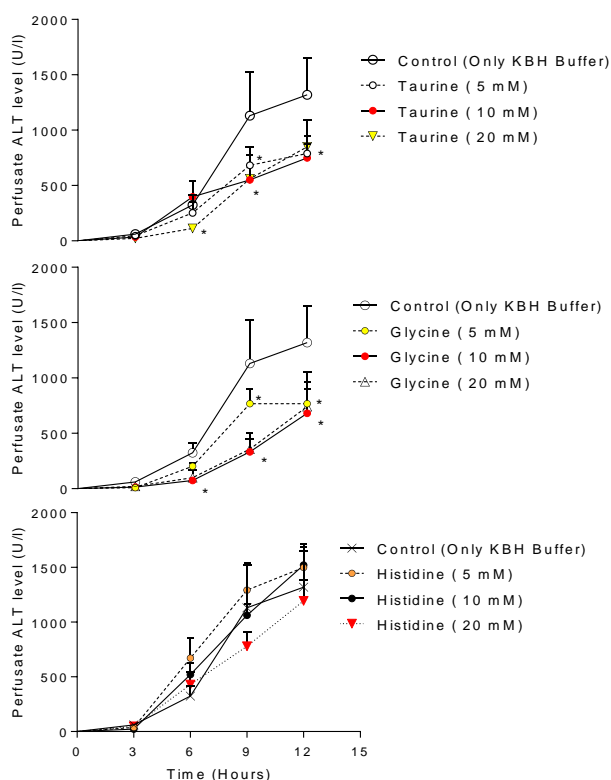


Figure 1. Effect of taurine, glycine, and histidine supplementation on liver perfusate ALT level at different time points. KBH: Krebs-Henseleit buffer.

Data are given as Mean \pm SD (n = 5).

*Indicates significantly different as compared with control (Only KBH buffer) ($P < 0.05$).

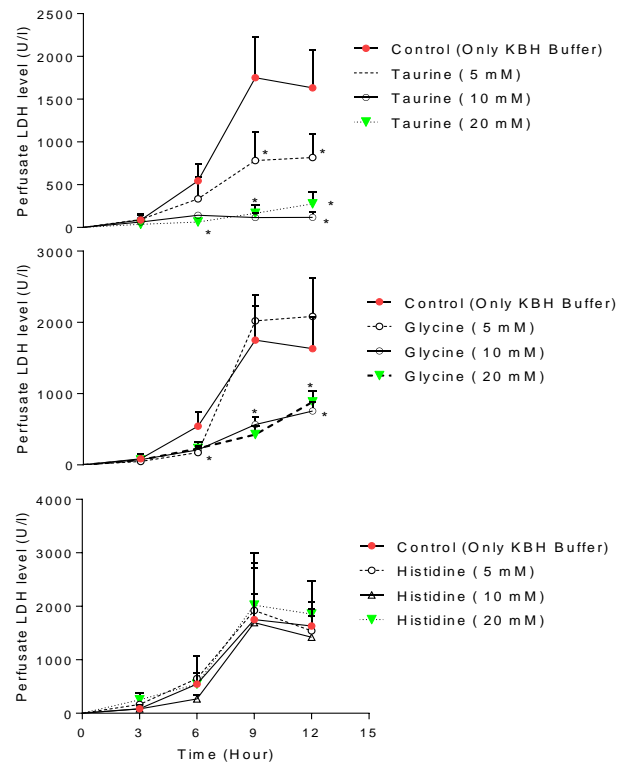


Figure 2. Effect of amino acid-containing KBH perfusion to the liver on the perfusate LDH level. KBH: Krebs-Henseleit buffer. Data are given as Mean \pm SD (n = 5). *Indicates significantly different as compared with control (Only KBH buffer) ($P < 0.05$).

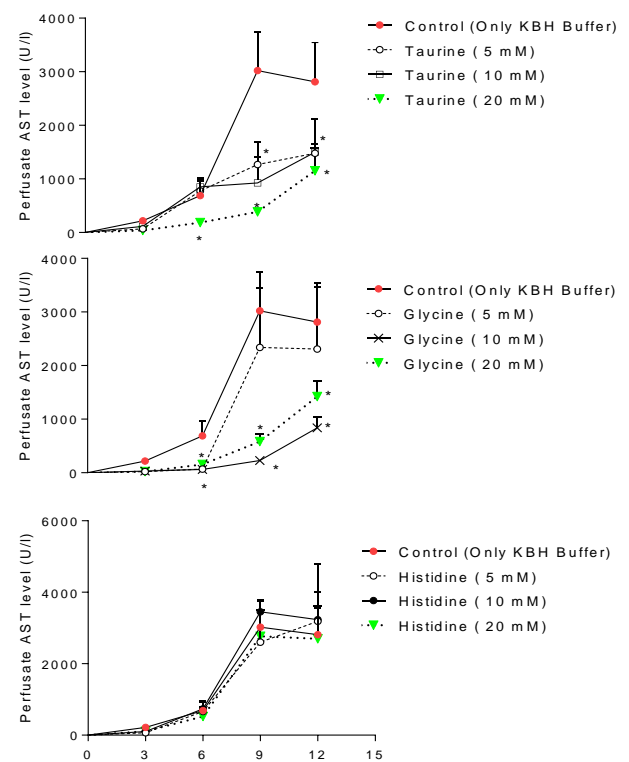


Figure 3. Liver perfusate AST level at different time points and the role of amino acid supplementation. KBH: Krebs-Henseleit buffer.

Data are given as Mean \pm SD (n = 5).

*Indicates significantly different as compared with control (Only KBH buffer) ($P < 0.05$).

It was found that the perfusate level of ALT, AST, and LDH were significantly higher in control group (Only KBH buffer) (Figures 1-3). On the other hand, the isolated liver was perfused with the KBH buffer containing taurine (5, 10, and/or 20 mM) and glycine (5, 10, and/or 20 mM). It was found that the biomarkers of liver injury were significantly lower in amino acid-treated groups (Figures 1-3). Moreover, it was found that histidine administration (5, 10, and/or 20 mM) could not mitigate liver injury as judged by the perfusate level of ALT, LDH, and AST (Figure 1-3).

The perfusate level of K^+ was assessed as a parameter of hepatocytes intactness. It was found that the perfusate K^+ level was significantly increased in the control group (Figure 4). Taurine (5, 10, and/or 20 mM) and glycine (10 and/or 20mM) supplementation ameliorated K^+ release, where histidine (5, 20, and/or 20 mM) administration did not significantly affect the perfusate K^+ level in the current investigation (Figure 4).

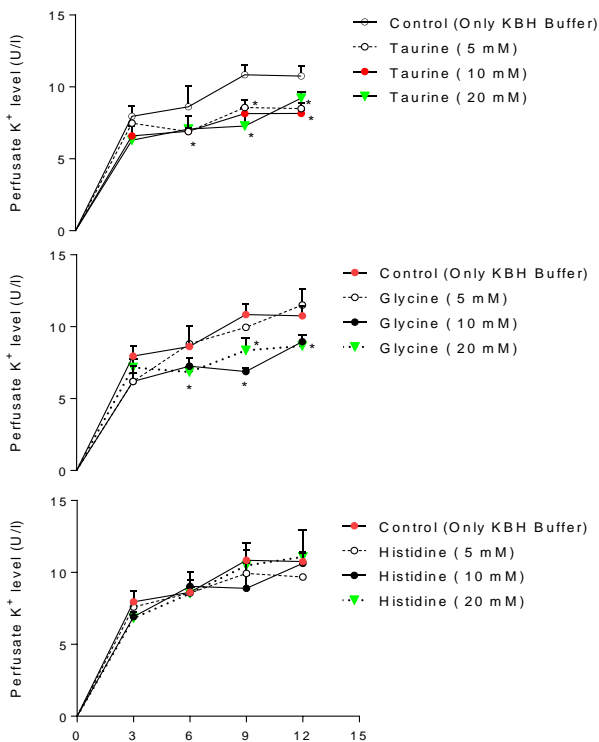


Figure 4. Liver perfusate potassium (K^+) level. KBH: Krebs-Henseleit buffer. Data are given as Mean \pm SD (n = 5). *Indicates significantly different as compared with the control group (Only KBH buffer) (P < 0.05).

It was found that liver glutathione content was depleted in control (Only KBH)-treated rats (Figure 5). Moreover, a significant amount of lipid peroxidation was detected in control group (Figure 6). On the other hand, the perfusion of taurine (10 and/or 20 mM) and glycine (10 and 20 mM)-containing KBH significantly prevented the decrease in hepatic glutathione content over time (Figure 5). Histidine (5, 10, and/or 20 mM) administration did not change hepatic glutathione reservoirs (Figure 5).

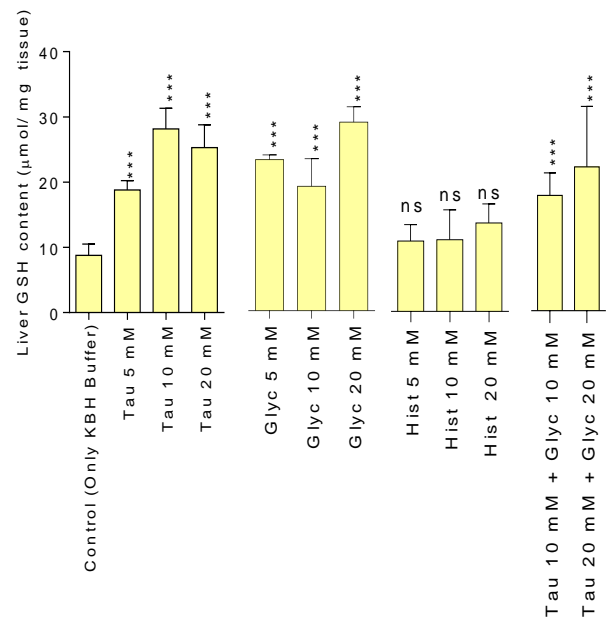


Figure 5. Liver glutathione content. Data are presented as Mean \pm SD (n = 5). KBH: Krebs-Henseleit buffer; Tau: Taurine; Glyc: Glycine; Hist: Histidine. ***Indicates significantly different as compared with the control group (Only KBH buffer) group (P < 0.01). ns: no significant difference as compared to control (only KBH buffer).

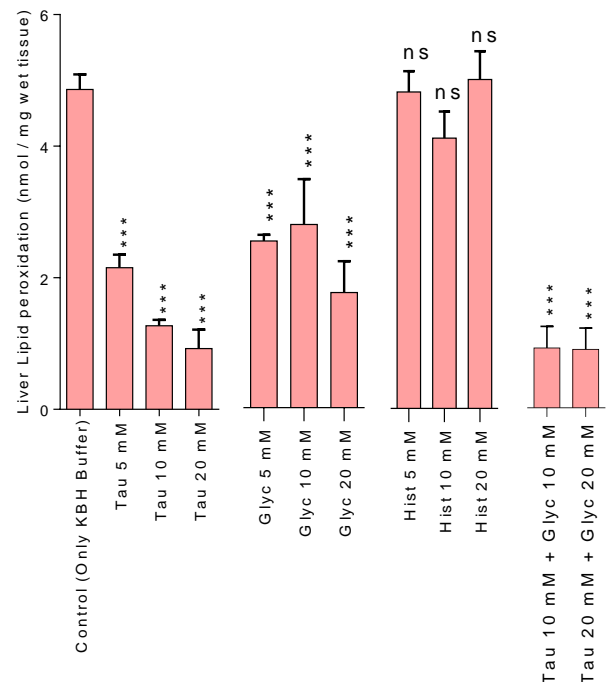


Figure 6. Effect of amino acid supplementation on liver tissue lipid peroxidation in the ex vivo model of isolated perfused rat liver. KBH: Krebs-Henseleit Buffer. Tau: Taurine. Glyc: Glycine. Hist: Histidine. Data are presented as Mean \pm SD (n = 5). ***Indicates significantly different as compared with control (Only KBH buffer) group (P < 0.01). ns: Indicates no significant difference as compared with control (Only KBH buffer).

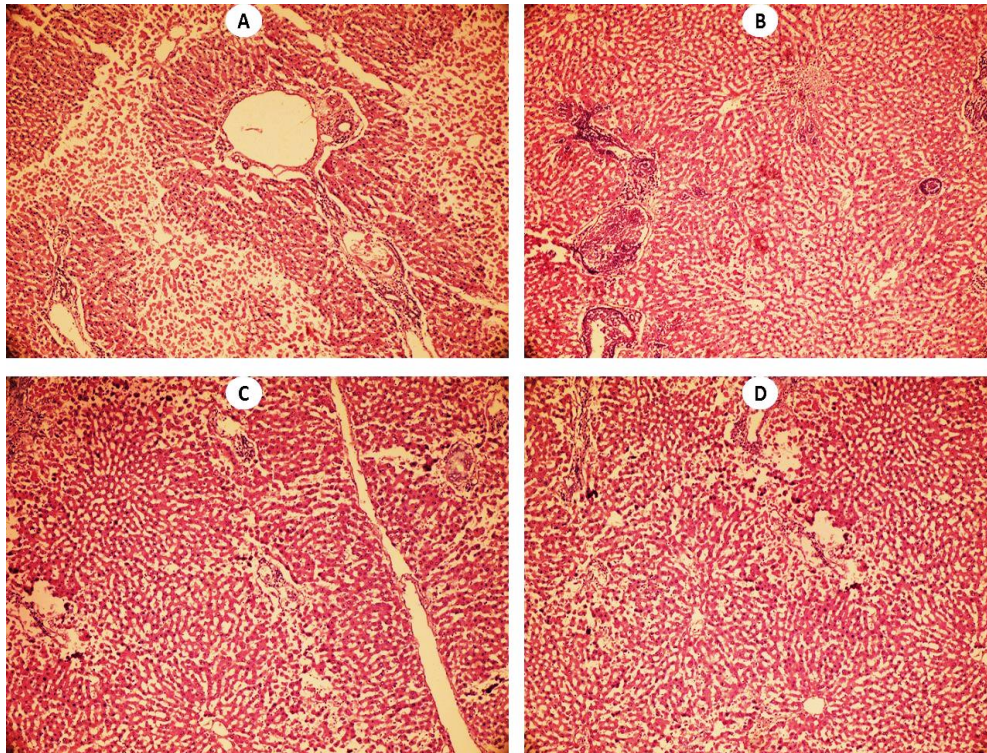


Figure 7. Liver histopathological changes in control and taurine-treated groups. H&E photomicrographs of liver tissue perfused for 12 consecutive hours with KBH buffer and amino acid-containing KBH buffer. A: Control (Only Krebs-Henseleit Buffer; KBH) group, showed intensive tissue necrosis, pyknosis, and sinusoidal dilation (Table 1). B: Rat liver was perfused with KBH buffer containing Taurine 5 mM for 12 hours. Liver injury was mitigated as compared to A (Table 1). C: Rat liver was perfused with KBH buffer containing 10 mM of taurine. D: Isolated rat liver was perfused with Taurine 20 mM-containing KBH buffer for 12 hours. Taurine perfusion (5, 10, and 20 mM) effectively ameliorated liver injury (Table 1).

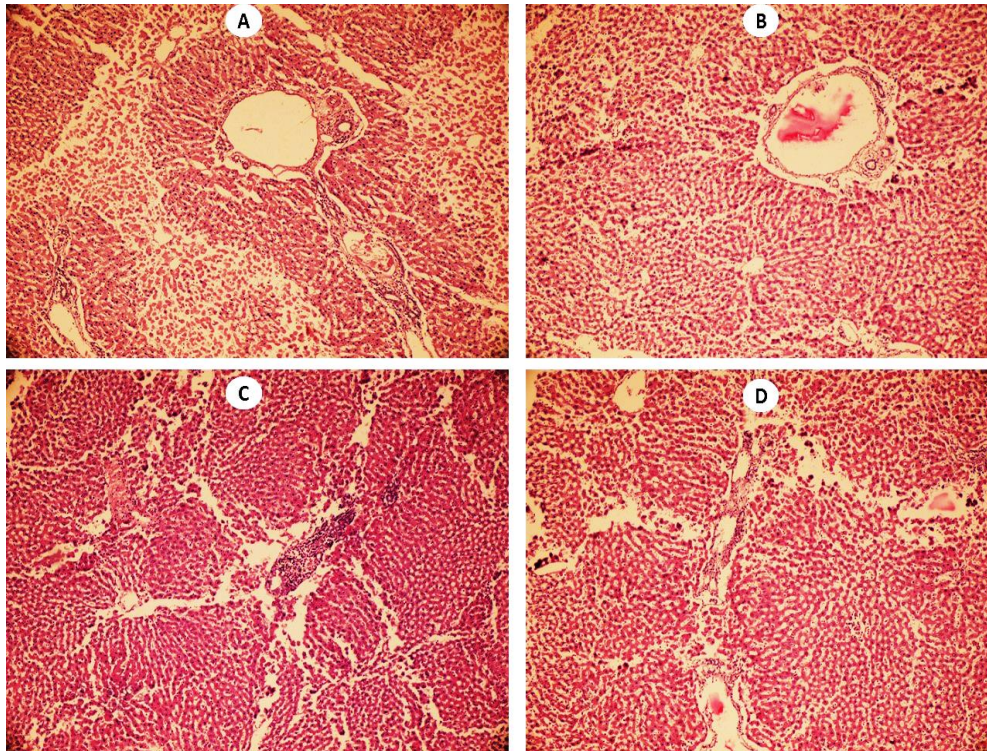


Figure 8. Effect of glycine administration on liver histopathological changes. H&E photomicrographs of liver tissue perfused for 12 hours with KBH buffer and amino acid-containing KBH buffer. A: Control (Only Krebs-Henseleit Buffer; KBH) group, showed massive tissue necrosis, pyknosis, and sinusoidal dilation (Table 1). B: Rat liver was perfused with KBH buffer containing glycine 5 mM for 12 hours. Liver injury was ameliorated as compared to A (Table 1). C: Isolated rat liver was perfused with Glycine 10 mM-containing KBH buffer for 12 hours. D: Isolated rat liver was perfused with Glycine 20 mM-containing KBH buffer for 12 hours. Glycine efficiently prevented liver injury (Table 1).

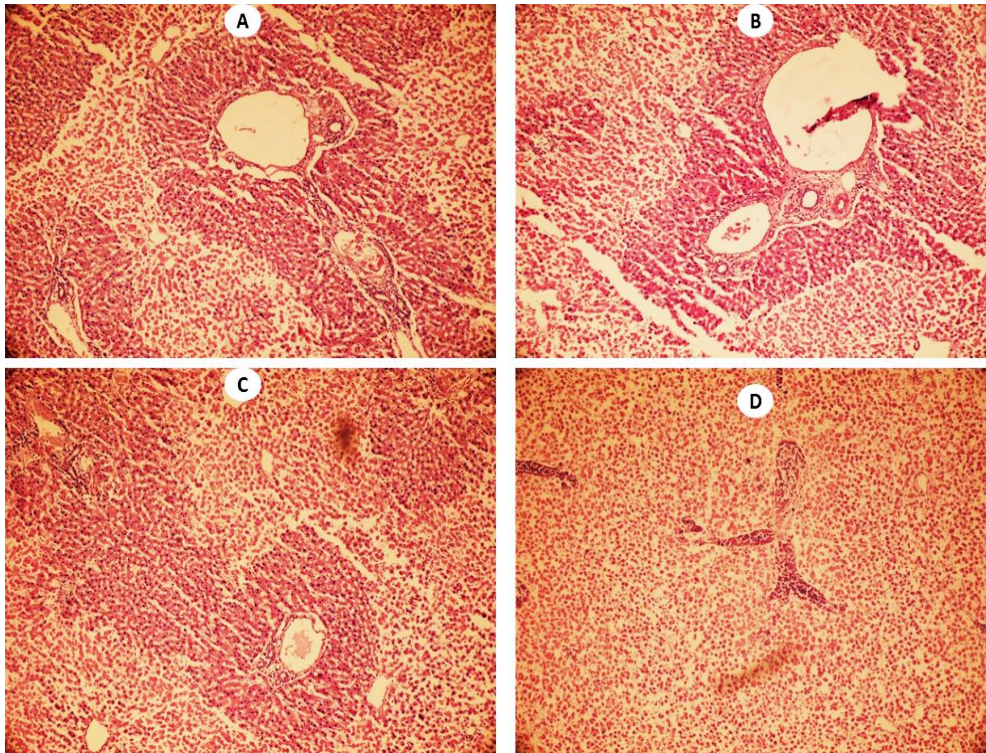


Figure 9. Effect of histidine administration on isolated-perfused rat liver. H&E photomicrographs of liver tissue perfused for 12 hours with KBH buffer and amino acid-containing KBH buffer. A: Control (Only Krebs-Henseleit Buffer; KBH) group, showed intensive sinusoidal dilation, tissue necrosis, and pyknosis (Table 1). B, C, and D: Rat liver were perfused with KBH buffer containing histidine 5 mM, 10 mM, and 20 mM respectively. Histidine administration did not change liver injury as compared to A (Table 1).

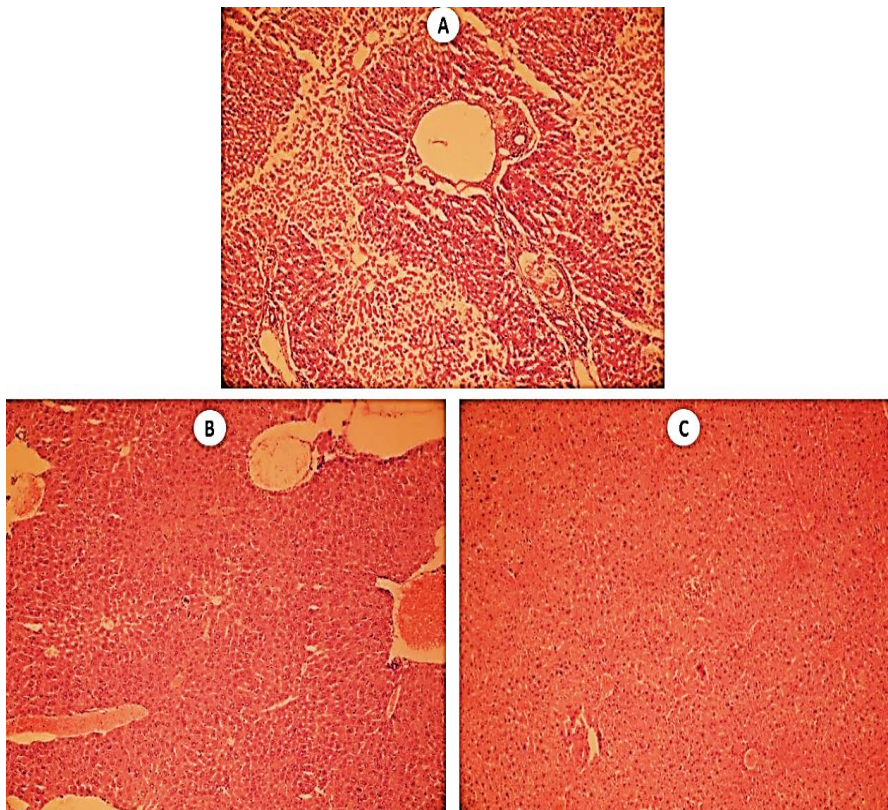


Figure 10. Effect of the amino acid cocktail (glycine and taurine) on liver histopathology. H&E photomicrographs of liver tissue perfused for 12 hours with KBH buffer and amino acid-containing KBH buffer. A: Control (Only Krebs-Henseleit Buffer; KBH) group, showed intensive sinusoidal dilation, tissue necrosis, and pyknosis (Table 1). B: Rat liver was perfused with KBH buffer containing Taurine 10 mM + Glycine 10 mM for 12 hours. Liver injury was significantly mitigated as compared to A (Table 1). C: Isolated rat liver was perfused with Taurine 20 mM + Glycine 20 mM KBH buffer for 12 hours. Taurine and glycine perfusion efficiently ameliorated liver injury in this group (Table 1).

Taurine (10 and/or 20 mM) and glycine (10 and 20 mM) also effectively alleviated lipid peroxidation when they were perfused to rat liver (Figure 6). Histidine (5, 10, and/or 20 mM) perfusion did not change liver lipid peroxidation in the current study (Figure 6). It was found that taurine and glycine combination therapy were also effective in preventing hepatic glutathione depletion and alleviating lipid peroxidation in isolated perfused rat liver (Figures 5 and 6).

Liver histopathological changes in control (Only KBH group) revealed as intensive tissue necrosis, pyknosis, and sinusoidal dilation (Figure 7 and Table 1). On the other hand, it was found that liver tissue histopathological changes were mitigated in taurine (5, 10, and/or 20 mM) and glycine (5, 10, and/or 20 mM)-treated groups (Figure 7 and 8 and Table 1). Evaluation of the histidine-treated isolated liver revealed that this amino acid did not change liver histopathology as compared with control group (Figure 9 and Table 1).

Table 1. Grades of liver histopathological changes in the presence of investigated amino acids.

Treatment	Pyknosis	Necrosis	Sinusoidal Dilation	Total Grade
Control(only KBH buffer)	++	+++	+++	8
+ Tau 5 mM	++	+++	++	7
+ Tau 10 mM	+	++	++	5
+ Tau 20 mM	+	++	++	5
+ Glyc 5 mM	++	++	+++	7
+ Glyc 10 mM	+	++	++	5
+ Glyc 20 mM	+	++	++	5
+ Hist 5 mM	++	+++	++	7
+ Hist 10 mM	++	+++	++	7
+ Hist 20 mM	++	+++	++	7
+Tau 10 mM + Glyc 10 mM	+	+	++	4
+Tau 20 mM + Glyc 20 mM	+	+	++	4

+: Mild; ++: Moderate; and +++: Severe liver tissue histopathological alterations. KBH: Krebs-Henseleit buffer. Tau: Taurine. Glyc: Glycine. Hist: Histidine.

Table 2. Effect of taurine and glycine combination therapy on liver injury biomarkers in isolated perfused rat liver.

Time (hour):	Perfusate LDH (U/I)			
	3	6	9	12
Control (Only KBH buffer)	87±32	544±102	1752±237	1632±220
+Tau 10 mM	63±18	142±19 [*]	116±29 [*]	118±30 [*]
+Tau 20 mM	36±11	63±15 [*]	166±50 [*]	275±65 [*]
+Glyc 10 mM	74±20	212±26 [*]	567±56 [*]	757±64 [*]
+Glyc 20 mM	69±17	231±47 [*]	426±58 [*]	883±81 [*]
+Tau 10 mM + Glyc 10 mM	14±9 ^{*,a}	83±23 ^{*,a}	109±28 ^{*,a}	134±21 ^{*,a}
+Tau 20 mM + Glyc 20 mM	17±4 ^{*,b}	58±12 ^{*,b}	114±31 ^{*,b}	144±26 ^{*,b}
Time (hour):	Perfusate ALT (U/I)			
	3	6	9	12
Control (Only KBH buffer)	61±8	325±44	1130±197	1319±168
+Tau 10 mM	35±6 [*]	398±71	550±114 [*]	749±100 [*]
+Tau 20 mM	22±6 [*]	112±4 [*]	561±145 [*]	849±123 [*]
+Glyc 10 mM	15±1 [*]	74±5 [*]	333±86 [*]	680±143 [*]
+Glyc 20 mM	20±1 [*]	99±35 [*]	358±46 [*]	741±155 [*]
+Tau 10 mM + Glyc 10 mM	27±4 [*]	125±18 ^{*,a}	280±39 ^{*,a}	452±58 ^{*,a}
+Tau 20 mM + Glyc 20 mM	28±6 [*]	73±14 ^{*,b}	121±22 ^{*,b}	208±79 ^{*,b}
Time (hour):	Perfusate AST (U/I)			
	3	6	9	12
Control (Only KBH buffer)	217±15	687±157	3023±418	2810±425
+Tau 10 mM	114±7 [*]	851±71	926±276 [*]	1497±357 [*]
+Tau 20 mM	38±9 [*]	184±26 [*]	384±13 [*]	1152±247 [*]
+Glyc 10 mM	33±7 [*]	60±9 [*]	229±45 [*]	837±119 [*]
+Glyc 20 mM	22±6 [*]	154±29 [*]	580±80 [*]	1420±164 [*]
+Tau 10 mM + Glyc 10 mM	31±9 [*]	77±23 ^{*,a}	117±21 ^{*,a}	207±34 ^{*,a}
+Tau 20 mM + Glyc 20 mM	17±7 [*]	65±12 ^{*,b}	98±31 ^{*,b}	177±45 ^{*,b}
Time (hour):	Perfusate K ⁺ (mg/dl)			
	3	6	9	12
Control (Only KBH buffer)	8±0.36	9±0.72	11±0.35	11±0.34
+Tau 10 mM	7±0.37	7±0.52 [*]	8±0.05 [*]	8±0.11 [*]
+Tau 20 mM	6±0.11 [*]	7±0.11 [*]	7±0.64 [*]	9±0.21 [*]
+Glyc 10 mM	6±0.31 [*]	7±0.27 [*]	7±0.12 [*]	9±0.10 [*]
+Glyc 20 mM	7±0.30	7±0.17 [*]	8±0.42 [*]	8±0.37 [*]
+Tau 10 mM + Glyc 10 mM	6±0.18 ^{*,a}	7±0.35 ^{*,a}	8±0.27 ^{*,a}	8±0.41 ^{*,a}
+Tau 20 mM + Glyc 20 mM	7±0.53	7±0.44 ^{*,b}	8±0.35 ^{*,b}	8±0.60 ^{*,b}

Data are given as Mean±SD (n = 5). KBH: Krebs-Henseleit buffer; Tau: Taurine; Glyc: Glycine. *Indicates significantly different as compared with control (Only KBH buffer) (P<0.001). ^a Indicates significantly different as compared with glycine (10 mM) and/or taurine (10 mM). ^b Indicates significantly different as compared with glycine (20 mM) and/or taurine (20 mM).

It was found that taurine and glycine combination therapy also significantly mitigated liver histopathological changes (Figure 10 and Table 2).

As mentioned, isolated rat liver was also perfused with a combination of taurine (10 and/or 20 mM) and glycine (10 and/or 20 mM) (Table 2). It is noteworthy to mention that glycine and taurine combination therapy was significantly more effective with amino acid monotherapy in preserving liver function ($P < 0.05$ in all assessed parameters, except for liver glutathione content and lipid peroxidation) (Table 2 and Figures 5 and 6).

Discussion

The liver is the target organ for many toxicants. The anatomical, biochemical, and physiological features of the liver makes it particularly sensitive to many foreign compounds. Hence, finding safe hepatoprotective agents has a significant clinical value. On the other hand, preserving the liver functionality at a normal level has a great clinical value in situations such as liver transplantation. The current investigation was designed to evaluate the role of amino acids with a previously reported hepatoprotective profile in an *ex vivo* model of prolonged perfusion of the rat liver (12 hours). It was found that taurine (10 and/or 20 mM) and glycine (10 and/or 20 mM), alone or in combination, effectively preserved liver function when they were added to the KBH buffer as the liver perfusate.

Taurine is a very safe amino acid,⁵⁸ which its hepatoprotective properties have been proved in several experimental models.^{9,24,59} Taurine concentrations reach at millimolar (1-20 mM) level in some tissues such as brain and skeletal muscles as well as plasma samples.⁶⁰ This amino acid might reach up to the concentration of 50 mM in leukocytes.⁶¹ The mechanisms of hepatoprotection provided by taurine might be greatly mediated by its effect on oxidative stress parameters.^{9,24,59,62} The antioxidant capacity of taurine is also believed to be mediated through its effect on cell mitochondria.^{12,63} In addition, taurine efficiently mitigates biological membranes disruption and lipid peroxidation.^{64,65} In the current study we found that taurine supplementation mitigated markers of oxidative stress which were evident by higher hepatic glutathione reservoirs and significantly lower amount of tissue lipid peroxidation. Therefore, the antioxidative stress properties of taurine might play a fundamental role in its mechanism of hepatoprotection in the current experimental model. On the other hand, risk assessment studies revealed that taurine is a safe compound in humans even at very high doses.⁵⁸ Hence, taurine could be a safe and effective hepatoprotective agent with the potential clinical application.

Glycine (10 and/or 20 mM) significantly prevented liver injury in our prolonged organ perfusion model. It has been found that this simple amino acid has excellent protective properties in several experimental models.^{24,66-70} Some investigations mentioned that the protective properties of glycine might be mediated through its anti-inflammatory effects.^{71,72} The antioxidant properties of glycine also

have been reported in previous investigations.^{24,33,69,73-75} It has been found that glycine is capable of preventing xenobiotics-induced liver injury.^{24,33,69,73,75} Glycine is also an essential component of the glutathione molecule. Glutathione is needed for cell defense mechanisms against oxidative stress. Moreover, it has been found that glycine efficiently protected organs against hypoxic injury.^{39,70,76} The effect of glycine on non-parenchymal liver cells might also be involved in its hepatoprotective properties.⁷² Collectively, all these studies mention the hepatoprotective potential of glycine. In the current study, we found that glycine supplementation significantly preserved liver function and counteracted oxidative stress and its consequences. On the other hand, as glycine is an endogenous compound, high doses of this amino acid could be administered in humans.^{32,77} High plasma level of this amino acid is found in human subjects.⁷⁸ Hence, this amino acid might be applicable in humans to protect the liver against a variety of xenobiotics or preserving liver function outside the body (*e.g.*, for liver transplantation).

Although some investigations mentioned the hepatoprotective role of histidine in animal models of liver injury,⁴⁵ we found that this amino acid did not change the liver injury biomarkers in the *ex vivo* model of isolated perfused rat liver. Histidine is reported to be a radical scavenger,⁷⁹ but its effect on liver lipid peroxidation and glutathione content was not significant in the current investigation. The insignificant effect of histidine in the current *ex vivo* model might be associated with different factors such as the concentrations of histidine applied in this study.

Conclusion

Preserving organ function in the *ex vivo* conditions is a critical challenge for organ transplantation. In this regard, several protective strategies in addition of different protective agents have been applied.⁸⁰ It has been shown that supplementation of the liver with several protecting agents including different antioxidants preserved liver function in *ex vivo* conditions.⁸⁰ Based on the data presented in the current study, we might be able to propose that taurine and glycine could be ideal protective agents with therapeutic capability not only against xenobiotics-induced liver injury but also as a tool in organ transplantation and protecting other isolated organs (*e.g.*, heart, kidney).

Collectively, the current investigation revealed significant hepatoprotective effects of taurine and glycine (alone or in combination). Hence, these amino acids are potential candidates of safe and effective hepatoprotective agents to preserve the liver function out of the body (*e.g.*, for organ transplantation) or protecting this organ against a wide range of xenobiotics-induced hepatotoxicity.

Acknowledgments

The authors thank Pharmaceutical Sciences Research Center and the Vice-chancellor of the Research Affairs of Shiraz University of Medical Sciences for providing

technical and financial facilities (Grant number: 95-01-36-12164) to carry out this investigation.

Conflict of Interests

The authors declare that there are no competing interests.

References

- Corsini A, Bortolini M. Drug-induced liver injury: The role of drug metabolism and transport. *J Clin Pharmacol.* 2013;53(5):463-74. doi:10.1002/jcph.23
- Strubelt O, Younes M, Li Y. Protection by albumin against ischaemia- and hypoxia-induced hepatic injury. *Pharmacol Toxicol.* 1994;75(3-4):280-4. doi:10.1111/j.1600-0773.1994.tb00361.x
- Heidari R, Niknahad H, Jamshidzadeh A, Azarpira N, Bazary M, Najibi A. Carbonyl traps as potential protective agents against methimazole-induced liver injury. *J Biochem Mol Toxicol.* 2014;29(4):173-81. doi:10.1002/jbt.21682
- Chen C-Y, Wang B-T, Wu Z-C, Yu W-T, Lin P-Y, Tsai W-L, et al. Glycine ameliorates liver injury and vitamin D deficiency induced by bile duct ligation. *Clin Chim Acta.* 2013;420:150-4. doi:10.1016/j.cca.2012.10.016
- Ghosh M, Pal S, Sil PC. Taurine attenuates nano-copper-induced oxidative hepatic damage via mitochondria-dependent and NF- κ B/TNF- α -mediated pathway. *Toxicol Res.* 2014;3(6):474-86. doi:10.1039/c4tx00030g
- Heidari R, Babaei H, Eghbal MA. Ameliorative effects of taurine against methimazole-induced cytotoxicity in isolated rat hepatocytes. *Sci Pharm.* 2012;80(4):987-99. doi:10.3797/scipharm.1205-16
- Abdoli N, Heidari R, Azarmi Y, Eghbal MA. Mechanisms of the statins cytotoxicity in freshly isolated rat hepatocytes. *J Biochem Mol Toxicol.* 2013;27(6):287-94. doi:10.1002/jbt.21485
- Heidari R, Babaei H, Eghbal MA. Amodiaquine-induced toxicity in isolated rat hepatocytes and the cytoprotective effects of taurine and/or N-acetyl cysteine. *Res Pharm Sci.* 2014;9(2):97-105.
- Heidari R, Jamshidzadeh A, Niknahad H, Mardani E, Ommati MM, Azarpira N, et al. Effect of taurine on chronic and acute liver injury: Focus on blood and brain ammonia. *Toxicol Report.* 2016;3:870-9. doi:10.1016/j.toxrep.2016.04.002
- Jagadeesan G, Pillai SS. Hepatoprotective effects of taurine against mercury induced toxicity in rat. *J Environ Biol.* 2007;28(4):753-6.
- Oja SS, Saransaari P. Pharmacology of taurine. *Proc West Pharmacol Soc.* 2007;50:8-15.
- Jamshidzadeh A, Heidari R, Abasvali M, Zarei M, Ommati MM, Abdoli N, et al. Taurine treatment preserves brain and liver mitochondrial function in a rat model of fulminant hepatic failure and hyperammonemia. *Biomed Pharmacother.* 2017;86:514-20. doi:10.1016/j.biopha.2016.11.095
- Karamikhah R, Jamshidzadeh A, Azarpira N, Saeedi A, Heidari R. Propylthiouracil-induced liver injury in mice and the protective role of taurine. *Pharm Science.* 2015;21(2):94-101. doi:10.15171/ps.2015.23
- Lourenco R, Camilo ME. Taurine: a conditionally essential amino acid in humans? An overview in health and disease. *Nutr Hosp.* 2002;17(6):262-70.
- Huxtable RJ. Physiological actions of taurine. *Physiol Rev.* 1992;72(1):101-63. doi:10.1152/physrev.1992.72.1.101
- Pasantes-Morales H, Quesada O, Moran J. Taurine: an osmolyte in mammalian tissues. *Adv Exp Med Biol.* 1998:209-217. doi:10.1007/978-1-4899-0117-0_27
- Atmaca G. Antioxidant effects of sulfur-containing amino acids. *Yonsei Med J.* 2004;45(5):776-88. doi:10.3349/ymj.2004.45.5.776
- Islambulchilar M, Asvadi I, Sanaat Z, Esfahani A, Sattari M. Taurine attenuates chemotherapy-induced nausea and vomiting in acute lymphoblastic leukemia. *Amino Acids.* 2015;47(1):101-9. doi:10.1007/s00726-014-1840-x
- Motawi TK, Abd Elgawad HM, Shahin NN. Modulation of indomethacin-induced gastric injury by spermine and taurine in rats. *J Biochem Mol Toxicol.* 2007;21(5):280-8. doi:10.1002/jbt.20194
- Oja SS, Saransaari P. Taurine and epilepsy. *Epilepsy Res.* 2013;104(3):187-94. doi:10.1016/j.epilepsyres.2013.01.010
- Marcinkiewicz J, Kontny E. Taurine and inflammatory diseases. *Amino Acids.* 2014;46(1):7-20. doi:10.1007/s00726-012-1361-4
- Timbrell JA, Seabra V, Waterfield CJ. The in vivo and in vitro protective properties of taurine. *Gen Pharmacol.* 1995;26(3):453-62. doi:10.1016/0306-3623(94)00203-y
- Das J, Roy A, Sil PC. Mechanism of the protective action of taurine in toxin and drug induced organ pathophysiology and diabetic complications: a review. *Food Funct.* 2012;3(12):1251-64. doi:10.1039/c2fo30117b
- Heidari R, Jamshidzadeh A, Niknahad H, Safari F, Azizi H, Abdoli N, et al. The hepatoprotection provided by taurine and glycine against antineoplastic drugs induced liver injury in an ex vivo model of normothermic recirculating isolated perfused rat liver. *Trends Pharm Sci.* 2016;2(1):59-76.
- Das J, Ghosh J, Manna P, Sil PC. Acetaminophen induced acute liver failure via oxidative stress and JNK activation: Protective role of taurine by the suppression of cytochrome P450 2E1. *Free Radic Res.* 2010;44(3):340-55. doi:10.3109/10715760903513017
- Boşgelmez P, Soylemezoğlu T, Guvendik G. The protective and antidotal effects of taurine on hexavalent chromium-induced oxidative stress in mice liver tissue. *Biol Trace Elem Res.* 2008;125(1):46-58. doi:10.1007/s12011-008-8154-3
- Das J, Ghosh J, Manna P, Sil PC. Taurine protects acetaminophen-induced oxidative damage in mice kidney through APAP urinary excretion and CYP2E1

- inactivation. *Toxicology*. 2010;269(1):24-34. doi:10.1016/j.tox.2010.01.003
28. Heidari R, Babaei H, Eghbal MA. Cytoprotective effects of taurine against toxicity induced by isoniazid and hydrazine in isolated rat hepatocytes. *Arch Ind Hyg Toxicol*. 2013;64(2):201-10. doi:10.2478/10004-1254-64-2013-2297
 29. Eftekhari A, Ahmadian E, Azarmi Y, Parvizpur A, Khalili Fard J, Eghbal MA. The effects of cimetidine, n-acetylcysteine, and taurine on thioridazine metabolic activation and induction of oxidative stress in isolated rat hepatocytes. *Pharm Chem J*. 2018;51(11):965-9. doi:10.1007/s11094-018-1724-6
 30. Shao A, Hathcock JN. Risk assessment for the amino acids taurine, l-glutamine and l-arginine. *Regulat Toxicol Pharmacol*. 2008;50(3):376-99. doi:10.1016/j.yrtph.2008.01.004
 31. Kibayashi E, Yokogoshi H, Mizue H, Miura K, Yoshita K, Nakagaw H, et al. Daily dietary taurine intake in Japan. *Adv Exp Med Biol*. 2002;483:137-42. doi:10.1007/0-306-46838-7_13
 32. Bruns H, Watanpour I, Gebhard M, Flechtenmacher C, Galli U, Schulze-Bergkame H, et al. Glycine and taurine equally prevent fatty livers from kupffer cell-dependent injury: An in vivo microscopy study. *Microcirculation*. 2011;18(3):205-13. doi:10.1111/j.1549-8719.2010.00078.x
 33. Pal PB, Pal S, Das J, Sil PC. Modulation of mercury-induced mitochondria-dependent apoptosis by glycine in hepatocytes. *Amino Acids*. 2011;42(5):1669-83. doi:10.1007/s00726-011-0869-3
 34. Heidari R, Ghanbarinejad V, Mohammadi H, Ahmadi A, Ommati MM, Abdoli N, et al. Mitochondria protection as a mechanism underlying the hepatoprotective effects of glycine in cholestatic mice. *Biomed Pharmacother*. 2018;97:1086-95. doi:10.1016/j.biopha.2017.10.166
 35. Weinberg JM, Roeser NF, Davis JA, Venkatachalam MA. Glycine-protected, hypoxic, proximal tubules develop severely compromised energetic function. *Kidney Int*. 1997;52(1):140-51. doi:10.1038/ki.1997.313
 36. Wheeler MD, Rose ML, Yamashima S, Enomoto N, Seabra V, Madrenet J, et al. Dietary glycine blunts lung inflammatory cell influx following acute endotoxin. *Am J Physiol Lung Cell Mol Physiol*. 2000;279(2):L390-8. doi:10.1152/ajplung.2000.279.2.L390
 37. Warnecke G, Schulze B, Steinkamp T, Haverich A, Klima U. Glycine application and right heart function in a porcine heart transplantation model. *Transpl Int*. 2006;19(3):218-24. doi:10.1111/j.1432-2277.2005.0259.x
 38. Sommer S-P, Sommer S, Sinha B, Leyh RG. Glycine preconditioning to ameliorate pulmonary ischemia reperfusion injury in rats. *Interact Cardiovasc Thorac Surg*. 2012;14(5):521-5. doi:10.1093/icvts/ivs008
 39. Carini R, Alchera E, Baldanzi G, Piranda D, Splendore R, Grazia De Cesaris M, et al. Role of p38 map kinase in glycine-induced hepatocyte resistance to hypoxic injury. *J Hepatol*. 2007;46(4):692-9. doi:10.1016/j.jhep.2006.10.014
 40. Shaikh ZA, Tang W. Protection against chronic cadmium toxicity by glycine. *Toxicology*. 1999;132(2-3):139-46. doi:10.1016/s0300-483x(98)00144-9
 41. Ukeda H, Hasegawa Y, Harada Y, Sawamura M. Effect of carnosine and related compounds on the inactivation of human Cu, Zn-superoxide dismutase by modification of fructose and glycolaldehyde. *Biosci, Biotechnol, Biochem*. 2002;66(1):36-43. doi:10.1271/bbb.66.36
 42. Wade AM, Tucker HN. Antioxidant characteristics of L-histidine. *J Nutr Biochem*. 1998;9(6):308-15. doi:10.1016/s0955-2863(98)00022-9
 43. Lee Y-t, Hsu C-c, Lin M-h, Liu K-s, Yin M-c. Histidine and carnosine delay diabetic deterioration in mice and protect human low density lipoprotein against oxidation and glycation. *Eur J Pharmacol*. 2005;513(1-2):145-50. doi:10.1016/j.ejphar.2005.02.010
 44. Farshid AA, Tamaddonfard E, Yahyae F. Effects of histidine and N-acetylcysteine on diclofenac-induced anti-inflammatory response in acute inflammation in rats. *Indian J Exp Biol*. 2010;48(11):1136-42.
 45. El-Batch M, Ibrahim W, Said S. Effect of histidine on autotaxin activity in experimentally induced liver fibrosis. *J Biochem Mol Toxicol*. 2011;25(3):143-50. doi:10.1002/jbt.20370
 46. Farshid AA, Tamaddonfard E, Belasius MS, Hamzeh-Gooshchi N. Histopathological comparison of the effects of histidine and ketotifen in a rat model of colitis. *Bull Vet Inst Pulawy*. 2009;53(4):795-800.
 47. Bessems M, Hart NA, Tolba R, Doorschodt BM, Leuvenink HG, Ploeg RJ, et al. The isolated perfused rat liver: standardization of a time-honoured model. *Lab Anim*. 2006;40(3):236-46. doi:10.1258/00236770677611460
 48. Ferrigno A, Richelmi P, Vairetti M. Troubleshooting and improving the mouse and rat isolated perfused liver preparation. *J Pharmacol Toxicol Methods*. 2013;67(2):107-14. doi:10.1016/j.vascn.2012.10.001
 49. Heidari R, Sadeghi N, Azarpira N, Niknahad H. Sulfasalazine-induced hepatic injury in an ex vivo model of isolated perfused rat liver and the protective role of taurine. *Pharm Sci*. 2015;21(4):211-9. doi:10.15171/ps.2015.39
 50. Jamshidzadeh A, Heidari R, Golzar T, Derakhshanfar A. Effect of Eisenia foetida extract against cisplatin-induced kidney injury in rats. *J Diet Suppl*. 2016;13(5):551-9. doi:10.3109/19390211.2015.1124163
 51. Heidari R, Niknahad H, Jamshidzadeh A, Eghbal MA, Abdoli N. An overview on the proposed mechanisms of antithyroid drugs-induced liver injury. *Adv Pharm Bull*. 2015;5(1):1-11. doi: 10.5681/apb.2015.001
 52. Moezi L, Heidari R, Amirghofran Z, Nekooiean AA, Monabati A, Dehpour AR. Enhanced anti-ulcer effect

- of pioglitazone on gastric ulcers in cirrhotic rats: The role of nitric oxide and IL-1b. *Pharmacol Rep.* 2013;65(1):134-43. doi:10.1016/s1734-1140(13) 709 71-x
53. Sedlak J, Lindsay R. Estimation of Total, Protein-Bound, and Nonprotein Sulfhydryl Groups in Tissue with Ellman's Reagent. *Anal Biochem.* 1968;25:192-205. doi:10.1016/0003-2697(68)90092-4
54. Heidari R, Babaei H, Roshangar L, Eghbal MA. Effects of enzyme induction and/or glutathione depletion on methimazole-induced hepatotoxicity in mice and the protective role of N-acetylcysteine. *Adv Pharm Bull.* 2014;4(1):21-8. doi:10.5681/apb.2014.004
55. Heidari R, Taheri V, Rahimi HR, Shirazi Yeganeh B, Niknahad H, Najibi A. Sulfasalazine-induced renal injury in rats and the protective role of thiol-reductants. *Ren Fail.* 2015;38(1):137-41. doi:10.3109/0886022x.2015.1096731
56. Uchiyama M, Mihara M. Determination of malonaldehyde precursor in tissues by thiobarbituric acid test. *Anal Biochem.* 1978;86(1):271-8. doi:10.1016/0003-2697(78)90342-1
57. Jamshidzadeh A, Heidari R, Razmjou M, Karimi F, Moein MR, Farshad O, et al. An in vivo and in vitro investigation on hepatoprotective effects of Pimpinella anisum seed essential oil and extracts against carbon tetrachloride-induced toxicity. *Iran J Bas Med Sci.* 2015;18(2):205-11.
58. Shao A, Hathcock JN. Risk assessment for the amino acids taurine, l-glutamine and l-arginine. *Regul Toxicol Pharmacol.* 2008;50(3):376-99. doi:10.1016/j.yrtph.2008.01.004
59. Yu Y-R, NI X-Q, Huang J, Zhu Y-H, Qi Y-F. Taurine drinking ameliorates hepatic granuloma and fibrosis in mice infected with *Schistosoma japonicum*. *Int J Parasitol Drugs Drug Resis.* 2016;6(1):35-43. doi:10.1016/j.ijpddr.2016.01.003
60. Suárez LM, Muñoz M-D, Martín del Río R, Solís JM. Taurine content in different brain structures during ageing: effect on hippocampal synaptic plasticity. *Amino Acids.* 2016;48(5):1199-1208. doi:10.1007/s00726-015-2155-2
61. Schuller-Levis GB, Park E. Taurine: new implications for an old amino acid. *FEMS Microbiol Lett.* 2003;226(2):195-202. doi:10.1016/s0378-1097(03)00611-6
62. Zhang Z, Liu D, Yi B, LIAO Z, TANG L, YIN D, et al. Taurine supplementation reduces oxidative stress and protects the liver in an iron-overload murine model. *Mol Med Report.* 2014;10(5):2255-62. doi:10.3892/mmr.2014.2544
63. Hansen SH, Andersen ML, Cornett C, Gradinaru R, Grunnet N. A role for taurine in mitochondrial function. *J Biomed Sci.* 2010;17(S1):S23. doi:10.1186/1423-0127-17-s1-s23
64. Doğru-Abbasoğlu S, Kanbağlı O, Balkan J, Cevikbaş U, Aykaç-Toker G, Uysal M. The protective effect of taurine against thioacetamide hepatotoxicity of rats. *Hum Exp Toxicol.* 2001;20(1):23-7. doi:10.1191/096032701673031525
65. You JS, Chang KJ. Taurine protects the liver against lipid peroxidation and membrane disintegration during rat hepatocarcinogenesis. *Adv Exp Med Biol.* 1998;442:105-12. doi:10.1007/978-1-4899-0117-0_14
66. Churchill TA, Green CJ, Fuller BJ. Protective properties of amino acids in liver preservation: effects of glycine and a combination of amino acids on anaerobic metabolism and energetics. *J Hepatol.* 1998;23(6):720-6. doi:10.1016/0168-8278(95)80039-5
67. Mangino MJ, Murphy MK, Grabau GG, Anderson CB. Protective effects of glycine during hypothermic renal ischemia-reperfusion injury. *Am J Physiol Renal Physiol.* 1991;261(5):F841-8. doi:10.1152/ajprenal.1991.261.5.f841
68. Parra-Vizuet J, Camacho-Luis A, Madrigal-Santillan E, Bautista M, Esquivel-Soto J, Esquivel-Chirino C, et al. Hepatoprotective effects of glycine and vitamin E, during the early phase of liver regeneration in the rat. *Afr J Pharm Pharmacol.* 2009;3(8):384-90.
69. Senthilkumar R, Sengottuvelan M, Nalini N. Protective effect of glycine supplementation on the levels of lipid peroxidation and antioxidant enzymes in the erythrocyte of rats with alcohol-induced liver injury. *Cell Biochem Funct.* 2004;22(2):123-8. doi:10.1002/cbf.1062
70. Weinberg JM, Davis JA, Abarzua M, Rajan T. Cytoprotective effects of glycine and glutathione against hypoxic injury to renal tubules. *J Clin Invest.* 1987;80(5):1446-54. doi:10.1172/jci113224
71. Ishizaki-Koizumi S, Sonakaa I, Takeib Y, Ikejimab K, Satob N. The glycine analogue, aminomethanesulfonic acid, inhibits LPS-induced production of TNF- α in isolated rat Kupffer cells and exerts hepatoprotective effects in mice. *Biochem Biophys Res Commun.* 2004;322(2):514-9. doi:10.1016/j.bbrc.2004.07.147
72. Zhong Z, Wheeler MD, Li X, Froh M, Schemmer P, Yin M, et al. L-Glycine: a novel antiinflammatory, immunomodulatory, and cytoprotective agent. *Curr Opin Clin Nutr Metab Care.* 2003;6(2):229-40. doi:10.1097/00075197-200303000-00013
73. Shaikh ZA, Tang W. Protection against chronic cadmium toxicity by glycine. *Toxicology.* 1999;132(2-3):139-46. doi:10.1016/s0300-483x(98)0144-9
74. Ligumsky M, Sestieri M, Okon E, Ginsburg I. Antioxidants inhibit ethanol-induced gastric injury in the rat: Role of manganese, glycine, and carotene. *Scand J Gastroenterol.* 1995;30(9):854-60. doi:10.3109/00365529509101591
75. Senthilkumar R, Viswanathan P, Nalini N. Effect of glycine on oxidative stress in rats with alcohol induced liver injury. *Pharmazie.* 2004;59(1):55-60.

76. Weinberg JM, Roeser NF, Davis JA, Venkatachalam MA. Glycine-protected, hypoxic, proximal tubules develop severely compromised energetic function. *Kidney Int.* 1997;52(1):140-51. doi:10.1038/ki.1997.313
77. D'souza DC, Gil R, Cassello K, Morrissey K, Abi-Saab D, White J, et al. IV glycine and oral D-cycloserine effects on plasma and CSF amino acids in healthy humans. *Biol Psychiatry.* 2000;47(5):450-62. doi:10.1016/s0006-3223(99)00133-x
78. Ohnuma T, Sakai Y, Maeshima H, Hatano T, Hanzawa R, Abe S, et al. Changes in plasma glycine, l-serine, and d-serine levels in patients with schizophrenia as their clinical symptoms improve: Results from the Juntendo University Schizophrenia Projects (JUSP). *Prog Neuro-Psychopharmacol Biol Psychiatry.* 2008;32(8):1905-12. doi:10.1016/j.pnpb.2008.07.022
79. Lee JW, Miyawaki H, Bobst EV, Hester JD, Ashraf M, Bobst AM. Improved functional recovery of ischemic rat hearts due to singlet oxygen scavengers histidine and carnosine. *J Mol Cell Cardiol.* 1999;31(1):113-21. doi:10.1006/jmcc.1998.0850
80. McLaren AJ, Friend PJ. Trends in organ preservation. *Transplant Int.* 2003;16(10):701-8. doi:10.1007/s00147-003-0659-2