

## The efficacy of Epley manoeuver in the treatment of posterior canal paroxysmal positional vertigo

Gandomi B. MD<sup>1</sup>, Koochak Alavi K. MD<sup>2</sup>,  
Niknejad N. MD<sup>3</sup>, Cho hedri A. MD<sup>4</sup>

<sup>1</sup>Assistant professor of otorhinolaryngology-Shiraz University of Medical sciences,  
<sup>2</sup>Assistant professor of otorhinolaryngology-Semnan University of Medical Sciences,  
<sup>3</sup>Otorhinolaryngologist, <sup>4</sup>Assistant Professor of Anesthesiology-Shiraz University of Medical Sciences, Shiraz, Iran

### Abstract

**Introduction:** Benign paroxysmal positional vertigo is the most common peripheral vestibular disorder. Canalith repositioning manoeuvres are an established method for treatment of this disorder but efficacy of these maneuvers, including Epley canalith repositioning manoeuver are reported differently in various studies. In this study the efficacy of the Epley canalith repositioning manoeuver has been evaluated in 43 patients.

**Materials and Methods:** 43 patients with a history and physical examination consistent with posterior canal benign paroxysmal positional vertigo were studied. Patients were treated with a modified Epley canalith repositioning manoeuver. Patients were provided with a preprinted diary in which they had to circle the answers most relevant to their symptoms for 7 days after the manoeuver. Patients were reevaluated at one week after the manoeuver, The Hallpike manoeuver was performed at this time to corroborate the response to therapy.

**Results:** The mean duration of the BPPV before treatment was 7 weeks. A resolution of vertigo as a result of the manoeuver was obtained during the first 24 hours in 59% of the patients after one canalith repositioning manoeuver. 20% of patients had a resolution of vertigo during the first week however it is not evidently possible to conclude that these patients definitely benefited from the canalith repositioning manoeuver. In 21% of the patients vertigo persisted after the first week. Residual symptoms of lightheadedness, imbalance or both, were frequent (55% of cases) but rarely required any intervention.

**Conclusions:** Epley canalith repositioning manoeuver resulted in immediate resolution of vertigo in 59% of our cases after one treatment. This manoeuver is safe and requires no special equipment or investigations; and it should be regarded as the treatment of choice for BPPV.

**Keywords:** Benign paroxysmal positional vertigo, Epley manoeuver, Treatment, Efficacy

### Introduction

**B**enign paroxysmal positional vertigo (BPPV) is the most common peripheral vestibular disorder (1,2).

In 1962 Schuknecht presented what has become known as cupulolithiasis or heavy cupula theory, which held that the posterior

semicircular canal (PSC) is rendered sensitive to gravity by dense particles attached to or impinging on its cupula (3).

Today there is general recognition that the majority of cases result from free-floating debris within the posterior semicircular canal (4,5).

Gandomi B, MD

Address: Department of Otolaryngology, Khalili Hospital, Shiraz

Tell fax: 0711 6279372 Email: Behroozgandomi@yahoo.com

Acceptation date: 83/5/3 Confirmation date: 84/1/24

This theory of canalithiasis has largely supplanted Schuknecht's model of cupulolithiasis. Variants of BPPV have been recognized, including diseases affecting the superior and horizontal semicircular canals (6,7).

Treatment strategies specifically designed based on the pathophysiology of the disorder have been developed and have supplanted ineffective or overly aggressive therapies. Specifically, single treatment strategies such as Epley canalith repositioning manoeuver and the Semont libratory manoeuver have become the standard care for patients with active BPPV(8).

For rare patients with intractable disease, posterior semicircular canal occlusion has proven to be a safe and effective surgical treatment that provides reproducible results in the hands of various surgeons (9).

Despite the fact that overwhelming evidence supports the use of single treatment positional manoeuvres in the treatment of BPPV, a number of questions persists pertaining to the efficacy of these manoeuvres. Questions have been raised pertaining to whether some of the beneficial results attributed to these manoeuvres may result from spontaneous recovery and not from the specific effects of the kind of treatments (10,11).

If the resolution of symptoms is related to the effects of the manoeuver and not to the spontaneous recovery from the disorder, the recovery from BPPV after the performance of a positional manoeuver should be virtually immediate. This prospective study of 43 patients with BPPV was designed to evaluate the efficacy of the Epley canalith repositioning manoeuver in the treatment of posterior canal benign paroxysmal positional vertigo.

### Materials and Methods

Sixty-one patients with BPPV referred to the outpatient clinic of the Ear, Nose and Throat Department of the Shiraz University

of Medical Sciences between May 2000 and December 2003. Entry into the study required the presence of active BPPV confirmed by a positive finding on Dix-Hallpike manoeuver that reproduced the patient's symptoms and demonstrated characteristic nystagmus. Four patients with signs of horizontal canal positional vertigo and one with anterior canal involvement were excluded from the study.

Thirteen one patients were also lost to follow up, so 43 patients with history and physical examination typical of posterior canal benign positional vertigo completed the study.

Outcome measures included the results of a daily diary designed to identify the precise time when the vertigo resolved and whether the patients had residual symptoms of lightheadedness and imbalance. The results of a Dix-Hallpike manoeuver that was performed 7 days after the treatment were also used to determine therapeutic efficacy.

The patients were treated with an Epley manoeuver without mastoid oscillation. Specifically, the patient was placed in the supine position with the neck slightly extended and the head turned so that the affected ear was facing the floor.

The patient's head was then turned so that the contralateral ear was facing the floor. The patient's body was then rotated so that the head completed a further 90 degree turn. Each position was maintained for 2 minutes. Neck extension was maintained throughout the steps of the manoeuver.

Eye movements were directly visualized without the aid of Frenzel glasses. If the direction of the nystagmus reversed during the manoeuver, the procedure was halted and repeated.

When the patient was brought back to the sitting position, he or she was instructed to tuck his or her chin to the shoulder to prevent the conversion to a horizontal canal BPPV.

The manoeuver was performed only one time per session. Because of the known fatigability of BPPV, it was not thought to be useful to repeat the manoeuver until the nystagmus was no longer visualized. The patients were not instructed to maintain any restrictions on head movement or position after the performance of the maneuvers.

Each patient was given a preprinted diary to maintain on a daily basis for 7 consecutive days. The patient was required to circle the entry that pertained to his or her symptoms on that particular day. The five possible answers were the following:

- 1) My vertigo did not change.
- 2) My vertigo was improved but not gone.
- 3) I had no vertigo.
- 4) I was lightheaded and/or imbalanced;
- 5) I felt fine.

The first three answers pertained to the presence or absence of vertigo. The fourth answer pertained to the presence or absence of any residual symptoms.

Patients were instructed that they could circle more than one answer. For example, their vertigo may have resolved (answer 3) but they still may be having residual symptoms (answer 4).

The patients were instructed to return to the office with the diary 7 days after the performance of the manoeuver, and their condition was evaluated with the Dix-Hallpike manoeuver.

A negative manoeuver was needed to confirm response to the canalith repositioning manoeuver. Other data that were recorded pertained to the patient's age and sex, the duration of symptoms and the presence or absence of any predisposing factors for BPPV.

## Results

Forty-Three patients with posterior canal benign paroxysmal positional vertigo were treated with Epley manoeuver. The number of female patients was 2.4 times that of the male patients.

The mean duration of symptoms was approximately 7 weeks. The age distribution of patients is given in figure 1.

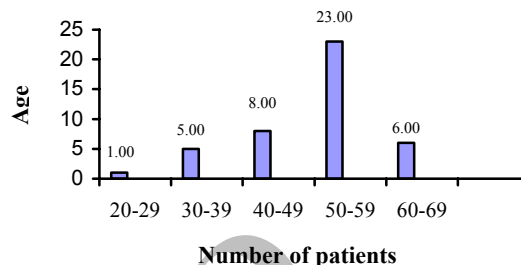


Fig 1: Age distribution of the patients

The most common age of presentation was 50-59 years. The disorder was relatively uncommon in patients less than 30 years old. Predisposing factors are detailed in table 1.

Table 1: Predisposing factors

Predisposing factor	Number (Percentage)
Previous history of benign paroxysmal vertigo	8 (19%)
Head trauma	4 (9%)
Vestibular neuronitis/labyrinthitis	1
Otosclerosis	2
Prolonged bed rest	1
Idiopathic SNHL	1
Meniere's disease	2
Chronic otitis media/mastoidectomy	2
Chemoradiation to the head and neck	1

SNHL= Sensorineural hearing loss

Approximately 19% of patients had a history of BPPV. Other predisposing factors included head trauma, vestibular neuronitis or labyrinthitis and otosclerosis. Two patients had meniere's disease. The therapeutic response to the Epley canalith repositioning manoeuver is detailed in figure 2.

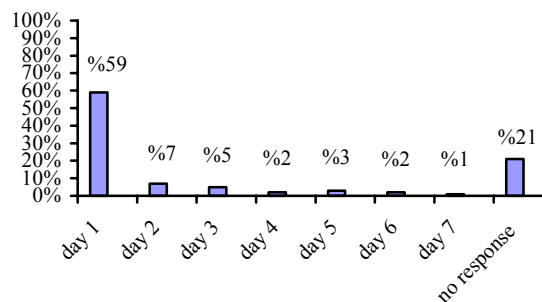


Fig 2: Therapeutic results after the first canalith repositioning manoeuver

Fifty nine percent of cases had a complete resolution of vertigo within the first day after treatment. 79 percent of cases had a resolution of vertigo within the first week of treatment. In 9 cases (21%) vertigo persisted after one week follow-up period.

Residual symptoms of lightheadedness or imbalance or both were common in this patient population. 55% of cases manifested these symptoms after a successful resolution of vertigo but these symptoms were generally not disabling and no intervention was needed.

### Discussion

The hypothesis of this study was that if the Epley canalith repositioning manoeuver is successful in alleviating BPPV, its effect should be virtually immediate. The rationale for this hypothesis was that ridding the semicircular canal of the canaliths should provide immediate relief from vertigo and this study attempted to determine the precise time of resolution of the vertigo.

The study also hypothesizes that a portion of patients in whom the true vertigo has resolved will complain of residual symptoms of lightheadedness and/or imbalance so it was attempted to differentiate the symptom of vertigo from the residual symptoms of lightheadedness and imbalance that may exist after resolution of the vertigo(3).

The results of this study reveal that 59% of cases had a resolution of their vertigo within 24 hours of the performance of the canalith repositioning manoeuver.

Given that most of these patients had BPPV for a long time (mean 7 weeks) it is reasonable to conclude that the canalith repositioning manoeuver was responsible for the resolution of their symptoms.

An additional 20% of patients had a resolution of their vertigo within the first week after the treatment. The role of the canalith repositioning manoeuver in their recovery must be considered questionable.

It is possible to say that the manoeuver may have loosened the canaliths and allowed them ultimately to pass from the semicircular canal.

Conversely, it is possible that the resolution in these cases may have resulted from spontaneous recovery. 21% of the patients did not report any significant improvement of their vertigo and no additional manoeuver was performed for these patients. Results of this study are in keeping with another similar study performed by Ruckenstein (12) who also reported the timing of recovery on a daily basis in 86 patients table 2.

**Table 2:** Therapeutic Results of Various Studies

Author	NO	Efficacy (No.of Rxs)	Efficacy (No of Rxs)	Follow-up (Wk)	Mastoid oscillation	Post- manoeuver restrictions
Ruckenstein <sup>12</sup>	95	70%(1)	74%(2)	2	yes	no
Epley <sup>8</sup>	30	80%(1)	97%(2)	1	Yes	Yes
Parnes and Price-Jones <sup>13</sup>	26	79%(1)		3-4	No	Yes
Herdman et al <sup>14</sup>	30	90%(1)		2	No	Yes
Welling and Barnes <sup>15</sup>	27	84%(1)		1	No	Yes
Lynn <sup>16</sup>	18	89%		4	No	Yes
Massoud et al <sup>17</sup>	23	96%		1	No	No
Blakely <sup>10</sup>	16	44%		?	No	No

The only difference between Ruckenstein study and ours is that he used mastoid vibration in 86% of his patients which we did not use.

In his study no selection was done with regard to type of canal involved while we selected patients with only posterior canal BPPV for study. No post manoeuver restriction of head position was used in either of these two studies. Results of several other studies are shown in table 2.

It seems that the use of a diary is the only way to obtain results on a daily basis (2) but as pointed out by Lynn et al (16) a diary may be subject to error of omission and they emphasized the need to corroborate the results obtained in the diary with objective findings on physical examination. Thus like Ruckenstein, this study required a negative finding on Dix Hallpike manoeuver at 7day follow-up as corroboration of the results recorded in the diary. Factors predisposing the patients to BPPV was similar to other studies(12). The most common predisposing factor was head trauma, found in 9% of our patients (table 1).

The patients in our study reported a high incidence of previous episodes of BPPV (19%). These results are consistent with the concept that BPPV is a recurrent condition as other studies also report a 15% recurrence rate per year (12). The age range and the female to male ratio of patients in this study is consistent with those reported in other major studies (12).

A significant number of patients (55%) reported subjective sensations of lightheadedness and imbalance after resolution of their vertigo. The origin of these symptoms are unclear (2). Possible explanations may include the persistence of small caliber otoliths that can elicit minor symptoms but not vertigo.

Another possibility is that the presence of otoliths causes some damage to the inner ear, for which adaptation must take place.

Another possible explanation is that the presence of active BPPV causes some recalibration at the level of central nervous system that must be readjusted after the canalolithiasis (2). Whatever the origin, these residual symptoms are short-lived and rarely require any specific therapy.

### Conclusion

In this study, the Epley's canalith repositioning manoeuver resulted in an immediate resolution of symptoms in 59% of cases with posterior canal benign paroxysmal positional vertigo after a single manoeuver.

Another 20% of our cases may have benefited from the manoeuver. Only 21% of cases manifested BPPV that persisted after one Epley canalith repositioning manoeuver. Post manoeuver restrictions of head position do not appear to offer any advantage in therapeutic efficacy. Residual symptoms of lightheadedness and imbalance are common but usually resolve soon after resolution of the vertigo and rarely require any intervention.

### References

- 1- Bath AP, Walsh RM, Ranalli P, et al. Experience from a multidisciplinary dizzy clinic. *Am J Otol* 2000; 21: 92-97.
- 2- Nedzelski JM, Barber HO, McIlmoy L. Diagnoses in a dizziness unit. *J Otolaryngol* 1986;15: 101-104.
- 3- Schuknecht HF. Cupulolithiasis. *Arch Otolaryngol* 1969; 90: 765-778.
- 4- Brandt T, Stedden S. Current view of the mechanism of benign paroxysmal positioning vertigo: cupulolithiasis or canalolithiasis?. *J Vestib Res* 1993;3:373-382.
- 5- Hall SF, Ruby RR, McClure JA. The mechanics of benign paroxysmal vertigo. *J Otolaryngol* 1979; 8:151-158.
- 6- McClure JA. Horizontal canal BPV. *J Otolaryngol* 1985; 14: 30-35.
- 7- Semont A, Freyss G, Vitte E. Curing the BPPV with a liberatory manoeuver. *Adv Otorhinolaryngol* 1988; 42: 290-293.

- 8- Epley JM. The canalith repositioning procedure for treatment of benign paroxysmal positional vertigo. *Otolaryngol Head Neck Surg* 1992; 107: 399 - 404.
- 9- Parnes LS, McClure JA. Posterior semicircular canal occlusion for intractable benign paroxysmal positional vertigo. *Ann Otol Rhinol Laryngol* 1990; 99: 330-334.
- 10- Blakley BW. A randomized, controlled assessment of the canalith repositioning maneuver. *Otolaryngol Head Neck Surg* 1994; 110: 391-396.
- 11- Smouha EE. Time course of recovery after Epley maneuvers for benign paroxysmal positional vertigo. *Laryngoscope* 1997; 107:187-191.
- 12- Ruckenstein MJ. Therapeutic efficacy of the Epley canalith repositioning maneuver. *Laryngoscope* 2001; 111: 940-945.
- 13- Parnes LS, Price-Jones RG. Particle repositioning maneuver for benign paroxysmal positional vertigo. *Ann Rhinol Laryngol* 1993; 102:325-331.
- 14- Herdman SJ, Tusa RJ, Zee DS, Proctor LR, Mattox DE. Single treatment approaches to benign paroxysmal positional vertigo. *Arch Otolaryngol Head Neck Surg* 1993; 119:450-454.
- 15- Welling DB, Barnes DE. Particle repositioning maneuver for benign paroxysmal positional vertigo. *Laryngoscope* 1994; 104:946-949.
- 16- Lynn S, Pool A, Rose D, Brey R, Suman V. Randomized trial of the canalith repositioning procedure. *Otolaryngol Head Neck Surg* 1995; 113: 712-720.
- 17- Massoud EA, Ireland DJ. Post-treatment instructions in the nonsurgical management of benign paroxysmal positional vertigo. *J Otolaryngology* 1996; 25:121-125.
- 18- Blatt PJ, Georakakis GA, Herdman SJ, Clendaniel RA, Tusa RJ. The effect of canalith repositioning maneuver on resolving postural instability in patients with benign paroxysmal positional vertigo. *Am J Otol* 2000; 21: 356-368.

\*\*\*\*\*

### خلاصه

## تأثیر مانور Epley در درمان سرگیجه وضعیتی خوش خیم کانال خلفی

دکتر بهروز گندمی، دکتر کاوه کوچک علوی، دکتر نیکا نیک نژاد، دکتر عبدولحمید چوهدری

**مقدمه:** سرگیجه خوش خیم وضعیتی از شایعترین انواع سرگیجه های محیطی می باشد. مانورهای فیزیکی (canalith repositioning) از مهمترین روش های شناخته شده در درمان این بیماری می باشند ولی میزان موثر بودن (efficacy) این مانورها از جمله مانور Epley در مطالعات مختلف، متفاوت ذکر شده است. در این مطالعه میزان تاثیر این مانور بر روی ۴۳ بیمار بررسی شده است.

**مواد و روش ها:** این مطالعه بر روی ۴۳ بیمار که شرح حال و معاینه بالینی آنها منطبق بر تشخیص بیماری سرگیجه خوش خیم وضعیتی بوده، انجام شده است. جهت این بیماران مانور Epley انجام و از آنها خواسته می شد که پرسشنامه ویژه ای را روزانه تا هفت روز پر کنند. بیماران پس از هفت روز مجددا معاینه، پرسشنامه ها جمع آوری و مانور Epley مجددا جهت تعیین پاسخ یا عدم پاسخ به درمان انجام می شد.

**نتایج:** متوسط دوره بیماری قبل از درمان ۷ هفته بود. ۵۹٪ بیماران به دنبال یک بار انجام مانور بهبود کامل سرگیجه را در ۲۴ ساعت اول گزارش کردند. در ۲۰٪ بیماران بهبود سرگیجه در طی یک هفته بعد از انجام مانور مشاهده شد ولی نتوانستیم نتیجه بگیریم که این بهبودی تا چه حد با انجام این مانور ارتباط داشته است. در ۲۱٪ بیماران سرگیجه تا بعد از هفته اول ادامه داشت. علائم باقی مانده شامل احساس سبکی در سر، عدم تعادل در ۵۵٪ بیماران دیده شد ولی به علت خفیف بودن علائم نیاز به درمان پیدا نکردند.

**نتیجه گیری:** یک بار انجام مانور Epley در ۵۹٪ از بیماران ما سبب از بین رفتن سرگیجه شد. این مانور ساده بوده و نیاز به تجهیزات خاصی ندارد و می تواند به عنوان درمان انتخابی بیماری سرگیجه خوش خیم وضعیتی در نظر گرفته شود.

**واژه های کلیدی:** سرگیجه خوش خیم وضعیتی، مانور Epley، درمان، میزان تاثیر