

# A Simple and Large Scale Performing Protocol for the Detection of *Sarcocystis* in Muscles of Some Small Mammals

\*EB Kia<sup>1</sup>

<sup>1</sup>Dept. of Medical Parasitology and Mycology, School of Public Health, Tehran University of Medical Sciences, Tehran, Iran.

---

## Abstract

A simple special protocol using Semichon's acetic carmine stain was applied for examination of muscles of some small mammals, naturally infected with *Sarcocystis* spp. using this method, infected muscles fibers with *Sarcocystis* could easily be differentiated from muscle tissues. This method can be applied for screening of infected muscles with *Sarcocystis* cysts on large number of samples for epidemiological studies, and in slaughterhouses on frozen samples and formalin preserved samples as well as fresh tissues.

**Keywords:** *Sarcocystis*, Muscle, Staining, Small mammals

---

## Introduction

The genus *Sarcocystis* Lankester, 1882 is one of the largest genera of the protozoan phylum Apicomplexa (1). It is composed of about 130 species of heterogeneous cyst-forming coccidian with differences in life cycle and pathogenicity (2). Distribution of this genus is worldwide in man and many species of animals. *Sarcocystis* spp are obligate two-host parasites, generally alternating between a herbivorous intermediate host and a carnivorous definitive host. Man is the definitive host for *S. hominis* and *S. suis hominis* with cattle and pigs as intermediate hosts for these species, respectively (3). Until now, several problems complicated the diagnosis of sarcocystiosis (2). Postmortem examination of tissues is usually performed by histological sections or squash preparations. However, these methods lack sensitivity due to examination of only a small section of muscle tissue. Moreover, squash preparation method is not applicable on frozen or preserved samples. In this study a simple protocol was found to be satisfactory for staining and detection of *Sarcocystis* cysts in infected muscles at the level of genus.

## Materials and Methods

The specimens examined in this study were part of the small mammals collections of the "Institute national de Recherche Agronomique" (IRNA) and of the Forestry Commission of Britain (FCB). They included 23 short-tailed vole, *Microtus agrestis* and 78 common shrew *Sorex araneus*, preserved in 10% formalin (IRNA collection), and 269 *M. agrestis* and 105 *S. araneus*

frozen in -20°C (FBC collection). Laboratory works were performed in Liverpool School of Tropical Medicine.

**Preparation of materials.** Formalin preserved specimens were transferred to tap water to reduce the exposure to formalin fumes. Then they were dissected and their skeleton and heart muscles were removed. Frozen specimens were removed from the freezer, a few hours before dissection, and placed at room temperature to defrost. Then they were dissected and their skeleton and heart muscles were removed.

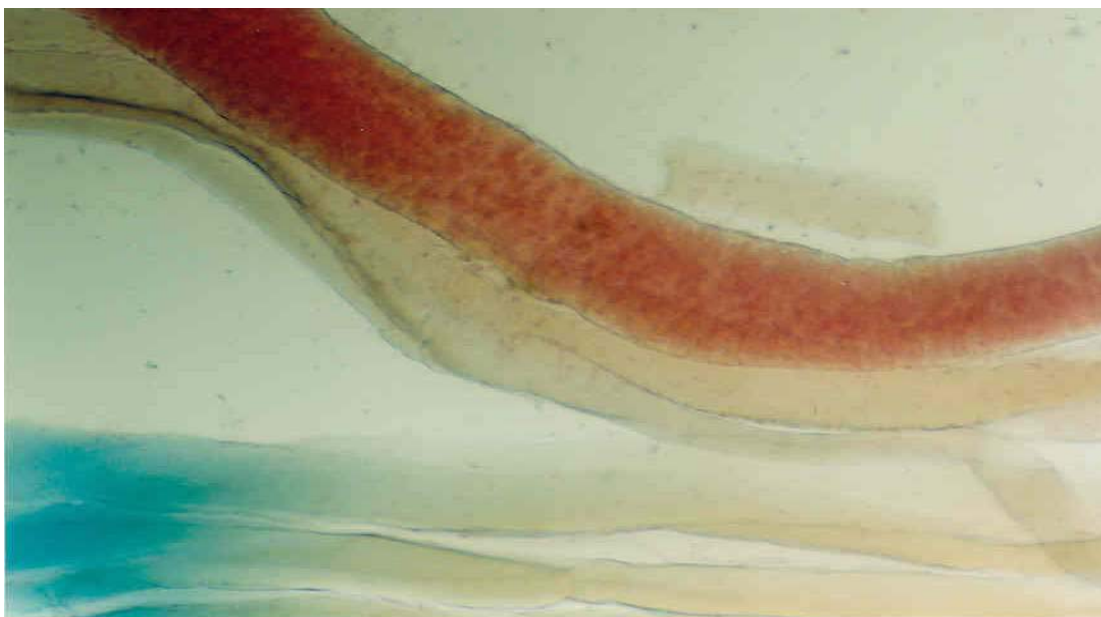
**Semichon's Acetic Carmine Staining.** Semichon's acetic carmine stain was prepared by adding 5 g carmine to 200 ml of 50% acetic acid; boiling in water bath for 15 minutes prior to filtering the stain. Using scalpel and forceps muscles were sliced manually (about 2 mm thick) and placed in undiluted Semichon's acetic carmine stain overnight. Then the specimens washed in distilled water for a few minutes. Afterwards, they transferred to 1% hydrochlorine acid in 70% ethanol alcohol to decolorize, leaving until detail could be seen. Then specimens transferred to glycerin until clear. Later, muscle slices were squashed between glass slides and plastic cover slips prior to examination under light microscope (power 10 & 40).

**Histological techniques.** For the diagnosis of species of *Sarcocystis*, infected muscle samples were processed for histological sectioning. Using a Shandon Hyper-cut microtom, 5 m sections were prepared from original fixed muscle tissues in 10% formalin or 70% ethanol. Then, sections were stained with Ehrlich's haematoxylin and eosin and examined under a light microscope.

## Results

Examination of muscles, after Semichon's acetic carmine staining revealed the infectivity of 17 *M.agrestis* and 12 *S.araneus* with *Sarcocystis* spp.. In all infected cases, *Sarcocystis* cysts were detected only in skeletal muscles. Using this method, *Sarcocystis* cysts take deep pink

colour and can easily be distinguished from the muscles tissues which appear pale pink (Fig.1). Species identification was achieved by histological sectioning of infected muscles.



**Fig. 1:** Semichon's acetic carmine staining of striated muscles of *M.agrestis* infected with *S.putorii*. Arrow indicates the *Sarcocystis* cyst which appears dark pink against pale pink colour of muscle.

## Discussion

*Sarcocystis* is one of the most prevalent parasites of livestock, and it also infects man. In addition to economic loss due to condemnation of infected carcasses (4), there is potential public health importance due to consumption of under-cooked meat of infected cattle and pigs (3). Current research on *Sarcocystis* is focused on the diagnosis of acute sarcocystiosis and sarcosporidial abortion, on the development of new methods to differentiate species and on the influence of chronic infection on growth rates and meat quality of slaughter animals (5). However, the diagnosis of sarcocystiosis especially in epidemiological surveys and large scale sampling is problematic. Squash preparation is limited since it is not applicable on frozen or preserved samples. The most conventional method, for the detection of *Sarcocystis* cysts, is histological sectioning of muscles, as its application in recent investigations carried out by DeLucia et al (6) on banded armadillos, Ewing et al. (7) on stranded Atlantic white-sided dolphins, Huong (8) on water buffaloes, Ono & Ohsumi (9) on beef, Baird et al. (10) on Virginia opossum and Mahammed et al. (11) on

gazelle. Nevertheless, the application of this method on large scale sampling is time consuming. Therefore, in this study in order to examine large samples of muscles and more tissues in each sample, skeletal and heart muscles of 319 *M.agrestis* and 183 *S.araneus* were stained by a special protocol using Semichon's acetic carmine stain. Results indicated that, by this protocol much more tissues can be examined than by histological sectioning or squash preparations. Moreover, it is applicable on either frozen or preserved samples as well as fresh ones. After detecting the infected muscles and their identification at the level of genus, determination of the species of *Sarcocystis* was achieved following conventional histological sectioning of infected muscles.

Further investigations are necessary to evaluate the sensitivity of this method compared to other methods in the detection of infection. The advantage of this method is its usefulness for rapid screening of infected muscles with genus *Sarcocystis* on large scale sampling and in epidemiological studies. However, determination of the species of *Sarcocystis* needs application of other

complementary methods including histological sectioning or electron microscopy.

### Acknowledgements

Thanks are due to Pof. P.Delattre from the "Institute National de Recherche Agronomique" (IRNA) and rest of his team and to Dr. Steve J. Petty from the Forestry Commission of Britain (FCB) for providing part of their small mammals collections and also to prof. R.W. Ashford from Liverpool School of Tropical Medicine for his helpful advise.

### References

1. Levine ND (1970). Taxonomy of *Sarcocystis* (protozoa, Apicomplexa) species. *J Parasitol*, 72: 372-82.
2. Tenter AM (1995). Current research on *Sarcocystis* species of domestic animals. *Int J Parasitol*, 25: 1311- 30.
3. Dubey JP, Speer CA, Fayer R (1989). *Sarcocystis of animals and man*. CRC Press. Boca Raton.
4. Thornton H (1972). Sarcosporidiosis: a review. *Trop Anim Hlth Prod*, 4, 54-7.
5. Rommel M (1989). Recent advances in the knowledge of the biology of the cyst-forming coccidian. *Angew Parasitol*, 30: 173-83.
6. DeLucia PM, Cheadle MA, Greinier EC (2002). Prevalence of *Sarcocystis* sarcocysts in nine-banded armadillos (*Dasyypus novemcinctus*) from Florida. *Vet Parasitol*, 103 (3): 203-5.
7. Ewing R, Zaias J, Stamper MA, Bossart GD, Dubey JP (2002). Prevalence of *Sarcocystis* sp in stranded Atlantic white-sided dolphins (*Lagenorhynchus acutus*). *J Wildl Dis*, 38 (2):291-96.
8. Huong Lam TT (1999). Prevalence of *Sarcocystis* spp in water buffaloes in Vietnam. *Vet Parasitol*, 86(1): 33-9.
9. Ono M, Ohsumi T (1999). Prevalence of *Sarcocystis* spp cysts in Japanese and imported beef (Lion: *Musculus longissimus*). *Parasitol Int*, 48 (1): 91-4.
10. Barid KL, Cheadle MA, Greiner EC (2002). Prevalence and site specificity of *Sarcocystis greineri* sarcocysts in Virginia opossum (*Didelphis virginiana*) in Florida. *J Parasitol*, 88 (3): 624-25.
11. Mohammed OB, Davies AJ, Hussein HS, Daszak P (2000). *Sarcocystis* infections in gazelles at the king Khalid Wildlife Research Center, Saudi Arabia. *Vet Rec*, 146 (8): 218-21.

Archive of SJI