

Dermatoglyphic Observations in an Iranian Girl Affected with Congenital Cutis Laxa (Autosomal Recessive)

***H Pour-Jafari¹, A Sarihi², M Hashemzadeh³, DD Farhud³**

¹*Unit. of Genetic, School of Medicine, HUMS, Hamadan, Iran*

²*Dept. of Physiology, School of Medicine, HUMS, Hamadan, Iran*

³*Dept. of Human Genetic, School of Public Health, TUMS, Tehran, Iran*

Abstract

The aim of this work was to determine the finger patterns, Finger Ridge Count (FRC), Total Finger Ridge Count (TFRC), and Asymmetry of Finger Ridge Count (AFRC) of an Iranian girl (aged 13 years) affected with congenital cutis laxa (CCL). The fingerprints of the first phalanx of both hands were taken by using the standard method (stamp ink). The fingerprints were classified according to the Galton nomenclature. The patterns of palm creases were also studied. Besides, the ridges of fingerprints of all ten fingers were counted, then employing the related formulas, the FRC, TFRC and AFRC were calculated. Results showed that the finger patterns of all ten fingers were radial loop; the major creases of the palms existed but their sizes were not normal. TFRC, which is the sum of all ten FRCs, was 77 ("low"), and AFRC was 10.344, more than that of her normal sister, that was 7.280. It is concluded that in CCL, the TFRC and symmetry of the fingertips ridges count may decrease; also palm pattern may be unusual.

Keywords: *Cutis Laxa, Dermatoglyphics, Skin disease, Iran*

Introduction

Dermatoglyphics is the study of the patterns of the ridged skin of the digits, palms and soles. They are important in medical genetics chiefly because of their diagnostic usefulness in some dysmorphic syndromes (1). Today the diagnostic roles of these patterns are clear especially in chromosomal abnormalities (2-6). In nearly all chromosomal disorders the dermatoglyphic patterns are unusual. In addition, unusual dermatoglyphics have been described in a variety of the skin disorders (7-10), including several cases in which there were no reason to expect dysmorphism. Our research group recently has worked on a case of cutis laxa. Based on clinical manifestations and laboratory findings as well as family history and pedigree study, we found that our case was affected with CCL (congenital cutis laxa) (11); its mode of inheritance also was autosomal recessive (12). Because in CCL, the basic defect is a genetic-based connective tissue abnormality that leads to skin laxis in addition to other difficulties, we tried to study patterns of her digits and palm skin creases to show if there was any abnormality which may had occurred in presence of the disease. Moreover, such studies may lead us to the onset of the abnormality during fetal life.

Materials and Methods

The case in this study was a 13-year-old Iranian girl with congenital cutis laxa (autosomal recessive type). In other reports it was stated: "based to a complete clinical and family studies and skin biopsy the case in this study was a case of congenital cutis laxa", the results are presented in detail (11, 12). Fingerprints of

first phalanx of both hands of her and her normal 6-year-old sister were examined using the standard method (stamp ink), and classified according to the Galton classification (13). In a qualitative study, besides the pattern of fingerprints, the palm patterns were examined too. For this reason the Bhanu classification (14) was employed. Bhanu has classified the palmar creases according to their locations. Some investigators use this system for identification the palmar creases (15, 16). In a quantitative study of the fingerprints, the case under study and her and her normal sister's FRC, TFRC and AFRC were determined. The FRC is finger ridge count. Counting the ridges is based on a line drawn from the center of a loop to a marking known as the triradus. This is a formation formed by the forking of a ridge so that a Y-shape state can be recognized. The ridge count is simply the number of ridges, which the line from the center of the loop crosses (Figure 1). Counts totaled for all fingers, called total finger ridge count (TFRC) (13), were determined as well. Besides, the Asymmetry of finger Ridge Count (AFRC) was calculated based on the following formula (18): AFRC =

$$\sqrt{A^2} = \sqrt{\sum_{i=1}^5 (R_i - L_i)^2} \quad \text{while } \sqrt{A^2} = \text{Asymmetry of}$$

finger ridge count, R_i = Ridge count of the right hand

and L_i = Ridge count of the left hand. Type of fingertip ridges, TFRC and AFRC of her normal sister were calculated, and were compared with those of the case.

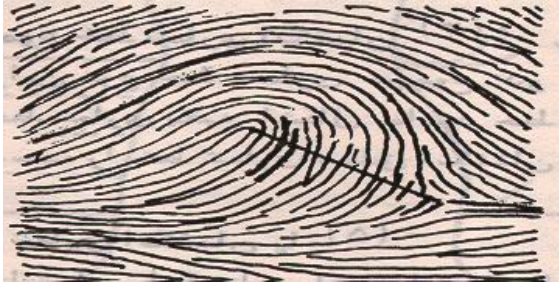

Fig.1: A typical figure showing how to count the ridges of the loop shaped fingerprints (13).

Results

a. Qualitative study. A-1: There was a triradii in each of the fingerprints which meant the major class was "loop" in all 10 fingers. A triradius is a point from which three ridge systems course in three different directions, at angles of about 120 degrees. The subclass of all loops was radial, which meant they opened to the radial side of the finger. Figure 2 shows the fingerprints of first phalanx of all 10 fingers of the case. The type of her normal sister fingerprints was radial loop as well. A-2: There are many creases on the palm but most researchers focused on three major

folds: "sub-thumb", "central" and "far from center". In both palms of our case these three major folds were present (Figure 2) but they were unusual in their sizes compared to 13 types which Bhanu explained as normal types (17). The sub-thumb creases in both palms finished in a point about 3 cm from wrist folds. The lower end of this short major crease in right palm fused with lower end of a minor crease, named sub-little finger crease, but in left palm the lower end of sub-thumb fold is 2.5cm from lower end of sub little finger fold. The central crease in right palm was about 6 cm and finished near the sub-little finger crease; whereas the same crease in left palm was shorter, being about 4 cm. The "far from center" crease of the left palm was long and drew from the edge of palm to below finger zone number 2. The same crease in right palm started from edge of palm and divided into two branches in zone between fingers numbers 3 and 4. The upper branch drew toward finger number 2 and was 3 cm in length. The lower branch crossed the central crease and finished near the sub-thumb crease; it was 3.5 cm in length. Palmar pattern of her normal sister was normal; it means that all three folds were present, but longer than those of her affected sister's.

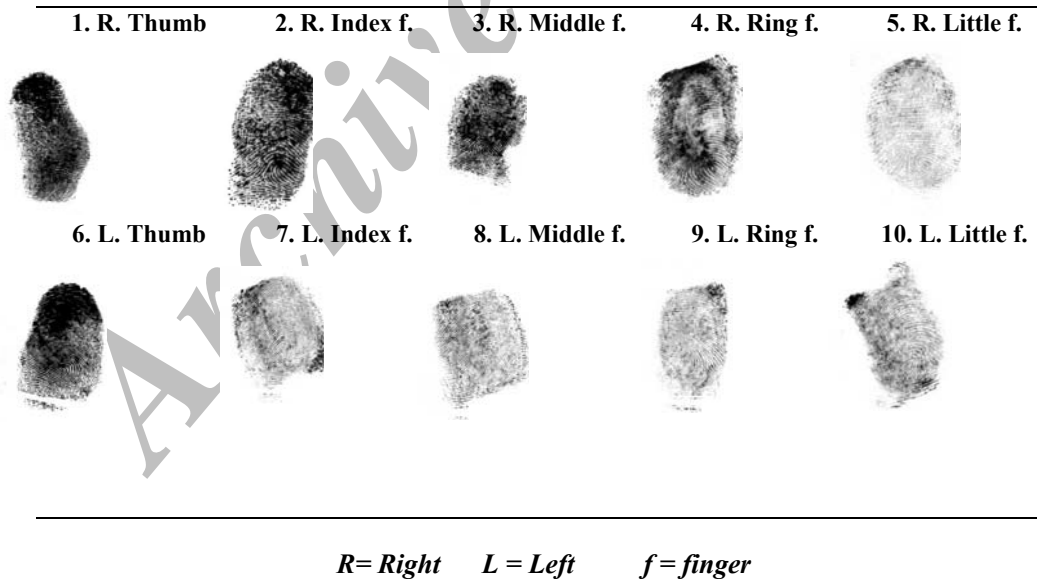


Fig. 2: Prints of first phalanx of ten fingers and palms of a 13-year-old Iranian girl with congenital cutis laxa.

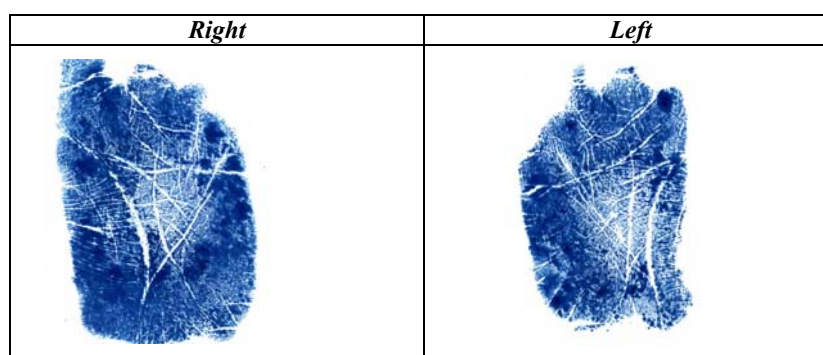


Fig. 2 : continued

b. Quantitative study. B.1. FRCs (finger ridge count) of ten fingers were: Rt = 7, Ri = 6, Rm = 6, Rr = 6, Rs = 6, Lt = 10, Li = 5, Lm = 10, Lt = 15 and Ls = 6, where R = right, L = left, t = thumb, i = index finger, m = middle finger, r = ring finger, and s = small finger. B.2. TFRC (total finger ridge count) of the case, which is the sum of all ten FRCs, in our case was 77, and TFRC of her normal sister was 83. B.3. Asymmetry of finger ridge count of the case was 10.344, and AFRC of her normal sister was 7.280.

Discussion

The case under study was a 13-year-old Iranian girl with CCL autosomal recessive type. All previous (11, 12) and present cases including ours showed loose skin and gave the appearance of premature aging. Review of recent literature did not have any report on dermatoglyphics, thus there was no similar investigation with which to compare. Gross distortion of the patterns can occur in association with any limb malformation of early parental onset. In nearly all the chromosome disorders the dermatoglyphic pattern are unusual, e.g. in Down syndrome (2), Trisomy 18 (3), Trisomy 13 (4), 45, X (5), 5p- (6) etc. This is not surprising, because abnormal karyotypes lead to multiple morphological abnormalities and the dermatoglyphic patterns are influenced by the shape of the underlying structures. The differences described are chiefly in the TRC (which may be either higher or lower than normal in different conditions), in the flexion creases of the palm (often reduced to a single crease), and in the position of the axial triradius (usually distally displaced). It must be emphasized that dermal patterns are highly variable, and none of these dermatoglyphic features is in itself abnormal; however, their different frequencies in patients and controls, and the combination of several different unusual features in a single patient may be distinctive. In other hand, normal patterns in a disorder can lead us to onset of the abnormality during fetal life. In other words, if in a disorder, the fingerprints show unusual pattern, it

means that such a condition was already present, or developing at the time of ridge differentiation. At 10th week the fetal hands bear conspicuous volar pads, as relatively large as a cherry on an adult's fingertips. At about the 13th week the pads regress; meanwhile, the dermal ridge differentiates in the thickening skin (1). The fingerprints in this study were normal (radial loop). The most frequent type of fingerprints is ulnar loop, and radial loop is the less frequent type in normal population of Caucasians (about 1-3 percent in the most fingers). The frequencies of the radial loop in the general population of Iranians (13) and in Hamadanians (18) were 8.5 percent and 16.04 percent, respectively. Different investigations about various cases of a single syndrome have shown that almost all of the patients have a unique pattern; for example, in syndromes characterized by nail dysplasia, the digital patterns are often simple arches (6), which is fairly unusual. The TRC or TFRC (total ridge count or total finger ridge count) is another index which is important in dermatoglyphic studies. In this study, TRC was 77. Another study showed that the TFRC of women from south of Iran was 129.38 (13). TFRC in French women was 121 (19), and in women from Sweden was 120.67 (20), from German 131.40 (21), and from England 126.97 (13). We consider that TFRC in this investigation was low as in affected with trisomy 18 and 13 which are "very low" and "low" respectively (1). The TFRC of our case was lower than her normal sister. Palm creases are responsible for tightly local connecting of skin with its inferior structures. In our case all three major creases were present, but shorter than normal creases. In Holt-Oram Syndrom the sub-thumb crease is absent or short and others are in horizontal positions (6). Individuals with Down's syndrom usually have only one Simian crease (1). Perhaps shortness of the palm creases in our case is a secondary consequence of the basic defect of connective tissue abnormality; nevertheless, this should be proved with other studies. Symmetry is known to be decreased in a variety of disorders of developmental origin, and thus could potentially serve as a risk marker

for disorders with a developmental component (22). The results brightly showed that symmetry of the case at least in ridge counts of fingertips were decreased. In addition, based on the data on dermatoglyphics of the Iranians of African decent, one can estimate that the AFRC in those men was 8.376 (13), which showed that the symmetry in our case was lower than that of Iranian population. Based on the results of present observations it may be concluded that in congenital cutis laxa, the palm pattern is expected to be unusual, total finger ridges count (TFRC) decreased and asymmetry of finger ridge count (AFRC) increased.

References

1. Thompson JS, Thompson MW (1989). *Genetics in medicine*, 4th Ed. W.B. Saunders Co. Toronto, Canada, pp. 283-86.
2. Holt SB (1970). Dermatoglyphics in Mongolism, *Ann NY Acad Sci*, 171: 602.
3. Ross LJ (1968). Dermatoglyphic observation in a patient with Trisomy 18, *J Pediatr*, 72: 862.
4. Penrose LS (1966). Dermatoglyphic patterns in large acrocentric trisomy, *J Ment Defic Res*, 10:1.
5. Dallapiccola B, Bangi B, Pistocchi G (1972). Dermatoglyphic and skeletal hand abnormalities in Turner's syndrome: A tentative scoring method, *Acta Genet Med Gemellol*, 21: 69.
6. Schaumann B, Alter M (1976). *Dermatoglyphics in medical disorders*. Spring-Verlag. New York.
7. Singh Pk, Pandey SS, Singh G (1987). Dermatoglyphics in auto-immune dermatoses. *Indian J Dermatol*, 32(1): 8-15.
8. Selmanowitz VJ, Victor S, Warburton D, Orentreich N (1974). Fingerprint arches in alopecia areata. *Arch Dermatol*, 110 (4): 570-71.
9. Singh Pk, Pandey SS, Singh G (1983). Dermatoglyphics in psoriasis. *Indian J Dermatol*, 28(2): 47-55.
10. Pour-Jafari H, Yazdanfar A (2003). Dermatoglyphics in patients with eczema, psoriasis and alopecia areata. *Skin Res. Technol*, 9(3): 240.
11. Sarihi A, Pour-Jafari H, Garakhani M, Shahmirzai K, Monsef AR. (2003). Two cases of congenital cutis laxa in an Iranian rural family, *abstract book of The First National Congress of Early Detection of Diseases*, p. 23.
12. Pour-Jafari H, Sarihi A. Presentation of pedigree pattern of an Iranian family with two cases of autosomal recessive cutis laxa, *Med J IRI*. In press.
13. Kamali MS (1987). *Dermatoglyphics (fingerprints)*. Me'raj, Tehran, Iran, pp. 39-42.
14. Bhanu BV (1973). Simian crease in man: Some methodological considerations, *J Hum Evol*, 2: 153-60.
15. Kamali MS (1985). Simian crease polymorphism among fifteen Iranian endogamous groups, *Anthropol Anz*, 43(3): 217-24.
16. Kamali MS, Mavalwala J, Kkaneqah AA, Bhanu BV (1991). Qualitative dermatoglyphic traits as measures of population distance, *Am J Phys Anthropol*, 85(4): 429-50.
17. Jantz RL (1975). Population variation in asymmetry and diversity from finger to finger for digital ridge counts, *Am J Phys Anthropol*, 45:215.
18. Pour-Jafari H, Farhud DD, Bagher-Nejad S (2000). Dermatoglyphical comparison of Mental retarded children and exceptional talents with students of the usual schools in Hamadan. *Abstract book, First National congress on Human Genetics*, shahrekord, Iran, p. 22.
19. Lami M, Frezal J, de Grouchy J, Kelley J (1957). Le nombre de Dermatoglyphes dans un echantillon de Jumeaux. *Ann Genet Hum*, 21: 374-84.
20. Book JA (1957). Frequency distributions of total finger ridge counts in the Swedish population, *Hereditas*, 43: 381-89.
21. Brehme HV, Reidel BH (1966). Uber Korrelationen Zwischen den Quantitativen werten aller finger und zehenbeerenmuster. *Anthropol Anz*, 28: 285.
22. Naugler CT, Ludman MD (1996). A case-control study of fluctuating dermatoglyphic asymmetry as a risk marker for developmental delay, *Am J Med Genet*, 66(1): 11-4.