

Fungal Involvement in Patients with Paranasal Sinusitis

*P Kordbacheh¹, F Zaini¹, M Emami¹, H Borghei², M Khaghanian¹, M Safara¹

¹Dept. of Medical Parasitology and Mycology, School of Public Health, Tehran University of Medical Sciences, Iran

² Amir Alam Hospital, Tehran University of Medical Sciences, Iran

Abstract

Fungal involvement of the paranasal sinuses is frequently observed in the immunocompromised host and it can become life-threatening if it is not diagnosed. Definitive diagnosis is made by tissue biopsy and culture. In this study biopsy materials of maxillary, ethmoidal and frontal sinuses of 60 patients with clinical manifestation of sinusitis and no response to medical therapy were assessed by mycological and pathological methods for the presence of fungi. Invasive fungal sinusitis was diagnosed in 3 patients and etiologic agents were *Candida albicans*, *Rhizopus* sp. and *Aspergillus fumigatus*. Predisposing factors in these patients were leukemia, diabetes mellitus and previous sinus and polyp surgery, respectively. Allergic fungal sinusitis also was seen in one patient and *Alternaria* sp. isolated from the biopsy material. Only the patient with allergic form of disease survived but all the patients with invasive form of fungal infection were expired. This clearly underscores the need of early recognition of fungal sinusitis in at risk population in order to start urgent treatment. In this study *Nocardia asteroides* also was isolated from the biopsy sample in a patient with sinunasal adenocarcinoma.

Keywords: Fungal sinusitis, Nocardiosis, Iran

Introduction

In recent years there has been a marked increase in mycotic infections of the paranasal sinuses. This has been attributed both to an increase in the survival of subjects at risk and to improvements in diagnostic techniques enabling the identification of fungal sinusitis (1). There are three types of invasive fungal sinusitis (IFS): acute fulminant, chronic and granulomatous. The granulomatous type is believed to be a subcategory of chronic IFS (2). Acute fulminant IFS have an invasive and destructive nature and mainly occurs in immunocompromised patients. The prognosis is poor and mortality has been reported as 50 to 80% in some series. Patients at the highest risk for acute fulminating form are poorly controlled diabetics and those with conditions that predispose to metabolic acidosis such as chronic renal failure. Immunosuppressive states secondary to chemotherapy, hematologic disorders and trans-

plantation also place their host at risk for acute fulminant fungal sinusitis (2, 3). Chronic IFS can occur in normal individuals but it is more often in patients who have received steroids for some other condition or have diabetes mellitus. This is slowly progressive, destructive condition that may remain confined to the sinuses or spread to the orbit and brain (4). Allergic fungal sinusitis (AFS) is the most common fungal sinus disease. Most authors believe it is not an infection but an allergic response to fungal antigen. Patients with AFS classically present with recurrent nasal polyposis, history of several nasal surgeries in the past and a strong history of atopy (5, 6). The diagnosis of IFS is based on culture and histopathological evidence of tissue invasion by fungal organism (2) whereas the diagnosis of AFS requires the microscopic examination of the characteristic allergic mucin to determine the presence of eosinophils and fungal elements and of sinus tissue

to rule out invasion (4). As the clinical signs and symptoms of fungal sinusitis vary from mild nasal symptoms to severe complication, so it may provide problems in diagnosis and treatment and can be lethal in some patients. Therefore early diagnose and aggressive treatment of disease are essential for outcome of patients (7). In order to diagnosis of fungal sinusitis in this study, mycological and pathological examination were carried out on biopsy samples of maxillary, ethmoidal and frontal sinuses of 60 patients with clinical manifestation of sinusitis and no response to medical therapy.

Materials and Methods

Biopsy samples of 60 patients who underwent sinus surgery were assessed for the presence of fungi in Dept. of Medical Parasitology and Mycology, School of Public Health, Tehran University of Medical Sciences. All specimens were examined by direct microscopy after treatment of a preparation with potassium hydroxide (KOH), Gram and Giemsa stains. A portion of each tissue biopsy from the paranasal sinuses were inoculated on Sabouraud, Sabouraud with chloramphenicol and brain heart infusion agar media and incubated at 25 and 37°C. Hematoxylin and eosin (H&E) stained sections of the paranasal sinus material were examined for the presence of fungi. Gomori methenamine silver (GMS) and Periodic acid-Schiff (PAS) stains were also applied to the sections in order to confirm the diagnosis. Some other methods including slide culture, production of germ tube and chlamydoconidia, biochemical and serological tests were performed if necessary.

Results

We examined operative specimens from 60 patients who underwent sinus surgery to determine fungal sinusitis. Mycological culture of the biopsy samples in this study yielded pure growth of fungi in 4 patients. Isolated fungi were *Aspergillus fumigatus*, *Candida albicans*,

Rhizopus sp. and *Alternaria* sp. respectively. The presence of fungal elements in pathologic sections of biopsy materials was confirmed by use of special stains as GMS and PAS. The patient with *Aspergillus* sinusitis was a 28-year-old man with a history of several sinus and polyp surgeries. KOH preparation and histopathologic examination showed numerous fungal organisms with septate hyphae within the mucosa (Figs. 1, 2).

C. albicans was isolated from the biopsy sample of maxillary and ethmoidal sinuses in 32-year-old man who was undergoing chemotherapy for leukemia. Pathologic examination revealed that fungal elements (blastoconidia & hyphae) had invaded the soft tissue (Fig. 3).

Rhizopus sp. was isolated from the biopsy material of maxillary and ethmoidal sinuses in a 69-year-old woman with uncontrolled diabetes mellitus. Histopathological analysis of biopsy material confirmed the diagnosis of mucormycosis and invasion of tissue by aseptate hyphae element was seen (Fig. 4). *Alternaria* sp. was isolated from the biopsy sample of frontal sinus in a 15-year-old girl. Histologic examination presented eosinophilic mucin with Charcot-Lyden crystals and non invasive luminal fungal hyphae (Fig. 5). Serologic tests (LAT & CIE) were negative in the cases of candidiasis and aspergillosis. In this study a case of sinusitis caused by *Nocardia asteroides* was seen in a 43-year-old man with sinunasal adenocarcinoma. Microscopic examination of sinus content showed gram positive filaments and culture of sample revealed colonies of *Nocardia*. By modified acid-fast staining of both sinus content and of the culture, delicate acid-fast branching filaments were seen (Fig. 6), these filaments are characteristic of *Nocardia* species, and on the basis of biochemical and physiological characteristics including positive reduction of nitrate and lack of gelatin, tyrosine, casein and hypoxanthin decomposition, *N. asteroides* was identified.

All the patients with IFS were expired in spite of treatment by amphotericin B. But the patient

with AFS improved by administration of steroids and antihistamines. Antibacterial agents

and surgery were curative in the case of nocardiosis.

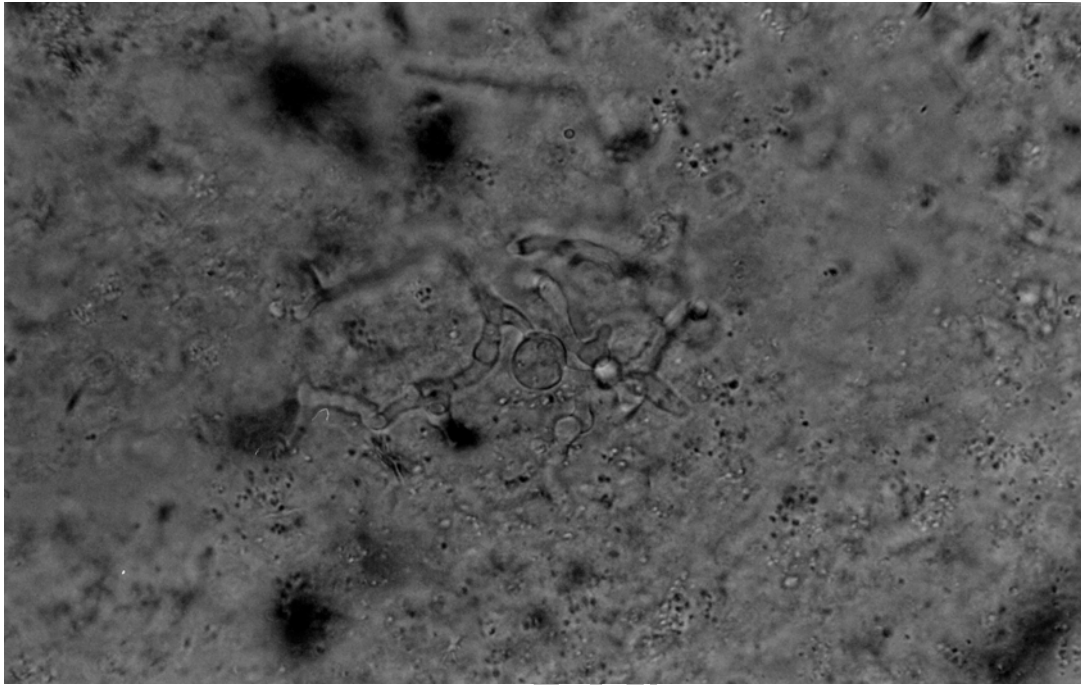


Fig.1: *Aspergillus* hyphae in KOH preparation of sinus material

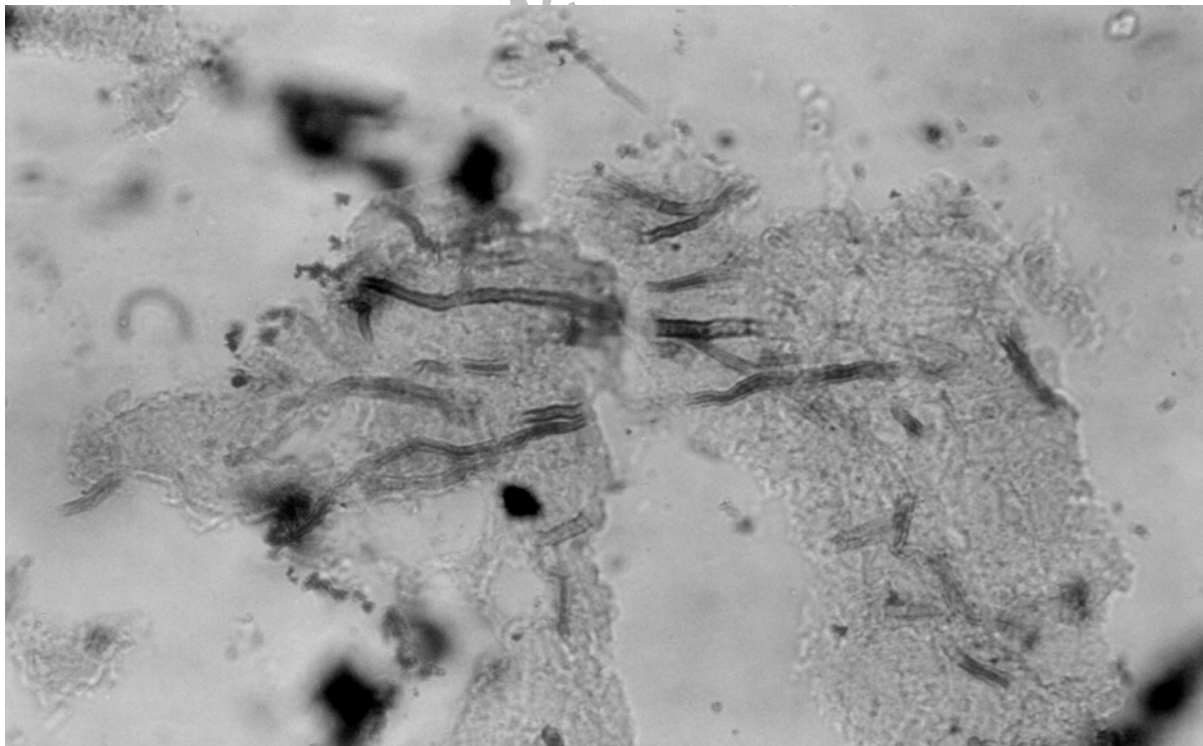


Fig. 2: Aspergillosis of paranasal sinus. Dichotomous hyphae of *Aspergillus fumigatus* (GMS, $\times 1000$)

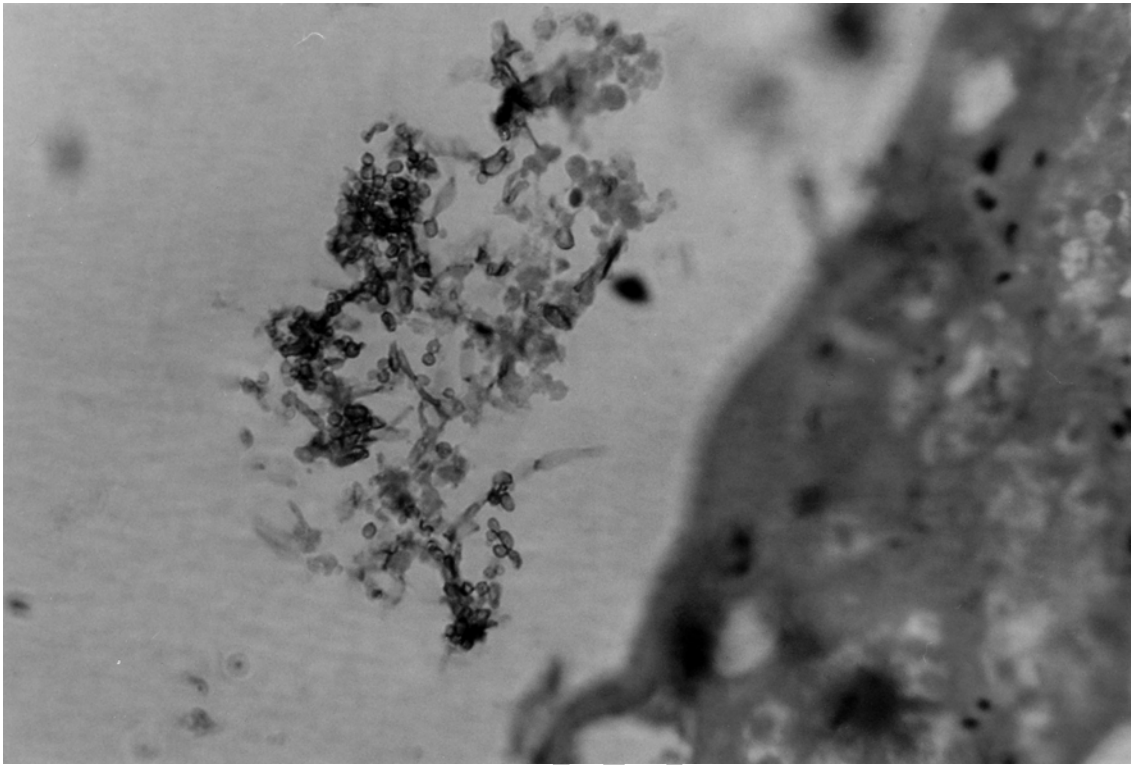


Fig. 3: Candidiasis of paranasal sinus. Blastoconidia & hyphae of *Candida albicans* (GMS, $\times 1000$)

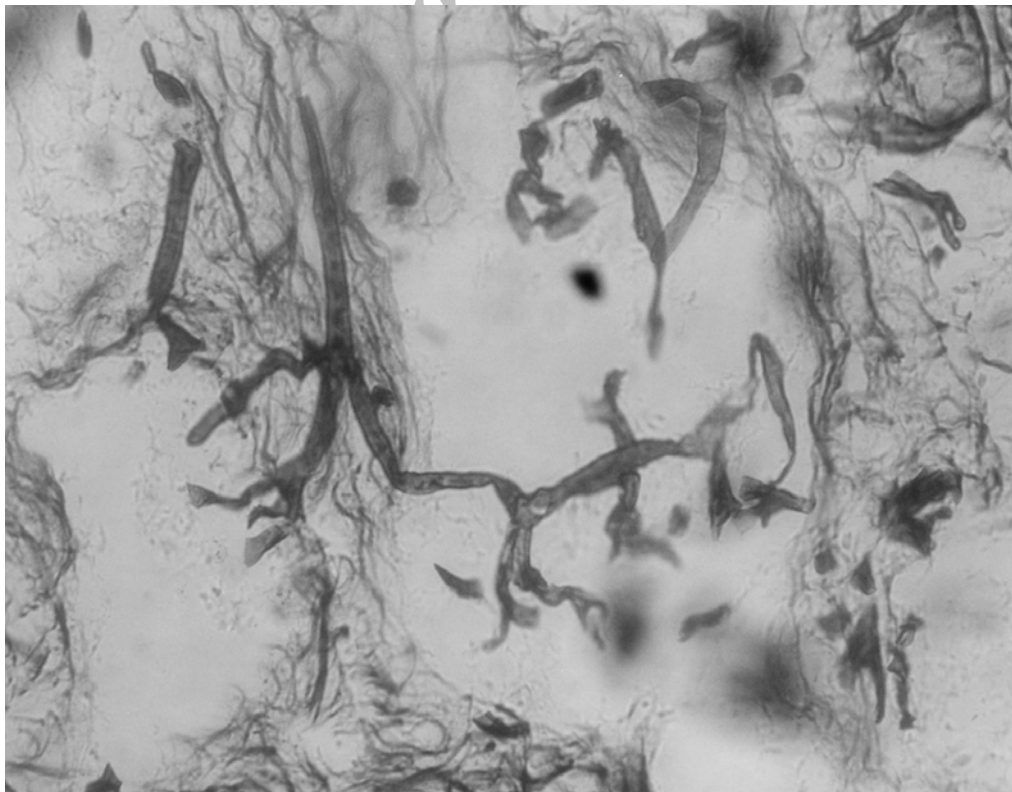


Fig. 4: Zygomycosis of paranasal sinus. Broad aspetate hyphae of *Rhizopus* sp. (GMS, $\times 1000$)

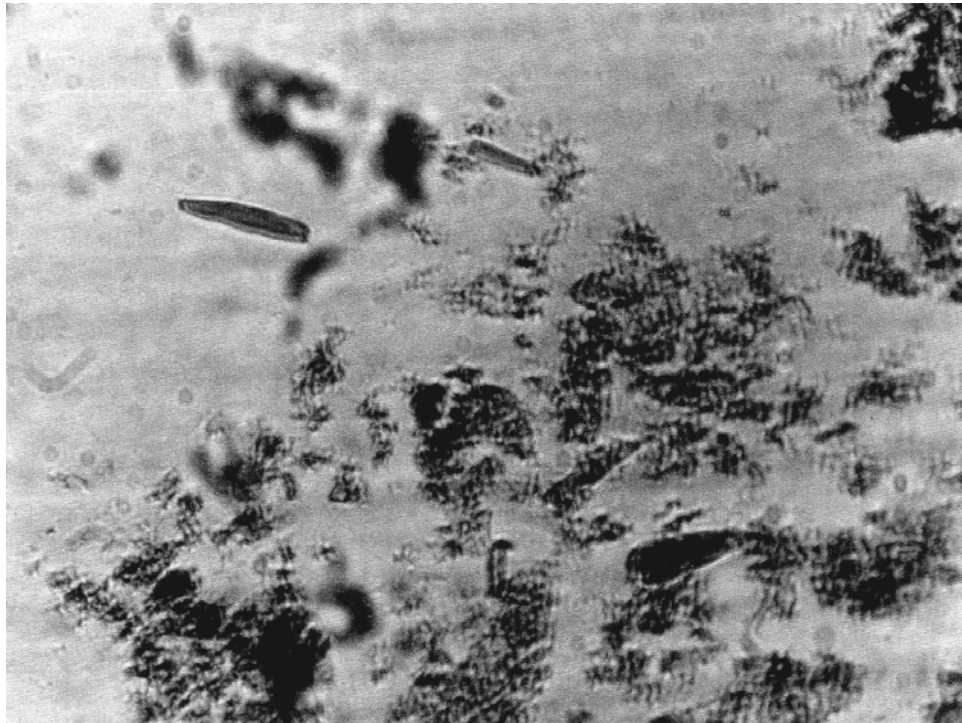


Fig. 5: Allergic fungal sinusitis caused by *Alternaria* sp. Charcot-Lyden crystals in sinus material (GMS, $\times 400$)

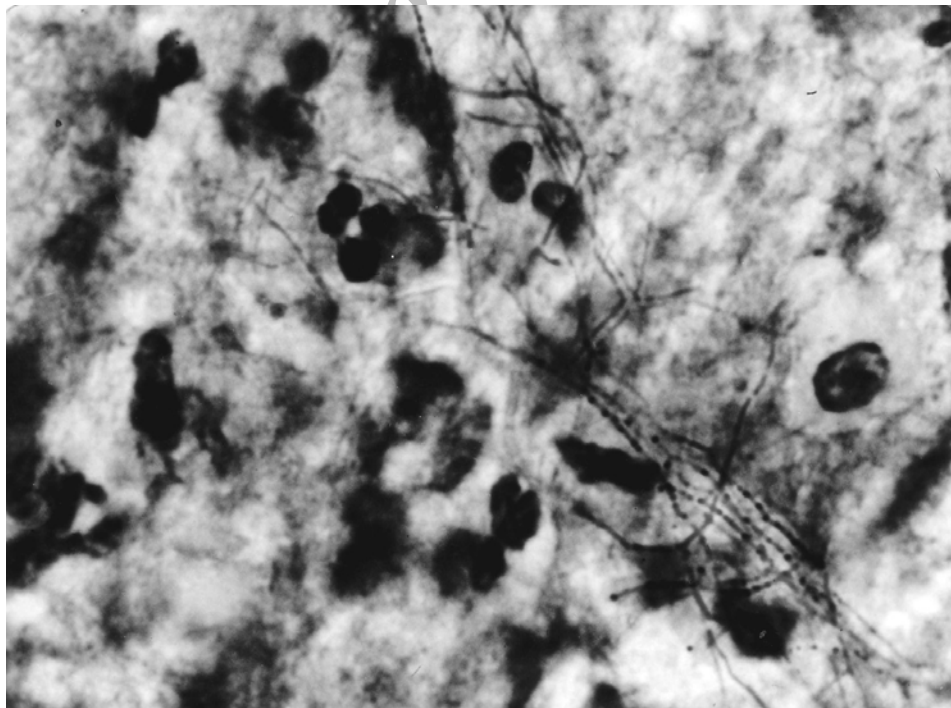


Fig. 6: Nocardiasis of paranasal sinus. Delicate branched filaments of *Nocardia asteroides* (Modified Kinyoun's acid-fast, $\times 1000$)

Discussion

IFS provides problems in diagnosis and treatment and can be lethal in some patients. Mortality rate is considerable and a large number of patients have permanent neurological, visual and cosmetic disabilities. Definitive diagnosis is made by means of culture of biopsy material and demonstrating tissue invasion by fungus and not merely superficial colonization (1,3, 8). In our study biopsy materials of the 60 patients who underwent sinus surgery were examined for fungal infection and on the basis of culture and histopathological evidence, fungal sinusitis was diagnosed in 4 (6. 6%) patients. It is estimated that 8-10% of patients undergoing surgery for sinusitis or polyposis have fungal sinusitis either extramucosal non-invasive or invasive (3). Similar rates of fungal sinusitis through our research have been reported in a few other studies in Iran (9-13), so it seems that the rate of this infection in our country is comparable with other reports. Fungal involvement of paranasal sinuses requires some type of impairment of local or systemic host mechanism which facilitates the conversion of fungal organisms from saprophytic to pathogenic. Individuals with a history of recurrent bacterial sinusitis may develop thickening of the mucosa which leads to chronic sinusitis and the colonization of the airway with mold secondary to frequent use of broad-spectrum antibiotics. Therefore it is not surprising that fungal infections are encountered in chronic bacterial sinusitis (14, 15). In present study, a case of IFS caused by *A. fumigatus* was diagnosed in a 28-year-old man with clinical manifestation of sinusitis and a history of several sinus surgeries. The patient had no evidence of immunosuppression and any other significant underlying medical problems. Chronic IFS can occur in normal individuals and is a slowly progressive, destructive condition that may remain confined to the sinuses or spread to the orbit and brain. The most common organism is *A. fumigatus* and affected individuals usually complain of

long standing symptoms of allergic rhinitis or chronic bacterial sinusitis (4). In this patient, on the basis of clinical and pathologic criteria, chronic IFS with spread into orbit and brain were diagnosed.

Acute fulminant IFS mainly occurs in immunocompromised status such as malignancy or diabetes mellitus or after administration of chemotherapy. Aggressive chemotherapeutic regimens for the treatment of leukemia place patients at a great risk for invasive fungal diseases (8). Acute fulminant IFS characterized by a rapidly progressive course with high mortality and morbidity (2, 3). We diagnosed two cases of acute fulminant IFS in this study.

Causative organisms were *Rhizopus* sp. and *C. albicans*. Predisposing factors were uncontrolled diabetes mellitus and leukemia.

Patients with IFS in our study were expired in spite of surgical resection and antifungal therapy. As previously mentioned the mortality rate associated with fungal sinusitis is considerable. Early diagnosis and aggressive treatment of disease are essential for the outcome of patients. Diagnosis of IFS still remains major problem. The clinical signs and symptoms are not specific. Fever, nasal obstruction, headache and facial swelling in an immunocompromised patient may be the earliest indication of acute fulminant IFS. Therefore a high degree of suspicion, careful clinical examination and precise radiologic localization may be helpful for early diagnosis. But tissue biopsy, for culture and histologic identification of fungi is the gold standard diagnostic procedure (1, 3, 7). The mainstay of treatment is immediate surgical resection followed by aggressive medical therapy and subsequent debridements (16). The poor prognosis in our patients may be due to a failure in early diagnose, extensive involvement and the underlying condition. Moreover despite the most aggressive and combined therapy, fungal sinusitis can be a relentlessly progressive disease (17). AFS is a non-invasive fungal disease.

In our study a case of AFS due to *Alternaria* sp. was diagnosed in a 15-year-old girl with frontal sinusitis. Diagnosis was based on histopathologic assessment and identifies absence of tissue invasion. The patients with IFS usually are young immunocompetent atopic adults with chronic relapsing rhinosinusitis and recurrent nasal polyposis with history of several nasal surgeries in the past. Treatments by antibiotics, antihistamines or corticosteroids are not helpful (1, 5). We must consider AFS in the patients with chronic sinusitis and no response to medical therapy or it may present with unilateral nasal polyposis and thick yellow-green nasal or sinus mucus (1, 4). Surgical excisions with adjunctive topical steroids are necessary for treatment. The use of oral steroid and antifungal drug is recommended by some researchers (5). In our patient improvement was seen by surgical excision and administration of oral steroids and antihistamines.

We also diagnosed a case of maxillary sinusitis caused by *N. asteroides* in a patient with sinunasal adenocarcinoma. This is the first report of *Nocardia* sinusitis in Iran. *Nocardia* should always be kept in mind as a potential cause of opportunistic infection (18). The frequency of *Nocardia* infection in immunocompromised patients has increased during the past few years and cases of sinusitis have been reported (19, 20). Members of *N. asteroides* complex are responsible for about 80% of non cutaneous invasive nocardiosis. Mortality in immunocompromised patients with *Nocardia* infections is high (18). We believe that positive outcome in our patients is due to aggressive treatment by surgical excision and antibiotic therapy.

Acknowledgments

The authors would like to thank Audio-visual unite. (School of Public Health, Tehran University of Medical Sciences) for their sincere cooperation. We also thank Mrs Sh. Jafarian for typing of the manuscript.

References

1. Erkilic S, Aydin A, Bayazit YA, Guldur E, Deniz H et al (2003). Histopathologic assessment of fungal involvement of paranasal sinuses in Turkey. *Acta Otolaryngol*, 123(3): 413-16.
2. Busaba NY, Colden DG, Faquin WC, Salman SD (2002). Chronic invasive fungal sinusitis. *Ear Nose Throat J*, 81(7): 462-66.
3. Sohail MA, Al khabori M, Hyder J, Verma A (2001). Acute fulminant fungal sinusitis: clinical presentation, radiological findings and treatment. *Acta Trop*, 22. 80 (2): 177-85.
4. Richardson Malcolm D, Warnock David W (2003). *Fungal infection: Diagnosis and management*. 3rd ed. Blackwell. Massachusetts.
5. Rupa V, Jacob M, Mathews MS (2001). Atopy, proptosis, and nasal polyposis. *Postgrad med J*, 77 (907): 343, 350-52.
6. Venarske DL, deShazo RD (2002). Sino-bronchial allergic mycosis. The SAM syndrome. *Chest*, 121(5): 1670-76.
7. Wehl G, Hoegler W, Kropshofer G, Meister B, Fink FM, Heiter A (2002). Rhinocerebral mucormycosis in a boy with recurrent acute lymphoblastic leukemia: Long term survival with systemic antifungal treatment. *J Pediatr Hematol Oncol*, 24 (6): 492-94.
8. Malhotra PS, Danahey D, Sidman J (2001). Bilateral lateral rhinotomy incisions for medial maxillectomies in the management of pediatric invasive fungal sinusitis. *Laryngoscope*, 111(11pt):1960-63.
9. Badiie P (2001). Report of two cases of sinusitis due to *Aspergillus* in Shiraz. *J Tashkhis*, No.14:55-56.
10. Ghahri M, Soruri R (2002). Study of 39 patients with chronic sinusitis for fungal involvement. The 10th Iranian Congress of Infectious Disease and Tropical Medicine, P. 175.

11. Madani SA, Shokohi T (1999). Study of allergic fungal sinusitis in patients with chronic sinusitis. *J of Mazadaran Uni Med Sci*, 9(25):1-9.
12. Moghaddami M, Mohraz M, Shidfar MR (1993). Report of thirteen cases of mucormycosis. *MJIRI*, 7 (3): 175-78.
13. Shafii A, Eslami M (1989). Rhino – orbital mucormycosis: report of a successfully treated patient. *MJIRI*, 3 (3, 4): 191-93.
14. Kaplan DM, Briscoe D, Niv A, Gatot A, Leiberman A, Fliss DM (2001). Detection of sinus-induced orbital mycosis with standardized orbital ultrasonography: A case report. *Ear Nose Throat J*, 80 (8): 576-8, 580, 582.
15. Chin-Hong PV, Sutton DA, Roemer M, Jacobson MA, Aberg JA (2001). Invasive fungal sinusitis and meningitis due to *Arthrographis kalrae* in a patient with AIDS. *J clin microbiol*, 39(2): 804-7.
16. Wali YA, Al Lamki Z, Al Kindi H, Taqi AM, Shah W, Soliman H, Zackaria M, AL Okbi H (2001). Case report successful outcome of invasive nasal sinus zygomycosis in a child with relapsed acute lymphoblastic leukemia due to liposomal amphotericin B. *Mycoses*, 44 (5):195-99.
17. Azap A, Arsalan H, Ergin F, Karakayali H, Haberal M (2002). Disseminated *Nocardia asteroides* and coinfection with *Trichophyton rubrum* in a renal transplant recipient. *Transpl Infect Dis*, 4 (4): 223- 25.
18. Unzaga MJ, Crovetto MA, Santamaria JM, Llanos A, Ezpeleta C, Cisterna R (1996). Maxillary sinusitis caused by *Nocardia nova*. *Clin Infect Dis*, 23(1): 184-85.
19. Marquez-Diaz F, Soto-Ramires LE, Sifuentes-Osornio J (1998). Nocardiosis in patients with HIV infection. *AIDS patient Care STDS*, 12 (11): 825-32.
20. Roberts SA, Bartley J, Braatvedt G, Ellis-Pegler RB (1995). *Nocardia asteroides* as a cause of sphenoidal sinusitis, case report. *Clin Infect Dis*, 21 (4): 1041-2.