

## **Effect of Tindurin on Immunopathogenesis Mechanism of Collagen-Induced Arthritis**

*F Saadat<sup>1</sup>, \*A Mirshafiey<sup>1</sup>, M Pezeshki<sup>1</sup>, MR Khorramizadeh<sup>1</sup>, R Sedaghat<sup>2</sup>, A Razavi<sup>1</sup>  
S Cuzzocrea<sup>3</sup>*

<sup>1</sup>*Dept. of Immunology, School of Public Health, Tehran University of Medical Sciences, Iran*

<sup>2</sup>*Dept. of Pathology, School of Medicine, University of Shahed, Tehran, Iran*

<sup>3</sup>*Institute of Pharmacology, School of Medicine, University of Messina, Messina, Italy*

(Received 10 Apr 2005; revised 13 Jul 2005; accepted 24 Jul 2005)

### **Abstract**

Rheumatoid arthritis is a chronic inflammatory disease characterized by the sequestration of various leukocyte subpopulations within both the developing pannus and synovial space. This study was undertaken to examine the therapeutic potency of tindurin in experimental rheumatoid arthritis. Collagen-induced arthritis (CIA) was induced by intradermally immunization of Lewis rats at the base of the tail. The paws and knees were then removed for histopathology and radiography analysis. Using fibrosarcoma cell line the apoptosis process was measured by Terminal deoxyribonucleotidyl transferase-mediated dUTP nick-end labeling (TUNEL) method. Our data showed that the i.p. injection of tindurin to arthritic rats induced a significant reduction in paw edema. Histopathological assessment showed reduced inflammatory cells infiltrate, tissue edema and bone erosion in joints of treated rats. Moreover, our results in radiography were in line with histological findings as well as tindurin was found to induce apoptosis of treated cells in comparison with positive, negative and non-treated ones. Our findings revealed the therapeutic effect of tindurin in experimental model of rheumatoid arthritis in comparison with methotrexate as a choice drug.

**Keywords:** *Anti-malarial drugs, Tindurin, Rheumatoid arthritis, Apoptosis, Iran*

### **Introduction**

Rheumatoid arthritis (RA) is a systemic autoimmune disease characterized by polyarticular symmetrical arthritis. Inflammatory mediators targeting joint structures produce joint inflammation with pain, functional loss, joint destruction and permanent deformity. While this disease has a worldwide distribution, its pathogenesis is not clearly understood (1). The collagen-induced arthritis (CIA) is a model of experimental arthritis, which is induced by the injection of type II collagen (CII) (2, 3). The similarities between the joint pathology as well as cellular and humoral immunity in CIA and RA, suggest that CIA is a relevant animal model which is useful in the search for new an-

tiarthritic drugs (4-9). In human, joint damage typically occurs before patients are diagnosed, and most of the joint destruction occurs within the first 2 yr of diagnosis (10). Therapeutic agents such as methotrexate (a disease modifying anti-rheumatic drug, DMARDs) and immunomodulators lessen the progression rate of the disease, suggesting that these drugs fail to adequately control the underlying pathophysiology of RA (11, 12).

Tindurin has been used for many years against malaria, initially on its own, but subsequently in combination with other drugs. Tindurin has also been used recently against toxoplasmic encephalitis relapses and *Pneumocystis carinii* pneumonia in HIV-infected patients (13).

Pyrimethamine (tindurin) inhibits dihydrofolate reductase-thymidylate synthase (DHFR-TS) in the folate biosynthetic pathway and resistance to it arises from mutation in the *dhfr* domain of the *dhfr-ts* gene (14). In humans, DHFR and TS are separate gene products, DHFR being monomeric and TS dimeric so the effect of this medicinal agent is specific (14, 15). The aim of the current research was to determine whether the tindurin was able to suppress the development of arthritis in experimental model.

## Materials and Methods

**Animals** Male Lewis rats weighing 160-180 g (Charles River, Milan, Italy) were used for these studies. The animals were housed in a controlled environment and provided with standard rodent chow and water. The rats were divided at random into four groups, N: normal group (n= 8); C: control group (n=9), T1: treated with tindurin 1mg/kg/d (n= 8); T2: treated with methotrexate 0.3mg/kg three times weekly (n=8). Animal care was in compliance with Italian regulations on the protection of animals used for experimental and other scientific purposes (document DM 116192) as well as with the European Economic Community regulations (document OJ of ECL 358/1, ratified 12/18/1986).

**Induction of CIA and treatment protocol** Bovine CII was dissolved in 0.1M acetic acid at a concentration of 2 mg/ml by stirring overnight at 4° C. Dissolved CII was frozen at -70° C until used. Before injection, CII was emulsified with an equal volume of Freund's complete adjuvant (CFA). CIA was induced as previously described (16). Briefly, on day 1, rats were injected intradermally at the base of the tail with 100 µl of emulsion (containing 100 µg of CII). On day 21, a second injection of CII in CFA was administered. The intraperitoneally administration of tindurin and methotrexate (MTX) were started on day 25 post-immunization and continued until final assessment on day 35. During this period, clinical examination was taken intermittently. The paws and knees were then removed for histopathological assay.

**Clinical assessment of CIA** Rats were evaluated daily for arthritis according to a macroscopic scoring system using a scale from 0 to 4 for each paw: 0= no signs of arthritis, 1= swelling and/ or redness of the paw or 1 digit, 2= involvement of 2 joints, 3= involvement of > 2 joints, and 4= severe arthritis of the entire paw and digits (17).

**Histological processing and assessment of arthritis damage** On day 35, animals were anesthetized with sodium pentobarbital (45 mg/kg intraperitoneally) and killed. Paws and knees were removed, trimmed and fixed in 10% buffered formalin, decalcified and then embedded in paraffin, sectioned at 5µm and stained with hematoxylin and eosin for histological examination. Joint damage was assessed based on synovial hypertrophy, pannus formation, inflammatory cell infiltration and cartilage and subchondral bone destruction (18). Scoring was carried out in a blinded manner. Joint erosion was graded on a scale of 0-3 for each limb, according to the severity of damage.

**Radiographic evaluation** Radiological scoring was determined by an investigator blinded to the treatment protocol on day 35. A score was assigned to each joint on the basis of degree of soft tissue swelling, joint space narrowing, periosteal new bone formation and bone destruction. Scores were 0-3 per joint (0, normal; 3, maximum joint destruction) (19, 20).  
**Cell culture:** The Fibrosarcoma (WEHI-164) cell line was seeded at an initial density of  $2 \times 10^4$  cells/well in 96-well tissue culture plates. Cells were maintained in RPMI-1640 medium supplemented with 5% fetal calf serum, penicillin at 100 units/ml, and streptomycin at 100 µg/ml, with 5% CO<sub>2</sub>, 37° C and saturated humidity.

**Cell apoptosis assay.** Cells were treated with pyrimethamine at different concentrations 0.1, 1 and 10 µg/ml for 24 h and were then fixed in 4% paraformaldehyde and permeabilized with 0.1% Triton X-100. The terminal deoxynucleotidyl transferase-mediated dUTP nick-end labeling (TUNEL) assay for detecting DNA

fragmentation was performed by flow cytometric analyses (APO-BRDU, Roche, CA, USA). Cell nuclei were stained with Fluorescein and Propidium iodide. Apoptotic and total cells were then counted by flow cytometry (FACS Calibar Becton, Dickinson, USA). The results were expressed as percentage of apoptotic cells.

**Statistical analysis** All data were expressed as the mean± SEM. The significance of differences in arthritic scores, histopathology and radiology assessment were evaluated with the Mann-Whitney test. *P* values less than 0.05 were considered significant.

## Results

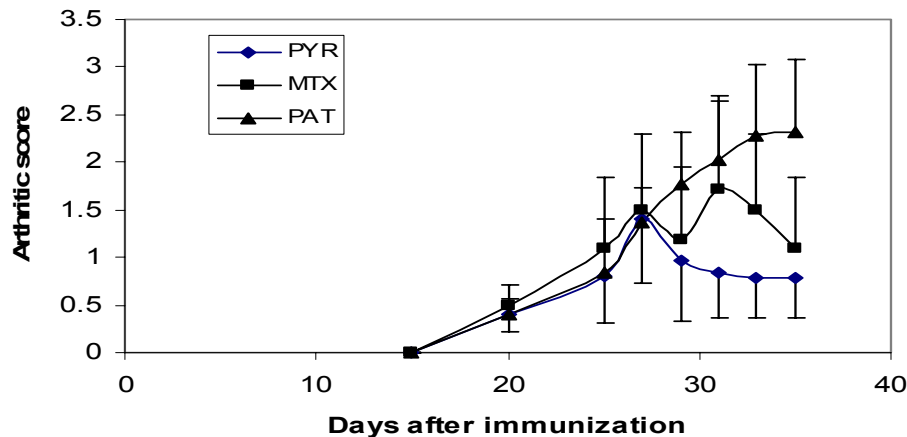
**Effect of tindurin in CIA** As shown in Fig. 1, CIA developed in rat immunized with CII, and clinical signs (periarticular erythema and edema) of the disease first appeared in the hind paws between days 25 and 27 after CII challenge, with a 100% incidence of CIA by day 27. The interaperitoneally injection of tindurin (1mg/kg/d) to arthritic rats could rapidly reverse paw edema as did MTX (no significant difference). The difference between control group and treated rats on days 30-35 of experiment was significant (*P*<0.05).

Histopathology findings. As shown in Fig. 2 histological evaluation of the paws in the control animals reveals signs of severe arthritis

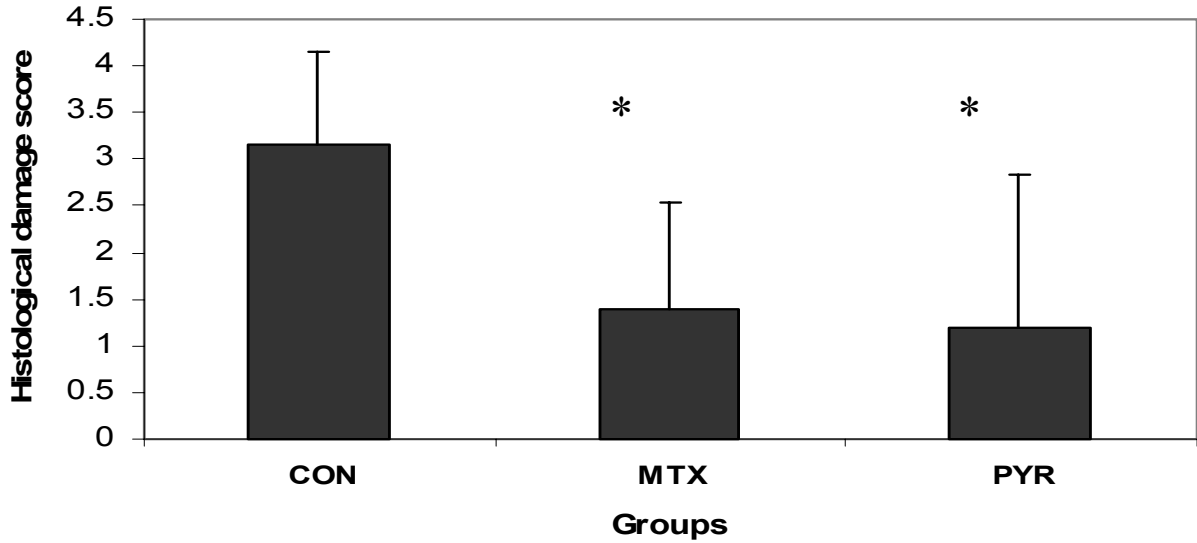
along with inflammatory cells infiltrate. Histopathological assessment showed a reduced inflammatory cells infiltrate in the joints of treated rats, as well as the number of osteoclasts present in the subchondral bone, tissue edema and bone erosion in the paws were markedly reduced by both drugs (treatment with tindurin and MTX), indicating that the tested drugs were effective in retarding synovial inflammation and prevented joints destruction.

**Radiographical findings.** Radiographical analysis of affected joints in control rats showed soft tissue swelling, joint space narrowing, reduced lucency due to demineralization and areas of recalcification indicative of new bone formation. Blinded radiographical scores on day 35 were significantly lower in tindurin-treated rats than nontreated animals and paralleled with MTX (Fig.3). The radiographical appearance of swollen joints was comparable with the results of arthritic index and histological changes of joints.

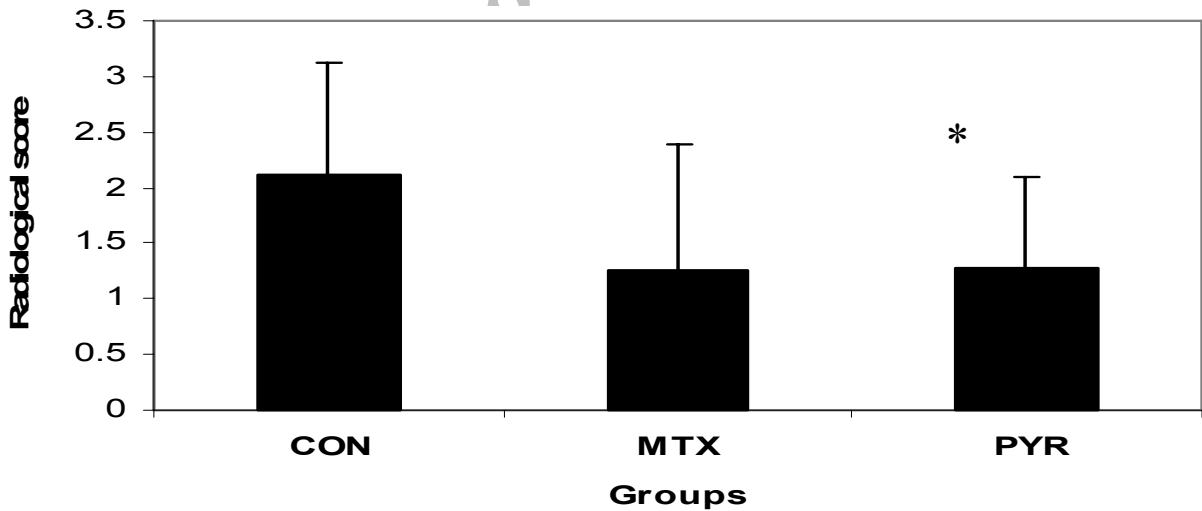
**Effect of tindurin in apoptosis.** Using the TUNEL assay method, we determined that apoptosis was induced in tindurin -treated cells in comparison with positive, negative as nontreated cells. As depicted in Fig. 4 the rate of apoptosis for tindurin at different concentrations (0.1, 1 and 10 µg/ml) was 3.30%, 9.42% and 11.32%, respectively.



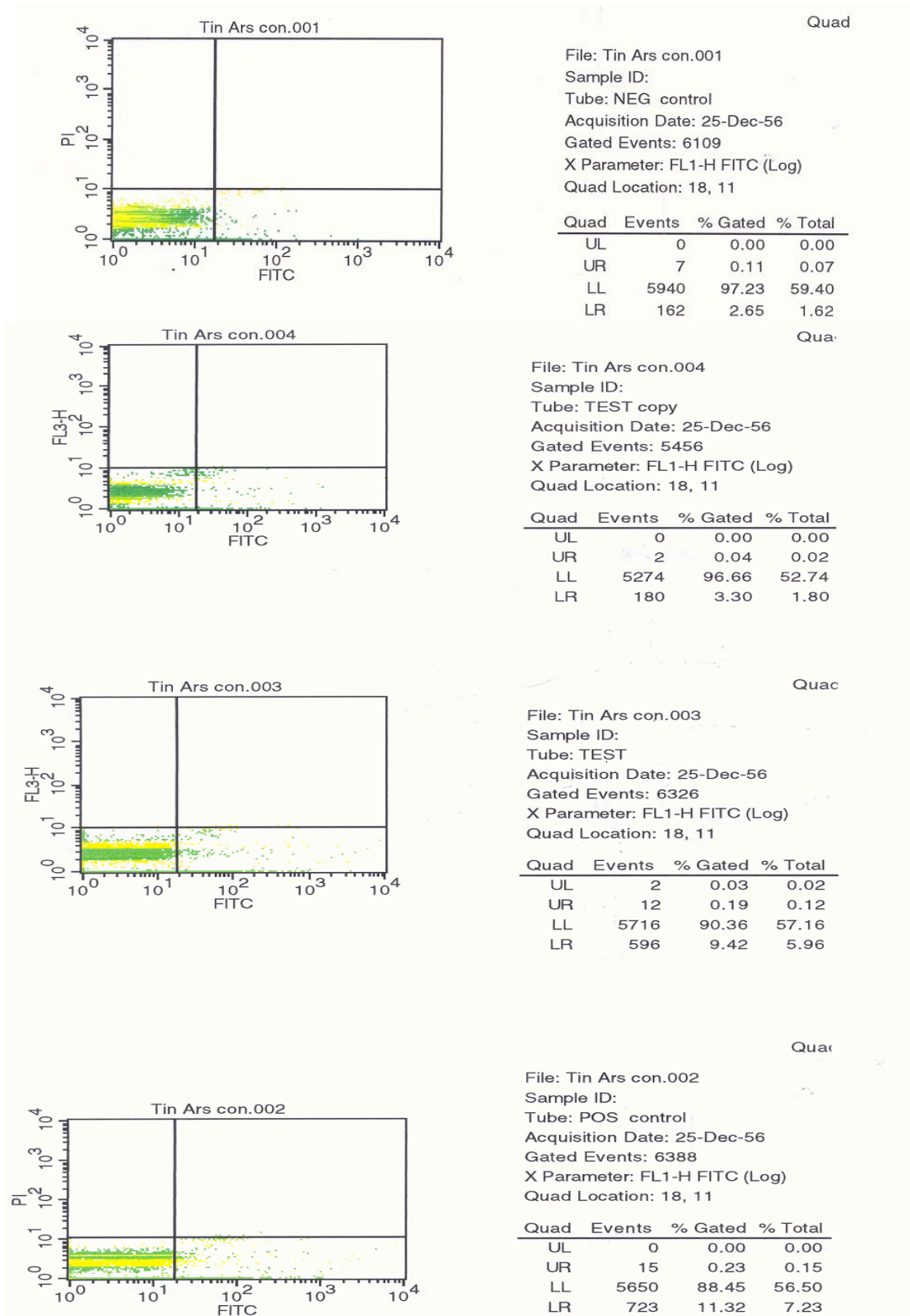
**Fig.1:** Severity of arthritis score in treated groups PYR (tindurin) and MTX (methotrexate) compared with non-treated control rats (CON). Number of rats in each group was eight. Total of i.p. injection (10), and administered PYR and MTX were 1mg/kg/d and 0.3 mg/kg three times weekly, respectively. The severity of arthritic lesions was significantly reduced on days 30-35 p.i. in PYR-treated animals compared with control rats. *P*<0.05 was considered significant.



**Fig. 2:** Semi-quantitative scoring of histological changes of the involved joints in groups PYR (treated with tindurin) and MTX ( treated with methotrexate) versus CON (control) were significant. Bars show the mean $\pm$  SEM.  $P < 0.05$  was considered statistically significant.



**Fig. 3:** Semi-quantitative scoring of radiological examination of the involved joints in groups PYR (treated with tindurin) and MTX ( treated with methotrexate) versus CON (control) were significant. Bars show the mean $\pm$  SEM.  $P < 0.05$  was considered statistically significant.



**Fig. 4:** Assessment of apoptosis by flow cytometry. From up to down; Negative control, Positive control, pyrimethamine-treated cells at different doses (0.1, 1 and 10 µg/ml). The TUNEL assay revealed that the rate of apoptosis for pyrimethamine -treated cells was 3.30%, 9.42% and 11.32%, as compared to positive, negative and non-treated cells, respectively.

## Discussion

The recent investigations indicate that rheumatoid arthritis should no longer be considered a benign disease. Considerable data suggest that this disease is associated with diminished long-term survival (21). The clinical trials on different treatment strategies in rheumatoid arthritis have shown that the antimalarials are useful drugs in the treatment of various rheumatic diseases (22-24), so that hydroxychloroquine is used as a second-line treatment of rheumatoid arthritis (25, 26). In this investigation, to imitate the clinical scenario of RA, CIA was induced in Lewis rats and subsequently, the antiarthritic potency of tindurin (pyrimethamine) was assessed in mentioned experimental model. This drug is being used for many years against malaria and in combination with other drugs is also used recently against toxoplasmic encephalitis relapses and *Pneumocystis carinii* pneumonia in HIV-infected patients (27). It has been reported that tindurin also has antibacterial value (28). Tindurin inhibits dihydrofolate reductase-thymidylate synthase (DHFR-TS) in the folate biosynthetic pathway and resistance to it arises from mutation in the *dhfr* domain of the *dhfr-ts* gene (27, 29). Here, we demonstrate that treatment with tindurin reduces the development of clinical signs in CIA model and infiltration of PMNs in the joints (histology), as well as the degree of joint injury (histology, radiography) in rats treated with type II collagen compared with MTX which is the most widely used DMARDs. All of these findings support the view that tindurin attenuates the degree of arthritis and joint damage caused by collagen in the rat.

To investigate the apoptotic effect of tindurin, we used a fibrosarcoma [WEHI-164] cell line, a highly sensitive cell line (30), since the synovial fibroblasts contribute to chronic inflammatory responses in RA as a major part of the invasive pannus (31). DNA fragmentation, a typical feature observable in cells undergoing apoptotic cell death was induced in WEHI cells

by treatment with tindurin. Data obtained from TUNEL assay exhibited that tindurin induced cell apoptosis in a dose dependent manner. Our data were in agreement with the result of clinical trial on the autoimmune lymphoproliferative syndrome (ALPS). ALPS is a recently identified human disorder of lymphocyte apoptosis. The genetic mechanism of this syndrome is based on identified defects in caspase-8 and caspase-10 along with mutations of the tumor necrosis factor receptor super family member 6 (TNFRSF6) gene, coding for the apoptosis-inducing protein Fas (Apo-1, CD95) (32).

Some reports suggest that sulphadoxine-pyrimethamine treatment may be useful in patients with this syndrome and this approach is presently being studied in a controlled trial (33). However, molecular mechanisms by which tindurin induce apoptosis are thus still called for. In addition, our results showed that tindurin had low toxicity compared with MTX, which might be recommended as a second-line drug in treatment of rheumatoid arthritis.

## Acknowledgments

This research was financially supported by a grant from Tehran University of Medical Sciences, Iran.

## References

1. Harris ED Jr (1990). Rheumatoid arthritis: pathophysiology and implications for therapy. *N Engl J Med*, 322:1277-89.
2. Griffiths MM, Eichwald EJ, Martin JH, Smith CB, DeWitt CW (1981). Immunogenetic control of experimental type II collagen-induced arthritis. I. Susceptibility and resistance among inbred strains of rats. *Arthritis Rheum*, 24:781-89.
3. Larsson P, Kleinau S, Holmdahl R, Klare-skog L (1990). Homologous type II collagen-induced arthritis in rats: characterization of the disease and demonstration of clinically distinct forms of

- arthritis in two strains of rats after immunization with the same collagen preparation. *Arthritis Rheum*, 33:693-701.
4. Stuart JM, Townes AS, Ang AH (1982). The role of collagen autoimmunity in animals and human diseases. *J Invest Dermatol*, 79 Suppl: 1-11.
  5. Cathcart ES, Hayes KC, Gonnerman WA, Lazzari AA, Franzblau C (1986). Experimental arthritis in a nonhuman primate. I. Induction by bovine type II collagen. *Lab Invest*, 54: 26-31.
  6. Clague RB, Morgan K, Shaw MJ, Holt PJ (1980). Native type II collagen-induced arthritis in the rat. II. Relationship between the humoral immune response to native type II collagen and arthritis. *J Rheumatol*, 7: 775-82.
  7. Takeshita M, Hinoue H, Furukawa O, Takata I (1995). Initial arthritic lesions induced by immunization with type II collagen in Lewis rats. *Exp Anim*, 44: 6366.
  8. Takeshita M, Sugita T, Takata I (1997). Pathological evaluation of effect of anti-rheumatic drugs on type II collagen-induced arthritis in Lewis rats. *Exp Anim*, 46:165-69.
  9. Holmdahl R, Andersson M, Goldschmidt TJ, Gustafsson K, Jansson L, Mo JA (1990). Type II collagen autoimmunity in animals and provocations leading to arthritis. *Immunol Rev*, 118:193-232.
  10. Van der Heijde DM (1995). Joint erosions and patients with early rheumatoid arthritis. *Br J Rheumatol*, 34 (suppl 2):74-78.
  11. Weinblatt ME (1996). Rheumatoid arthritis: treat now, not later. *Ann Intern Med*, 124:773-74.
  12. Boey ML (1992). Treatment strategies in rheumatoid arthritis. *Singapore Med J*, 33:631-32.
  13. Schurmann D, Bergmann F, Albrecht H, Padberg J, Grunewald T, Behnsch M, Grobusch M, Vallee M, Wunsche T, Ruf B, Suttorp N (2001). Twice-weekly pyrimethamine-sulfadoxine effectively prevents *Pneumocystis carinii* pneumonia relapse and toxoplasmic encephalitis in patients with AIDS. *J Infect*, 42:8-15.
  14. Hyde JE (1990). The dihydrofolate reductase-thymidylate synthetase gene in the drug resistance of malaria parasites. *Pharmacol Ther*, 48: 45-59.
  15. Hunt SY, Rezvani BB, Sibley CH (2005). Novel alleles of *Plasmodium falciparum* dhfr that confer resistance to chlorocycloguanil. *Mol Biochem Parasitol*, 139: 25-32.
  16. Cuzzocrea S, Mazzon E, Bevilacqua C, Costantino G, Britti D, Mazzullo G, De Sarro A, Caputi A (2000). Cloricromene, a coumarine derivative, protects against collagen-induced arthritis in Lewis rats. *Br J Pharmacol*, 131:1399-407.
  17. Szabo' C, Virag L, Cuzzocrea S, Scott GS, Hake P, O'Connor M (1998). Protection against peroxynitrite-induced fibroblast injury and arthritis development by inhibition of poly (ADP-ribose) synthetase. *Proc Natl Acad Sci USA*, 9: 3867-72.
  18. Bremell T, Abdelnour A, Tarkowski A (1992). Histopathological and serological progression of experimental *Staphylococcus aureus* arthritis. *Infect Immun*, 60: 2976-85.
  19. Oliver SJ, Cheng TP, Banquerigo ML, Brahn E (1995). Suppression of collagen-induced arthritis by an angiogenesis inhibitor, AGM-1470, in combination with cyclosporin: reduction of vascular endothelial growth factor (VEGF). *Cell Immunol*, 166:196-206.
  20. Mirshafiey A, Chitsaz M, Attar M, Mehraian F, Razavi AR (2000). Culture filtrate of *Cryptococcus neoformans* var. *gattii* (CneF) as a novel anti-inflammatory compound in the treatment of experimental septic arthritis. *Scand J Immunol*, 52: 278-84.

21. Finesilver AG (2003). Newer approaches to the treatment of rheumatoid arthritis. *WMJ*, 102:34-7.
22. Araiza-Casillas R, Cardenas F, Morales Y, Cardiel MH (2004). Factors associated with chloroquine-induced retinopathy in rheumatic diseases. *Lupus*, 13:119-24.
23. Wassenberg S, Rau R (2003). Methotrexate, hydroxychloroquine, and intramuscular gold in rheumatoid arthritis. *J Rheumatol*, 1891:1891-92.
24. Johnsen V, Forre O, Haga HJ, Kvien TK, Mikkelsen K, Nordvag BY, Rodevand E (2003). Combination therapy in rheumatoid arthritis. *Tidsskr Nor Laegeforen*, 123:1511-13.
25. Carmichael SJ, Charles B, Tett SE (2003). Population pharmacokinetics of hydroxychloroquine in patients with rheumatoid arthritis. *Ther Drug Monit*, 25: 671-81.
26. Carmichael SJ, Beal J, Day RO, Tett SE (2002). Combination therapy with methotrexate and hydroxychloroquine for rheumatoid arthritis increases exposure to methotrexate. *J Rheumatol*, 29: 2077-83.
27. Ruf B, Schurmann D, Bergmann F, Schuler-Maue W, Grunewald T, Gottschalk H J, Witt H, Pohle HD (1993). Efficacy of pyrimethamine/sulfadoxine in the prevention of toxoplasmic encephalitis relapses and *Pneumocystis carinii* pneumonia in HIV-infected patients. *Eur J Clin Microbiol Infect Dis*, 12: 325-29.
28. Opravil M, Pechere M, Lazzarin A, Heald A, Ruttimann S, Iten A, Furrer H, Oertle D, Praz G, Vuitton DA (1995). Dapsone/pyrimethamine may prevent mycobacterial disease in immunosuppressed patients infected with the human immunodeficiency virus. *Clin Infect Dis*, 20: 244-49.
29. Hyde JE (1990). The dihydrofolate reductase-thymidylate synthetase gene in the drug resistance of malaria parasites. *Pharmacol Ther*, 48; 45-59.
30. Espevik T, Nissen-Meyer J (1986). A highly sensitive cell line, WEHI 164 clone 13, for measuring cytotoxic factor /tumor necrosis factor from human monocytes. *J Immunol Methods*, 95:99-105.
31. Firestein GS (1996). Invasive fibroblast-like synoviocytes in rheumatoid arthritis: passive responders or transformed aggressors? *Arthritis Rheum*, 39:1781-90.
32. Van der Werfften, Bosch J (2003). Auto-immune lymphoproliferative syndrome: etiology, diagnosis, and management. *Paediatr Drugs*, 5:185-93.
33. Oliveira JB, Fleisher T(2004). Autoimmune lymphoproliferative syndrome. *Curr Opin Allergy Clin Immunol*, 4:497-503.