

# **Homozygosity for Pericentric Inversions of Chromosome 9 in a Patient's Parents with Stillbirth - Report of a New Case and Review of Literature**

*M Khaleghian, \*C Azimi*

*Dept. of Genetics, Cancer Institute, Faculty of Medicine, Tehran University of Medical Sciences, Iran*

(Received 16 Aug 2005; revised 9 Feb 2006; accepted 11 Jun 2006)

## **Abstract**

Pericentric inversions of chromosome 9 are among the most frequent chromosomal rearrangement in human. A few cytogeneticists consider inversions of chromosome 9 as a normal variant. However, many reports in the recent literature link pericentric inversions of chromosome 9 with infertility, recurrent abortions, and a number of other abnormal conditions. We report a case of homozygosity pericentric inversions of chromosome 9 in a woman with 28- wk stillbirth. In this case, her both parents were heterozygotes for the inversions of chromosome 9.

**Keywords:** *Pericentric inversions, Chromosome 9, Iran*

## **Introduction**

An inversion occurs when a single chromosome undergoes two breaks and is reconstituted with the segment between the inverted breaks. Inversions are of two types: paracentric (not including the centromere), in which both breaks occur in one arm, and pericentric (including the centromere), in which there is a break in each arm (1). An inversion does not usually cause an abnormal phenotype in carriers, because it is a balanced rearrangement. Its medical significance is for the progeny; a carrier of either type of inversion is at risk of producing abnormal gametes that may lead to unbalanced offspring. When an inversion is present, during meiosis I, a loop will be formed. Although recombination is somewhat suppressed within inversion loops, when it occurs it can lead to production of unbalanced gametes. A pericentric inversion, on the other hand, can lead to the production of unbalanced gametes with both duplication and deficiency of chromosome segments (2).

The most common inversion seen in human chromosomes is a small pericentric inversion of chromosome 9, which is present in 1-3 per cent in the general population (3-6).

The human chromosome 9 displays the highest degree of structural variability (7). The molecular studies of pericentric inversion breakpoints in chromosomes 4, 9 and 12 in human and chimpanzee showed similarity between them (8).

Review of literature showed that inversions of chromosome 9 with different breakpoints could be the cause of different disturbances in carriers. Table 1 shows the associations between the different disturbances and inversion 9 with different breakpoints.

## **Materials and Methods**

A 25 yr-old woman, who had first cousins marriage, was referred to our Genetic Department due to one 28- wk stillbirth. Cytogenetic analysis was performed with GTG-banding technique for her and her husband on their lympho-

cytes and showed that the wife had pericentric inversions on her both chromosomes 9 [46, XX, inv [9] (p11q13) x2] (Fig.1, 2).

Chromosomal study on her parents showed both parents also had inversions of chromo-

somes 9, [father: 46, XY, inv [9] (p11q13) and mother: 46, XX, inv [9] (p11q13)], but her husband had a normal male karyotype [46, XY].

**Table 1:** Associations between the different disturbances and inversion 9 with different breakpoints

Karyotype	Disturbance	Reference
Inv [9] (p11q12)	Recurrent abortion	Sasiadek et al., 1997 (9)
inv[9](p24q13)	Male infertility	Davalos et al., 2000(10)
inv[9]	Male infertility	Sasagawa et al., 1998(11)
inv[9](p24q34.1)	FTT and congenital anomalies in offspring	Shapira et al., 1997(12)
inv(9)	Acute leukemia	Keung et al., 2003 (13)
inv[9](p11q21)	Familial bipolar disorder	Mc Candless et al.,1998(14)
inv[9](p11q13)	Asperger Syndrome	Pia Verri and Cimbri, 2002(15)
inv[9](p11q13)	Goldenhar Syndrome or oculo-auriculo-vertebral spectrum	Stanojevic et al., 2000(16)
inv[9]	Mental retardation	Cora et al., 2000 (17)
inv[9]	Familial schizophrenia	Lee et al., 1998(18)
inv[9]	Immotile/ultrastructural sperm defect	Baccetti et al.,1997(19)
inv[9]	Double aortic arch (CHD)	Brzezinska-Kolarz et al., 1997(20)
inv[9]	Hydronephrosis,encephalocele and prune belly syndrome	Salihu et al.,2001(21)
inv[9](q31.2q34.3)	Schizoaffective disorder, short stature, depressed nasal bridge, hypertelorism and slender shoulders.	Inayama et al.,1997 (22)
inv[9](p11q13)	Schizophrenia-like psychosis	Miyaoka et al.,1999(23)
inv[9],9qh+	Schizophrenia	Demirhan and Tastemir, 2003(24)
inv [9]	Schizophrenia	Kunugi et al.,1999 (25)
inv[9]	Neurofibromatosis	Flego et al.,2003(26)
inv[9](p21)	Neuroblastoma	Stage et al.,2003 (27)
inv[9]	Ectodermal dysplasia	Fuenmayor et al.,1981 (28)
inv[9]	Blepharophimosis Syndrome	Mhanni et al.,1998(29)
inv[9]	Recurrent spontaneous first trimester abortions	Parmar and Sira,2003(30)

## Discussion

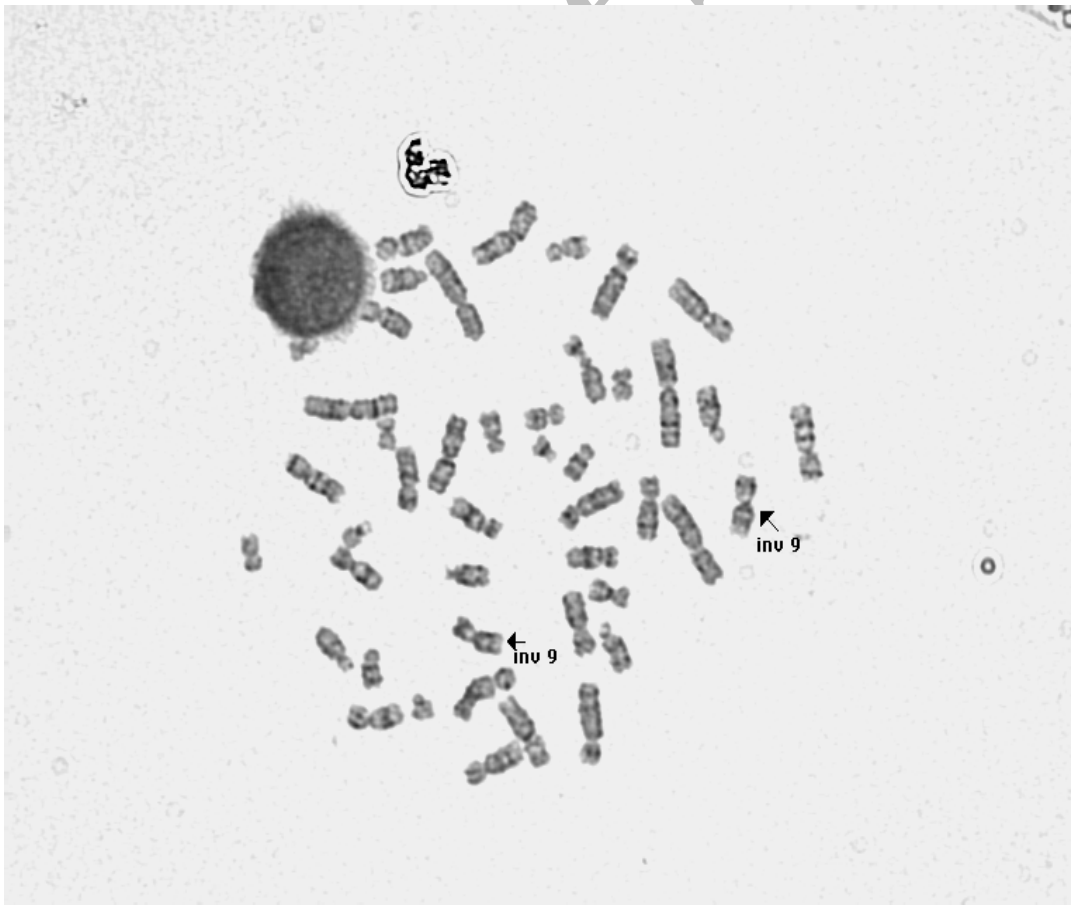
It has been reported that various abnormalities appeared in individuals who have pericentric inversion 9. In 2.3% of the couples with the history of recurrent spontaneous miscarriages, pericentric inversion of chromosome 9 was detected (9). Nevertheless, most of the cytogeneticists believe that there are only one kind of breakpoints (p11q12) on the inversions of chromo-

somes 9, which has no known deteriorated effect on carriers and does not appear to be associated with a significant risk of miscarriage or unbalanced offspring; it is, therefore, generally considered as a normal chromosome variant. It has been suggested that phenotypes of inversion 9 may vary depending on the location of breakpoints (18). We also showed that there were several different forms of inversion 9 with

differential breakpoints, which can cause different abnormalities either in the proband or in his/her children.

The finding of homozygosity for a pericentric inversion of chromosome 9 is rare (3). A report showed a case of homozygosity for inversion 9 in a normal infant which his both parents were heterozygotes for the inv[9] (p11q13). In that paper, there was also another case, which was referred for severe intrauterine growth retardation (IUGR) and oligohydroamnios, and subsequently expired in utero. Chromosome study revealed inv [9] (p11q13) x2 for this case and both parents were heterozygotes for the inv [9] (p11q13) (3). Another paper described homozygous pericentric inversion 9 in a 2-month-old

female baby with eye and brain abnormalities. Her clinical and neuroradiological features were similar to the signs of Walker-Warburg Syndrome. They showed both parents were heterozygotes (31). A newborn was presented with a recto-cloacal fistula and a high confluence of the urino-genital and intestinal systems. It was interesting that although both parents had a chromosome 9 inversion (p11q13), but the child was chromosomally normal (32-33). It is interesting to mention that our case with homozygosity for pericentric inversion of chromosome 9 has not showed any phenotypic abnormality, but the only problem was her stillbirth which was not clear that it was related to her inversion or not.



**Fig. 1:** Pericentric inversions on the both chromosomes 9 in the present case

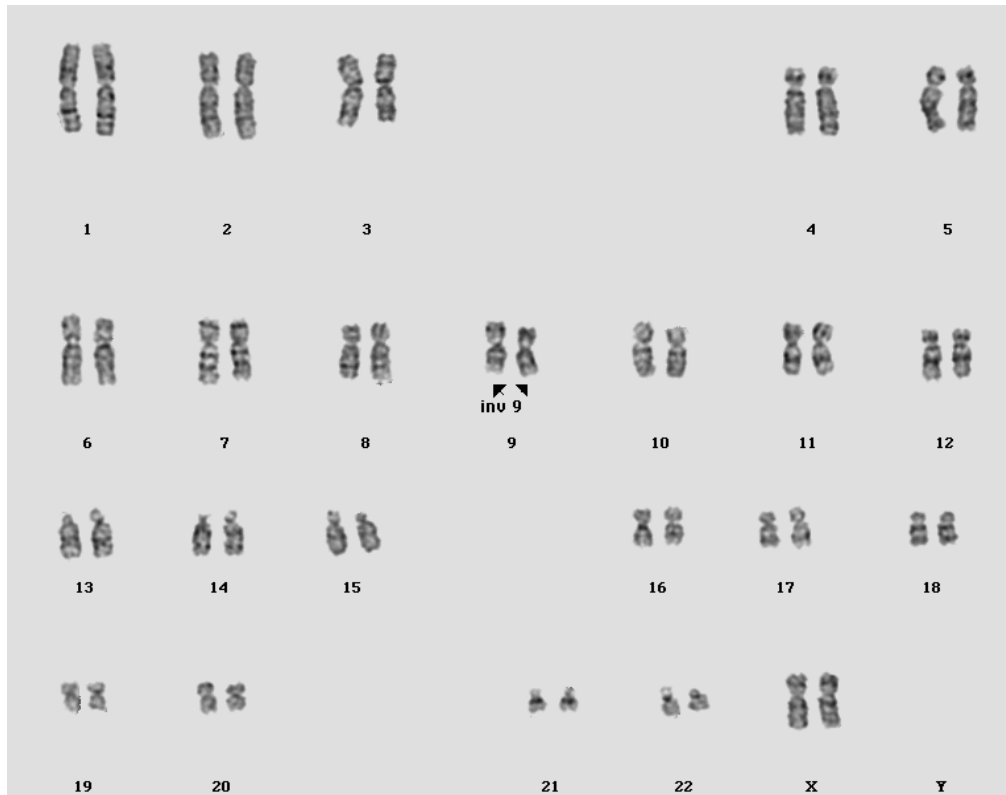


Fig. 2: The karyotype of pericentric inversions on the both chromosomes 9 in the present case

### Acknowledgements

The authors are grateful to our patient and her family for their contribution to this study.

### References

1. Hartl DL (2000). *Our uncertain heritage: Genetics and human diversity*. 5<sup>th</sup> ed. Harper and Row Publishers, New York, pp.: 181-88.
2. Mange AP, Mange EJ (1998). *Genetics: Human aspects*. 4<sup>th</sup> ed. Saunders College, Philadelphia, pp.: 170-72.
3. Cotter PD, Babu A, McCurdy LD, Caggana M, Willne JP, Desnick RJ (1997). Homozygosity for pericentric inversions of chromosome 9. Prenatal diagnosis of two case. *Ann Genet*, 40(4): 222-26.
4. Mokhtar, MM (1997). Chromosomal aberrations in children with suspected genetic disorders. *EMHJ*, 3(1): 114-122.
5. Kim SS, Jung SC, Kim HJ, Moon HR, Lee JS (1999). Chromosome abnormalities in a referred population for suspected chromosomal aberrations: a report of 4117 cases. *J Korean Med Sci*, 14(4): 373-76.
6. Toyota T, Shimizu H, Yamada K, Yoshit-sugu K, Meerabux J, Hattori E, Ichimiya T, Yoshikawa T (2001). Karyotype analysis of 161 unrelated schizophrenics: no increased rates of X chromosome mosaicism or inv [9], using ethnical matched and age-stratified controls. *Schizophr Res*, 52(3): 171-79.
7. Cheong KF, Knight LA, Tan M, Ng IS (1997). Variants of chromosome 9 in phenotypically normal individuals. *Ann Acad Med Singapore*, 26(3): 312-14.
8. Nickerson E, Nelson DL (1998). Molecular definition of pericentric inversion breakpoints occurring during the evolution of

- humans and chimpanzees. *Genomics*, 50(3): 368-72.
9. Sasiadek M, Haus O, Lukasik-Majchrowska M, Slezak Paprocka-Borowicz M, Busza H, Plewa R, Bullo A, Jagielski J (1997). Cytogenetic analysis in couples with spontaneous abortions. *Ginekol Pol*, 68(5A): 248-52.
  10. Davalos IP, Rivas F, Ramos AL, Galaviz C, Sandoval I, Rivera H (2000). Inv [9] (p24q13) in three sterile brothers. *Ann Genet*, 43(1): 51-4.
  11. Sasagawa I, Ishigooka M, Kubota Y, Tomaru M, Hashimoto T, Nakada T (1998). Pericentric inversion of chromosome 9 in infertile men. *Int Urol Nephrol*, 30(2): 203-7.
  12. Shapira SK, Orr-Urtreger A, Gagos S, Shaffer LG (1997). Constitutional mosaicism for a chromosome 9 inversion resulting in recombinant aneuploidy in offspring. *Am J Med Genet*, 69(4): 360-64.
  13. Keung YK, Knovich MA, Powell BL, Buss DH, Pettena M (2003). Constitutional pericentric inversion of chromosome 9 and acute leukemia. *Cancer Genet Cytogenet*, 145(1): 82-5.
  14. McCandless F, Jones I, Harper K, Craddock N (1998). Intrafamilial association of pericentric inversion of chromosome 9, inv [9] (p11-q21), and rapid cyclic bipolar disorder. *Psychiatr Genet*, 8(4): 259-62.
  15. Pia Verri A, Cimbri C (2002). Observation of an Asperger Syndrome's case with a diagnosis in adulthood and a pericentric inversion chromosome 9. *Minerva Psichiatrica*, 43: 38.
  16. Stanojevic M, Stipoljev F, Koprčina B, Kurjak A (2000). Oculo-auriculo-vertebral (Goldenhar) spectrum associated with pericentric inversion 9: coincidental findings or etiologic factor? *J Craniofac Genet Dev Biol*, 20(3): 150-54.
  17. Cora T, Demirel S, Acar A (2000). Chromosomal abnormalities in mentally retarded children in the Konya region, Turkey. *Genet Couns*, 11(1): 53-5.
  18. Lee KB, Kunugi H, Nanko S (1998). Familial schizophrenia with pericentric inversion of chromosome 9: a case report. *Schizophr Res*, 32(2): 123-26.
  19. Baccetti B, Collodel G, Crisa D, Moretti E, Piomboni P (1997). Ultrastructural sperm defects in two men, carriers of autosomal inversion. *Andrologia*, 29(5): 277-82.
  20. Brzezinska-Kolarz B, Sanak M, Musial J, Szczeklik A (1997). Double aortic arch associated with pericentric inversion of chromosome 9. *Kardiol Pol*, 47: 39.
  21. Salihu M, Boos Gisele R, Tchuinguem W, Schmidt H (2001). Prenatal diagnosis of translocation and a single pericentric inversion 9: the value of fetal ultrasound. *J Obstet Gynaecol*, 21(5): 474-477.
  22. Inayama Y, Yoneda H, Fukushima K, Sakai J, Asaba I, Sakai T (1997). Paracentric inversion of chromosome 9 with schizoaffective disorder. *Clin Genet*, 51(1): 69-70.
  23. Miyaoka T, Seno H, Itoga M, Ishino H (1999). A case of small cerebral cyst and pericentric inversion of chromosome 9 that developed schizophrenia-like psychosis. *Psychiatry Clin Neurosci*, 53(5): 599-602.
  24. Demirhan O, Tastemir D (2003). Chromosome aberrations in a schizophrenia population. *Schizophr Res*, 65(1): 1-7.
  25. Kunugi H, Lee KB, Nanko S (1999). Cytogenetic findings in 250 schizophrenics: evidence confirming an excess of the x chromosome aneuploidies and pericentric inversion of chromosome 9. *Schizophr Res*, 40(1): 43-7.
  26. Flego V, Radojčić Badovinac A, Pleše V, Kapović M, Beg-Zec Z, Zaputović L (2003). Malignancy risk in patient with neurofibromatosis and autosomal dominant polycystic kidney disease. *Croat Med J*, 44 (4): 485-88.

27. Satge D, Moore SW, Stiller CA, Niggli FK, Pritchard-Jones K, Bown N, Benard J, Plantaz D (2003). Abnormal constitutional karyotypes in patients with neuroblastoma: a report of four new cases and review of 47 others in the literature. *Cancer Genet Cytogenet*, 147(2): 89-98.
28. Fuenmayor HM, Roldan-Paris L, Bermudez H (1981). Ectodermal dysplasia in females and inversion of chromosome 9. *J Med Genet*, 18(3): 214-17.
29. Mhanni AA, Dawson AJ, Chudley AE (1998). Vertical transmission of the Ohdo blepharophimosis syndrome. *Am J Med Genet*, 77(2): 144 -48.
30. Parmar RC, Sira P (2003). Prenatal diagnosis of partial trisomy 21 associated with maternal balanced translocation 46, XX, der 21 t (21q; 22q) with pericentric inversion of chromosome 9. *J Postgrad Med*, 49(2): 154-56.
31. Baltaci V, Ors R, Kaya M, Balci S (1999). A case associated with walker warburg syndrome phenotype and homozygous pericentric inversion 9: coincidental finding or aetiological factor? *Acta Paediatr*, 88(5): 579-83.
32. Cacciaguerra S, Bianchi A (1998). Concepts and considerations for repair of a severe cloacal anomaly. *EurJ Pediatr Surg*, 8(2): 114-18.
33. Cacciaguerra S, Lo Presti L, Di Leo L, Grasso S, Gangarossa S, Di Benedetto V, Di Benedetto A (1998). Prenatal diagnosis of cloacal anomaly. *Scand J Urol Nephrol*, 32(1): 77-80.

Archive of SJD