



Effect of Wrist Deviation on Median Nerve Cross-Sectional Area at Proximal Carpal Tunnel Level

**Ping Yeap LOH¹, Satoshi MURAKI²*

1. Graduate School of Design, Kyushu University, 4-9-1 Shiobaru, Minamiku, Fukuoka 815-8540, Japan
2. Faculty of Design, Kyushu University, 4-9-1 Shiobaru, Minamiku, Fukuoka 815-8540, Japan

***Corresponding Author:** Email: lohpingyeap@gmail.com

(Received 20 July 2014; accepted 04 Sep 2014)

Abstract

Background: Carpal tunnel syndrome (CTS) is one of the most common musculoskeletal disorders among computer users. Computer users exhibit various wrist angles while typing. Dynamic changes of wrist angle may cause different degrees of median nerve compression. The objective of this study was thus to investigate the effects of the combination of wrist flexion-extension with wrist deviation on median nerve cross-sectional area (MNCSA).

Methods: Eight right-handed participants were recruited in this study. Both wrists were examined by sonographic ultrasound (US) at the proximal carpal tunnel level in the transverse plane. A total of nine wrist positions were examined, including wrist neutral (WN), wrist flexion (WF)30°, and wrist extension (WE)30°, together with three wrist deviation conditions, namely, without radial deviation (RD) and ulnar deviation (UD), with maximal RD and with maximal UD. MNCSA was measured by tracing method with *ImageJ*.

Results: Paired *t*-test showed a significant difference of WN MNCSA between the dominant hand ($7.93 \pm 0.63 \text{ mm}^2$) and the non-dominant hand ($6.98 \pm 0.42 \text{ mm}^2$) ($P < 0.001$). Two-way repeated-measures ANOVA (handedness as an independent factor) showed that WF30° and WE30° caused significant differences of MNCSA when compared with WN ($P < 0.001$). However, wrist RD/UD did not have a significant interaction with the changes of MNCSA in WN, WF and WE positions.

Conclusion: The results indicate a significant reduction of MNCSA when WN changed to WF and WE. Wrist RD and UD did not cause significant changes of MNCSA at different wrist positions.

Keywords: Median nerve, Ultrasound, Wrist active holding, Nerve deformation

Introduction

Computers are widely used in daily work. They have become essential tools in the workplace. Repetitive and awkward positions are associated with musculoskeletal disorders of the upper extremities among computer users (1). Long hours of computer use in daily life have increased the discomfort levels of the neck, shoulder, elbow, and wrist and hand regions. Studies have shown that approximately 20% of computer users experience musculoskeletal disorders of the upper extremities (2, 3). Intensive use of a computer keyboard and a mouse may increase the risk of carpal tunnel

syndrome (CTS), which is one of the most commonly reported musculoskeletal disorders of the upper extremities, in which the median nerve is affected at the carpal tunnel as a result of nerve compression (1). CTS has a multifactorial etiology and mechanical compression stress on the median nerve is one of the relevant factors.

The carpal tunnel is located at the volar wrist and formed by carpal bones as the floor, transverse carpal ligament as the roof and the proximal carpal tunnel defined by the edge of the transverse carpal ligament at the pisiform level (4). The me-

dian nerve and a total of nine tendons enter through the carpal tunnel, which are the flexor pollicis longus (FPL), four flexor digitorum superficialis (FDS) and four flexor digitorum profundus (FDP). The median nerve is located near the flexor retinaculum and is vulnerable to compression stress. Wrist movements comprise flexion, extension, radial deviation and ulnar deviation. Finger dynamic movements were previously shown to impose compression stress on the median nerve from FDS, FDP and FPL gliding motion (5). Dynamic kinematic movements of carpal bones may also influence the carpal tunnel volume during wrist flexion-extension motion (6). Therefore, different wrist angles may cause different levels of compression stress on the median nerve. A comfortable workspace that allows computer users to perform daily work in a good posture is necessary to reduce repetitive strain injuries. However, body posture and joint angles change over time. For example, wrist motions during computer work are dynamic as the wrist changes between flexion and extension simultaneously with radial-ulnar deviation. In a previous study, most computer users showed a higher percentage of wrist extension at 20° with 20° ulnar deviation during computer use (7). Therefore, different wrist angles while working may cause different levels of compression stress on the median nerve. Ultrasound (US) examination has been widely used in different fields, including outside of medicine. In particular, the mechanical compression of carpal tunnel region structures during dynamic wrist motion can be observed by US. Compared with other imaging techniques, US is relatively inexpensive and requires a shorter time to examine the wrist region (1).

The objective of this study was thus to investigate the effect of wrist flexion-extension with radial-ulnar deviation on median nerve cross-sectional area (MNCSA) by using high-resolution US images.

Materials and Methods

Eight right-handed healthy male adults were recruited for this study (Table 1). All the participants were free from signs and symptoms of CTS,

as indicated by a screening test. Phalen's Test, CTS Tinel test and Boston Carpal Tunnel Questionnaire (BCTQ) were conducted for all participants to rule out CTS (8-10). In total, sixteen wrists were included for median nerve ultrasound (US) examination.

US examination was performed with the *GE Healthcare Ultrasound System* (Model LOGIQ e) with a 5-13 mHz transducer (Model 12L-RS), and a gel pad (thickness 7.0 mm; Sonar Pad, Nippon BXI Inc., Japan) was used as the coupling medium for the US examination.

Participants sat upright with the forearm resting on a forearm support on a table during the US examination. A total of nine wrist positions were examined, including WN, WF30°, and WE30°, together with three wrist deviation conditions, namely, without radial deviation (RD) and ulnar deviation (UD), with maximal RD and with maximal UD (Fig. 1). Participants were instructed to maintain these wrist positions and relax their fingers during the US examination. Three US images were taken for each wrist position and the average MNCSA measurement was calculated to represent the wrist angle. MNCSA at WN without RD/UD was used as a reference point when comparing with other wrist positions' MNCSA. MNCSA was measured using *ImageJ* (11) by a tracing method (12) (Fig. 2).

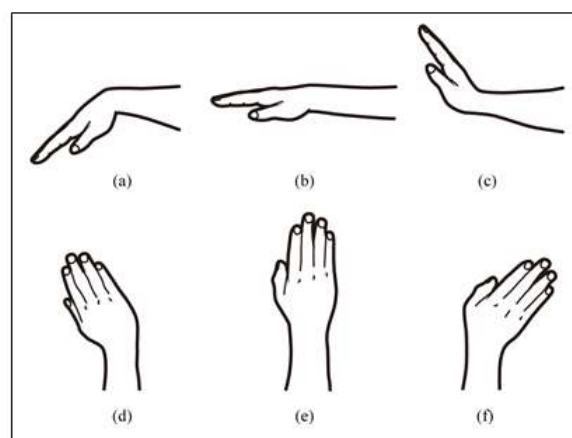
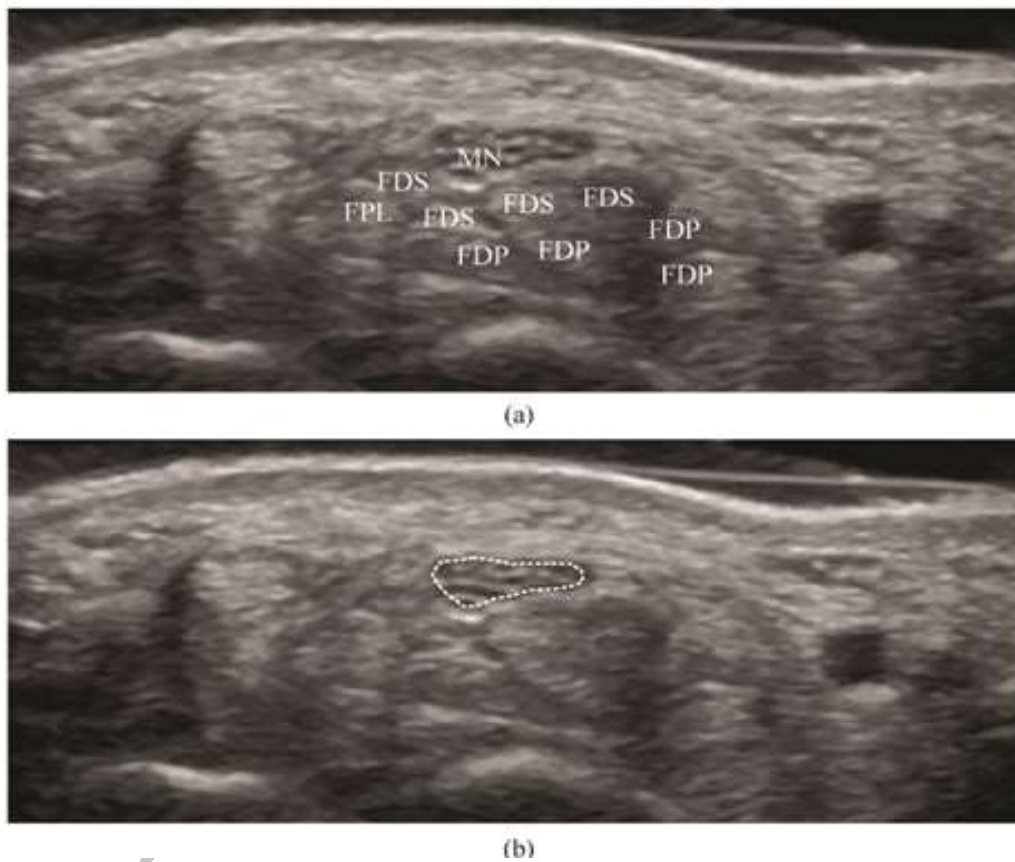


Fig. 1: Wrist position for US examination: (a) wrist flexion; (b) wrist neutral; (c) wrist extension; (d) wrist radial deviation; (e) wrist without deviation; (f) wrist ulnar deviation

Table 1: Demographic data of participants (n = 8)

	Minimum	Maximum	Mean \pm SD
Age (yr)	21.3	31.8	27.0 \pm 3.5
Height (cm)	161.5	182.4	171.6 \pm 6.2
Weight (kg)	51.6	79.0	65.8 \pm 11.1
BMI (kg/m ²)	17.5	26.9	22.3 \pm 3.3
Wrist circumference (cm)			
Right	15.1	16.7	16.0 \pm 0.6
Left	14.7	16.4	15.7 \pm 0.6
Computer use (hours/day)	5	10	8.9 \pm 2.1

**Fig. 2:** (a) Appearance of tendons and median nerve at proximal carpal tunnel; (b) median nerve cross-sectional area measurement by a tracing method

The margin of the median nerve was identified from ultrasound images and its outer hypoechogenic rim was traced accordingly to measure MNCSA. All results are expressed as mean \pm standard deviation (SD). Paired t-test was used to analyze the differences of MNCSA (WN without RD and UD) between the dominant and non-dominant hands. Two-way repeated ANOVA (3 x 3 factorial within-

subjects) was conducted with wrist flexion-extension positions (WF30°, WN and WE30°) and wrist deviation positions (without deviation, RD and UD) as factors to examine the changes of MNCSA at different wrist positions. Post hoc pairwise Bonferroni-corrected comparison was used to examine the mean differences of the factors.

Results

The difference of MNCSA between the dominant hand ($7.93 \pm 0.63 \text{ mm}^2$) and the non-dominant hand ($6.98 \pm 0.42 \text{ mm}^2$) for WN without wrist deviation was significant ($t(9.34) = 7.00$, $P < 0.001$).

The main effect of wrist flexion-extension on MNCSA was significant for both dominant ($F(1.09, 7.622) = 99.45$, $P < 0.001$) and non-dominant hands ($F(1.86, 12.99) = 187.22$, $P < 0.001$). In contrast, the main effect of wrist deviation was not significant for both dominant ($F(1.25, 8.72) =$

4.52 , $P = 0.058$) and non-dominant hands ($F(1.83, 12.81) = 1.77$, $P = 0.210$).

However, the wrist flexion-extension x wrist deviation interaction was not significant for both dominant ($F(2.78, 19.46) = 0.36$, $P = 0.766$) and non-dominant hands ($F(1.39, 9.75) = 0.73$, $P = 0.459$). From Table 2, the MNCSA of WN was larger than those for WF30° and WE30° for all three-wrist deviation positions.

Post hoc pairwise Bonferroni-corrected comparisons showed a significant reduction in MNCSA for both dominant and non-dominant hands when the wrist angle changed from WN to WF30° and WE30° ($P < 0.001$), regardless of the wrist deviation position (Fig. 3).

Table 2: Mean values of MNCSA (mm^2) at each wrist position

Wrist Deviation	Dominant Hand (n = 8)			Non-Dominant Hand (n = 8)		
	Wrist Flexion 30°	Wrist Neutral (0°)	Wrist Extension 30°	Wrist Flexion 30°	Wrist Neutral (0°)	Wrist Extension 30°
Neutral (Without deviation)	6.70 ± 0.46 (5.90 – 7.26)	7.93 ± 0.63 (7.25 – 8.82)	6.80 ± 0.42 (6.04 – 7.29)	5.91 ± 0.50 (5.36 – 6.67)	6.98 ± 0.42 (6.57 – 7.52)	5.92 ± 0.42 (5.44 – 6.54)
Maximal Radial Deviation (RD)	6.69 ± 0.43 (5.98 – 7.20)	7.90 ± 0.60 (7.27 – 8.69)	6.77 ± 0.43 (6.08 – 7.32)	5.87 ± 0.47 (5.28 – 6.61)	6.95 ± 0.40 (6.57 – 7.57)	5.88 ± 0.46 (5.40 – 6.59)
Maximal Ulnar Deviation (UD)	6.67 ± 0.47 (5.86 – 7.28)	7.87 ± 0.62 (7.18 – 8.69)	6.77 ± 0.43 (5.95 – 7.25)	5.90 ± 0.48 (5.39 – 6.69)	6.95 ± 0.42 (6.45 – 7.52)	5.95 ± 0.42 (5.52 – 6.63)

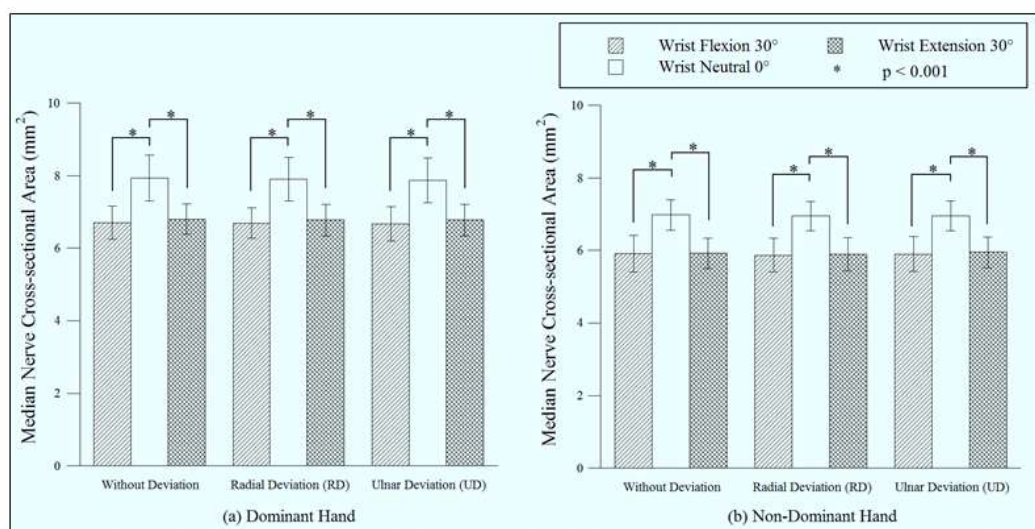


Fig. 3: Comparison of MNCSA among different wrist positions

Discussion

Physical anthropometry studies have shown that humans possess asymmetrical morphology between dominant and non-dominant limbs. For the upper limbs, the girths of the elbow, forearm and wrist were found to differ between right and left arms (13). The analysis shows that right-handed participants have larger MNCSA in the right wrist than in the left wrist, which is in line with Toosi's findings (1).

We have shown that MNCSA decreased when the wrist position changed from neutral to flexion and extension for all wrist deviation positions. From Table 2, the reductions of MNCSA from WN to WF30° and WE30° positions were approximately 7.4 mm² to 6.3 mm². The significant reduction in MNCSA indicated that wrist motion might cause median nerve compression at the proximal carpal tunnel region. Other researchers found that finger joint motions lead to different degrees of compression stress on the median nerve at the carpal tunnel region via US imaging during individual finger or multiple finger flexion-extension motion (5). The carpal tunnel is a confined space with nine tendons and a median nerve. The pathophysiology of CTS suggests that synovial inflammation of the surrounding tissue subjects the median nerve to compression and elicits signs and symptoms of CTS. As the carpal tunnel volume is reduced when the wrist changes from a neutral position to a flexion or extension posture (6), the tendons and median nerve have limited space for mobility. Therefore, a median nerve under compression may experience more friction force at the carpal tunnel during repetitive typing motions.

From Table 2, the mean values of MNCSA of the three deviation positions were about the same during wrist holding in flexion, extension and neutral positions. Our findings show that wrist deviation does not have a significant influence on MNCSA changes, but prolonged deviation of wrist posture in daily tasks may lead to discomfort in the workplace. The frequency of wrist deviation motion increases with the use of computer peripheral devices such as a mouse. However, we do

not have a clear understanding of the long-term effect of wrist deviation on MNCSA. Therefore, an understanding of wrist posture and the impact on wrist muscle fatigue and median nerve compression during computer work is important to minimize the incidence of CTS or reduce the signs and symptoms among the CTS patient group in workplaces.

Wrist posture during computer work is influenced by the keyboard and mouse design, as well as individual posture. In a previous study, nearly 65% of computer users presented with wrist extension and ulnar deviation while typing (7). The dynamic changes of wrist flexion-extension and radial-ulnar deviation angles may increase the compression stress on the median nerve after long hours of computer use. Research has shown that intensive use of a computer for typing in daily work leads to median nerve swelling and an increase in MNCSA (1). The different wrist angles and their impact on median nerve compression are important for better computer workstation ergonomics. Further research is needed to obtain a better understanding of the relationship between different wrist angles and the impact on median nerve deformation.

Conclusions

The reduction of MNCSA was observed through wrist flexion-extension motion, but not wrist deviation motion. Similar MNCSA during wrist flexion and wrist extension positions was found for both dominant and non-dominant hands.

Ethical considerations

This study was approved by the Ethics Committee, Faculty of Design, Kyushu University. All participants were provided with participant information and signed an informed consent form.

Ethical issues (Including plagiarism, informed consent, misconduct, data fabrication and/or falsification, double publication and/or submission, redundancy, etc.) have been completely observed by the authors.

Acknowledgments

The authors received no specific funding for this work. The authors thank all subjects who volunteered to participate in this study. The authors declare that there is no conflict of interest.

References

1. Toosi KK, Impink BG, Baker NA, Boninger ML (2011). Effects of computer keyboarding on ultrasonographic measures of the median nerve. *Am J Ind Med*, 54(11), 826-833.
2. Baker NA, Cham R, Cidboy EH, Cook J, Redfern MS (2007). Kinematics of the fingers and hands during computer keyboard use. *Clin Biomech (Bristol, Avon)*, 22(1), 34-43.
3. Sauter SL, Schleifer LM, Knutson SJ (1991). Work posture, workstation design, and musculoskeletal discomfort in a VDT data entry task. *Hum Factors*, 33(2), 151-167.
4. Presazzi A, Bortolotto C, Zacchino M, Madonia L, Draghi F (2011). Carpal tunnel: Normal anatomy, anatomical variants and ultrasound technique. *J Ultrasound*, 14(1), 40-46.
5. van Doesburg MH, Yoshii Y, Villarraga HR, Henderson J, Cha SS, An KN, Amadio PC (2010). Median nerve deformation and displacement in the carpal tunnel during index finger and thumb motion. *J Orthop Res*, 28(10), 1387-1390.
6. Mogk JPM, Keir PJ (2009). The effect of landmarks and bone motion on posture-related changes in carpal tunnel volume. *Clin Biomech*, 24(9), 708-715.
7. Donoghue MF, O'Reilly DS, Walsh MT (2013). Wrist postures in the general population of computer users during a computer task. *Appl Ergon*, 44(1), 42-47.
8. Bakhsh H, Ibrahim I, Khan W, Smitham P, Goddard N (2012). Assessment of validity, reliability, responsiveness and bias of three commonly used patient-reported outcome measures in carpal tunnel syndrome. *Orthop Traumatol Rehabil*, 14(4), 335-340.
9. LaJoie AS, McCabe SJ, Thomas B, Edgell SE (2005). Determining the sensitivity and specificity of common diagnostic tests for carpal tunnel syndrome using latent class analysis. *Plast Reconstr Surg*, 116(2), 502-507.
10. Sambandam SN, Priyanka P, Gul A, Ilango B (2008). Critical analysis of outcome measures used in the assessment of carpal tunnel syndrome. *Int Orthop*, 32(4), 497-504.
11. Schneider CA, Rasband WS, Eliceiri KW (2012). NIH image to ImageJ: 25 years of image analysis. *Nat Methods*, 9(7), 671-675.
12. Duncan I, Sullivan P, Lomas F (1999). Sonography in the diagnosis of carpal tunnel syndrome. *Am J Roentgenol*, 173(3), 681-684.
13. Rogowski I, Ducher G, Brosseau O, Hautier C (2008). Asymmetry in volume between dominant and nondominant upper limbs in young tennis players. *Pediatr Exerc Sci*, 20(3), 263-272.