



## Multiple Enteroenteric Fistulas- Crohn's Disease- A Case Report

*\*Hasnain Abbas DHARAMSHI<sup>1</sup>, Ali Abbas MOHSIN ALI<sup>2</sup>, Tufail RAZA<sup>3</sup>, Narmeen SHAHID<sup>1</sup>, Faizan SHERAZ<sup>4</sup>, Tooba SAJID<sup>1</sup>, Zohair LILANI<sup>1</sup>, Mustaqueem ur REHMAN<sup>3</sup>, Taha NAFEES<sup>1</sup>*

1. Karachi Medical and Dental College, Karachi, Pakistan
2. Sindh Medical College, Dow University of Health Sciences, Karachi, Pakistan
3. Baqai Medical College, Karachi, Pakistan
4. Army Medical College, Islamabad, Pakistan

**\*Corresponding Author:** Email: dr.hasnain.dh@hotmail.com

(Received 25 May 2015; accepted 11 Aug 2015)

### Abstract

Crohn's disease is a type of chronic inflammatory bowel disease (IBD) of unknown etiology that may affect any part of the gastrointestinal tract from mouth to anus and shows extra-intestinal involvement. It characteristically shows skip lesions. This case report reported in 2014 describes a middle age Pakistani male known to have documented evidence of significant crohn's disease since past 18 years. He was diagnosed with multiple fistulas that are a rare entity of patients with crohn's disease, which is itself a rare disease in Asian countries.

**Keywords:** Crohn's disease, Inflammatory bowel disease (IBD), Multiple fistulas

### Introduction

Crohn's disease is a type of chronic inflammatory bowel disease (IBD) of unknown etiology that may affect any part of the gastrointestinal tract from mouth to anus (1, 2). It typically presents as a recurrent course of patchy transmural inflammation with normal intestinal mucosa in between the diseased part followed by relapses (3, 4). It also manifests with extra intestinal complications most common being arthralgias/arthritis, and cutaneous, ophthalmologic and hepatobiliary manifestations (5). Smoking is considered as an important risk factor (5). The treatment of this incurable disease aims at reducing the disease process, decreasing the number of relapses and improving the quality of life (6).

This case report describes a middle age Pakistani male known to have documented evidence of significant crohn's disease since past 18 years. He is

diagnosed with multiple fistulas that are a rare entity of patients with crohn's disease, which is itself a rare disease in Asian countries.

### Case Report

A 39 years old Pakistani male with a past history of significant crohn's disease since last 18 years presented to emergency room with severe supra pubic abdominal pain as well as dysuria and pneumaturia since 2-3 weeks in 2014. He also complained of questionable fecal contamination of his urine in same year. He denied the presence of fever, chills, nausea and vomiting in his presenting complains and stated that he had normal bowel movements over the past one week.

The patient stated that he had occasional nausea and vomiting, crampy abdominal pain with bloat-

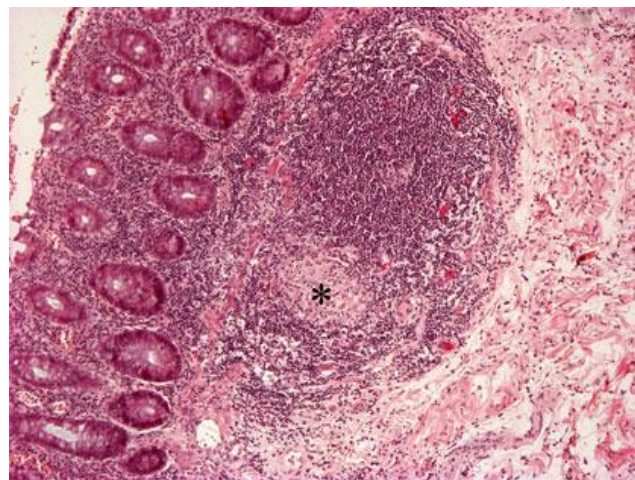
ing associated with meal intake and occasional diarrhea since 18 years leading to significant weight loss of 15 pounds over the previous 1-2 months. He denied any extra intestinal manifestations of his disease.

He was medically managed on infliximab for approximately 10 years but switched later to cetolizumab due to episodes of exaggerations between the doses. The next drug also failed after 1-2 months as he started having acute exaggerative episodes in the last few months. He had pre-operative colonoscopy, a year ago, after which he was recommended exploratory laparotomy with possible resection of diseased bowel and stricturoplasty by his primary GI doctor but he denied it due to financial reasons. He completed a 2-week course of ciprofloxacin + metronidazole and a week course of prednisone for his symptoms and became asymptomatic with the treatment. One week after completion of symptomatic treatment, he became symptomatic again and was progressively getting worse.

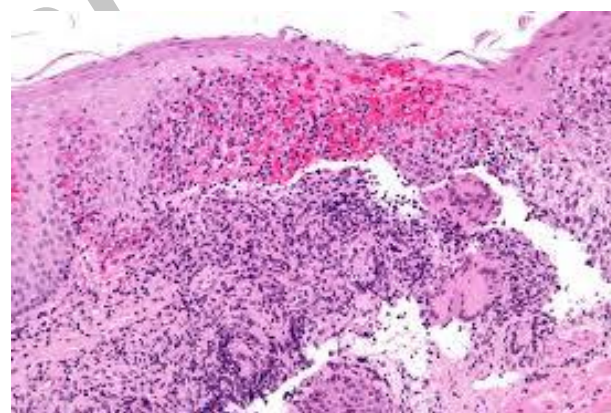
Of all his past record of I.V with oral contrast CT scans, the latest one that was performed approximately a year ago stated that the patient had moderately distended small bowel, compatible with small bowel obstruction, due to significant inflammatory edematous thickening of the terminal ileum. There was also evidence of multiple enteroenteric fistulas. In addition, there was an inflamed small bowel loop inseparable from the superior wall of bladder with presence of gas in the urinary bladder demonstrating evidence of entero-vesicular fistula. The overall configuration suggested complications related to chronic inflammatory bowel disease (Crohn's disease in particular) (Fig. 1 and 2).

He also had colonoscopy a year ago that showed classical features of chronic inflammatory disease with tubulization in the cecum, ascending colon and proximal transverse colon as well as sigmoid colon and rectum except that there were no ulcerations present. The distal transverse colon and the entire descending colon appeared to be free of obvious disease. A flat carpet like polyp was also seen at ano-rectal junction. Overall pattern sug-

gested of skip lesions with anal involvement classical for crohn's disease.



**Fig.1:** High magnification image of Crohn's disease \*showing granuloma



**Fig.2:** Inflammatory cells- Crohn's disease

He was negative for family history of inflammatory bowel disease; however, his mother was hypertensive. He does not drink but was a social smoker positive for tobacco abuse but was not ready to quit. Besides his presenting complains, the review of other systems was normal.

The study was approved by Ethical Committee board. Informed consent was taken from patient.

## Acknowledgements

The authors declare that there is no conflict of interests.

## References

1. Klein S, Kinney J, Jeejeebhoy K, Alpers D, Hellerstein M, Murray M, Twomey P (1997). Nutrition support in clinical practice: review of published data and recommendations for future research directions. *Am J Clin Nutr*, 66(3): 683-706.
2. Lee, Kang M, Ji ML (2014). Crohn's disease in Korea: past, present, and future. *Korean J Intern Med*, 29(5): 558-570.
3. Samuel D James, Paul E Wise, Tania Zuluaga-Toro et al. (2014). Identification of pathologic features associated with "ulcerative colitis-like" Crohn's disease. *World J Gastroenterol*, 20(36): 13139-13145.
4. Giuseppe S Sica, Sara Di Carlo, Giorgia Tema et al. (2014). Treatment of peri-anal fistula in Crohn's disease. *World J Gastroenterol*, 20(37): 13205-13210.
5. Ott C, Taksas A, Obermeier F et al. (2014). Smoking increases the risk of extraintestinal manifestations in Crohn's disease. *World J Gastroenterol*, 20 (34): 12269-76.
6. Magalhães J, Castro FD, Carvalho PB, Moreira MJ, Cotter J (2014). Quality of life in patients with inflammatory bowel disease: importance of clinical, demographic and psychosocial factors. *Arq Gastroenterol*, 2014;51(3):192-7.

Archive of SID