

CRANIOSPINAL VERSUS WHOLE BRAIN IRRADIATION IN MEDULLOBLASTOMA PATIENTS, WITH INTRODUCTION OF UTILIZING A SIMPLE IMMOBILIZATION DEVICE

P. Haddad¹, H. Behruzi¹, K. Dehshiri¹ and B. Zarpak²

1- Department of Radiation Oncology, Cancer Institute, Tehran University of Medical Sciences, Tehran, Iran

2- Department of Mathematics and Statistics, Shahed University, Tehran, Iran

Abstract - Craniospinal irradiation plus posterior fossa boost (CSI) is the standard modality for post-operative treatment of patients with medulloblastoma, but considering the technical difficulties and limited facilities, often whole-brain irradiation plus posterior fossa boost (WBI) had been used in our institution until 1991. Thus a retrospective study was undertaken to compare the patients treated by WBI and CSI for recurrences and disease-free survival (DFS).

Files of all medulloblastoma patients treated post-operatively in our department in the 10-year period of 1986-1996 were reviewed. To obtain the best possible follow-up, a formal inquiry letter was mailed to all patients' addresses.

Total of 72 patients had been treated, with a mean age of 14.7 years and male-to-female ratio of 1.5:1. Thirty-seven patients had been treated by WBI and 35 by CSI. A simple wooden device designed and made in our department was used for CSI patients' set-up and immobilization. Mean radiation dose to posterior fossa was 4,795 cGy in WBI and 5,071 cGy in CSI (180-200 cGy fractions). Sixty-two patients (85%) came back for follow-up, with 24 recurrences. Only 24% of CSI patients had recurrences, versus 51% in WBI. Nearly all WBI recurrences versus half of the CSI recurrences were spinal. DFS was 39 months in CSI and 26 months in WBI ($p < 0.001$). In multi-factorial analysis, only the extent of radiation (CSI versus WBI, $p < 0.001$) was statistically significant.

Mean age in our patients was higher than what is commonly reported in literature. The immobilization device introduced was a simple and useful accessory to CSI. Considering DFS, CSI in our department was acceptably comparable to literature results and significantly superior to WBI. With regard to relatively high spinal recurrence rate even in CSI, the importance of suitable spinal cytological and imaging evaluation is again emphasized.

Acta Medica Iranica 39 (1): 1-6; 2001

Key Words: Medulloblastoma, craniospinal irradiation, immobilization device

INTRODUCTION

Medulloblastoma is one of the most common tumors among children, and its standard treatment includes total or near-total resection followed by irradiation to the full neuraxis. Craniospinal irradiation has long been the standard of radiotherapy for medulloblastoma, but this is one of the most complicated of the routine radiotherapy techniques requiring multiple fields to cover the entire subarachnoid space and demanding exact attention to technical details, specially to the gaps between radiation fields, to minimize the danger of overdosed or underdosed areas.

Considering the technical demands of craniospinal irradiation, before 1990s many medulloblastoma patients in our department were treated with whole-brain fields (plus posterior fossa boosts), some receiving the spinal radiotherapy at a later time. This was due to policies current then and resulted from the heavy workload of the department and lack of suitable supporting staff and facilities. After 1991, craniospinal irradiation was the standard policy of the department. Thus we decided to compare the treatment results between patients who had and had not received full neuraxis irradiation.

MATERIALS AND METHODS

Files of all patients with a diagnosis of medulloblastoma referred to our radiotherapy department during the 10-year period of 1986-1996 were retrospectively reviewed. All patients who had been referred soon after their primary surgery were included; thus the patients who were sent for radiotherapy after tumor recurrence were not studied.

To obtain the best possible follow-up, a formal inquiry letter was mailed to all patients' addresses, asking for information about their latest disease status.

This report was presented in part at the XV Asia Pacific Cancer Conference, December 1999, Chennai (Madras), India.

Follow-up duration was calculated from the last day of radiotherapy until the date last seen alive or the date of death.

Statistical analysis was performed by chi-square test to determine the significance of various findings; life-tables statistics was used to determine the proportion of patients surviving various periods of time free of disease, and Kaplan-Meier survival analysis with log-rank test was used to compare disease-free survival durations. Multifactorial assessment was done by Cox regression analysis. The statistical software used was SPSS 9.0.

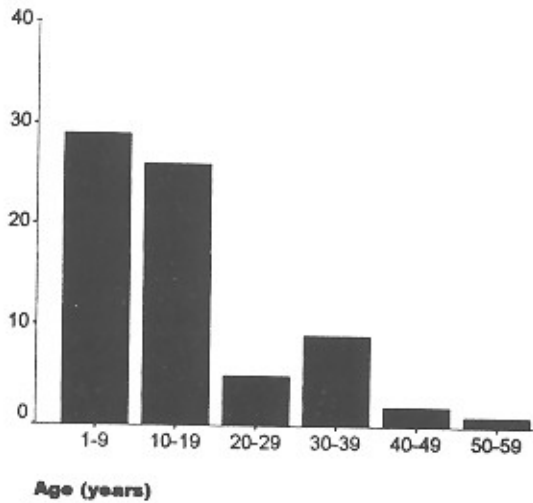


Fig. 1. Age of the patients shown by the number of patients in each decade of life

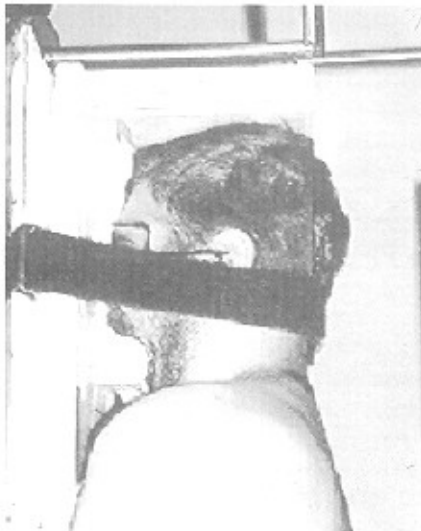

Fig. 2. Patient set-up for craniospinal irradiation with the help of a simple wooden immobilization device

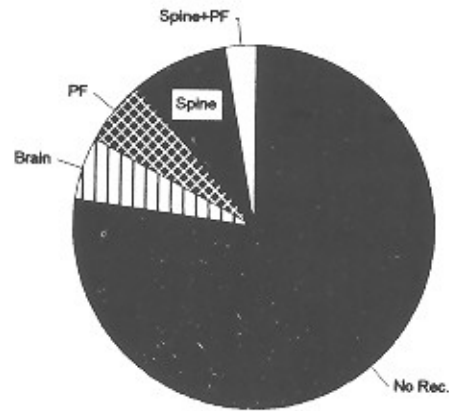


Fig. 3. Recurrences and sites of recurrence in the patients treated by craniospinal irradiation.

PF = posterior fossa, Rec. = recurrence

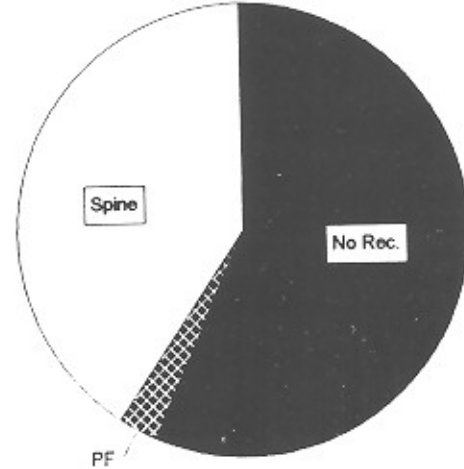


Fig. 4. Recurrences and sites of recurrence in the patients treated by whole-brain irradiation.

PF = posterior fossa, Rec. = recurrence

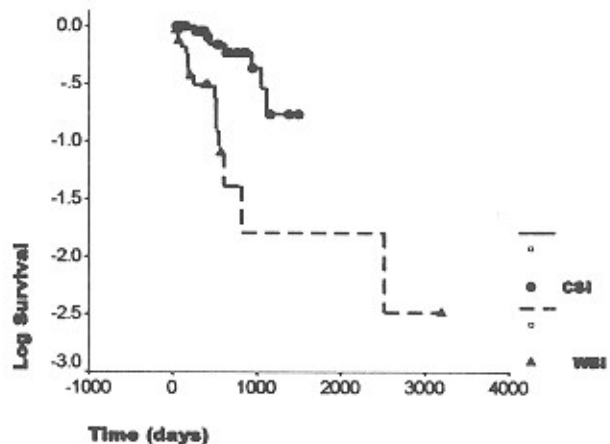


Fig. 5. Disease-free survival in the patients treated by craniospinal irradiation (CSI) versus whole-brain irradiation (WBI)

RESULTS

During 1986-1996, a total of 73 patients with medulloblastoma were referred to our department. One of these patients had been referred after tumor recurrence without prior radiotherapy following the primary surgery, and was excluded from the study.

Of the remaining 72 patients, 45 (62.5%) were male and 27 (37.5%) female, showing a male-to-female ratio of 1.5:1.

Mean and median age were 14.7 and 11.5 years respectively (SD=10.9), with a range of 1-53 years. Most patients were in the first (no.=29) and second (no =26) decades of life (Fig. 1).

Adult patients (age 15 or older) made up 35% of the study population, with a mean and median age of 27 years. The mean and median age in the pediatric group (less than 15 years old) was 8 years. The male-to-female ratio in the adult and pediatric groups was not different.

Most patients (66%) had referred to their neurosurgeon with the primary symptoms of headache, nausea and vomiting. Nearly all patients had been evaluated pre-operatively by computerized tomography (CT) scanning. Only in one patient, magnetic resonance imaging (MRI) had been used in addition to CT scanning.

Tumor site was 74% in cerebellar vermis and the remainder equally in either cerebellar hemispheres. Biopsy had only been performed in 10, subtotal surgery in 27 and near-total or total surgery in 35 patients.

Pathologically tumor size was 0.5-8 cm, with a mean and median of 3 cm (SD= 1.65). Ten cases were classified as desmoplastic, 1 as spongioblastic and 1 as undifferentiated medulloblastoma. According to operation notes and/or 41 post-operative CT scans, tumor residue was present in 40 patients (56%). Shunting had been used to control hydrocephaly in 34 patients (47%).

Cerebrospinal fluid (CSF) cytology had been performed in only 4 patients, with a positive result in two. None of the patients had been evaluated by myelography or spinal MRI.

In the neurological examinations performed in our department, 30 patients (41%) had some abnormalities in cerebellar tests.

Interval between surgery and radiotherapy was 1-7 months. Most patients had been irradiated 1-2 months after surgery.

Radiotherapy was given by cobalt-60 systems in all cases and included craniospinal irradiation plus posterior fossa boost (CSI) in 35 patients (49%) and whole-brain irradiation plus posterior fossa boost (WBI) in 37 (51%). WBI was mostly done before 1991, and after this time CSI was usually used. Two of the WBI patients were given spinal radiotherapy about 1 month

after the brain irradiation.

Most CSI treatments were performed with the help of a simple wooden immobilization device which was specially designed and made for this purpose in our department (Fig. 2). This device has a fixed resting place for patients' frontal area and movable chin rests with different heights for patients of different sizes. Grooves provide the possibility of placing perspex sheets, and rulers make for an acceptable reproducibility.

The junction between brain and upper spinal fields was adjusted by suitable couch and collimator angles. In CSI treatments, mean doses for brain, spinal canal and posterior fossa were 3,286, 3,165 and 5,071 (min. 4,040 max. 5,400) cGy. In WBI, mean doses for brain and posterior fossa were 3,730 and 4,778 (min. 1,800 max. 5,600) cGy. Lower doses were usually used for younger children, and in one case only 1,800 cGy whole-brain irradiation could be prescribed to a one-year old child, with adjuvant chemotherapy. During irradiation, drops of white blood cells counts resulted in a temporary treatment halt in 6 patients. Also one patient had shunt occlusion needing surgical intervention. Other than this, no significant acute effects were found.

Adjuvant chemotherapy was used in 30 patients (47%) by decision of the treating physician. This included 11 CSI and 19 WBI patients. The drugs used were mostly lomustine (CCNU) and vincristine.

Despite all efforts, no information was found after radiotherapy for 10 (8 WBI and 2 CSI) patients. If the 10 patients with no follow-up (F/U) were excluded, mean F/U was 19 months (range 2-106 months) in the remaining 62 patients.

In the 62 patients with F/U, the number of recurrences was 24 (38%). This included 8 recurrences out of 33 CSI patients (25%) and 16 recurrences out of 29 WBI patients (55%). The difference of the number of recurrences in two groups was statistically significant ($p < 0.01$). There was no significant difference between the number of recurrences in adult and pediatric patients, neither in the whole population nor the CSI/WBI groups ($p > 0.05$).

Sites of recurrence in CSI (Fig. 3) included 3 in spine, 2 in posterior fossa, 1 in both posterior fossa and spine and 2 in other areas of brain (frontal area). But in WBI, nearly all recurrences occurred in spine: the other one recurrence was in posterior fossa (Fig. 4). The difference of the number of recurrences in spine reached statistical significance ($p < 0.05$). Also from the 2 patients given spinal radiotherapy after brain irradiation in the WBI group, one recurrence was found in spine.

In life-tables statistics, the 2-years disease-free survival (DFS) was 62% in CSI and 21% in WBI. Kaplan-Meier survival analysis was used to determine the DFS duration. This showed a markedly higher DFS

in CSI (Fig. 5) with a mean of 39 months for CSI and 26 months in WBI patients. By log-rank test, the difference of DFS between CSI and WBI was very significant ($p < 0.01$).

But log-rank test did not show DFS to be significantly different between adult and pediatric patients, neither in the whole population nor the CSI/WBI groups ($p > 0.05$).

Multi-factorial assessment of various factors affecting DFS duration was performed by Cox-regression analysis on age, sex, shunt placement, tumor size, tumor residue, extent of radiotherapy (CSI or WBI), total posterior fossa dose and use of adjuvant chemotherapy. Among these, only the radiotherapy extent was statistically significant ($p < 0.001$).

Treatments after recurrence included surgery, radiotherapy to the untreated spine, chemotherapy or a combination of them. Seven deaths were recorded (all after recurrence of the tumor), 6 in WBI and 1 in CSI patients.

DISCUSSION

Medulloblastoma is one of the most common tumors among children, with a peak incidence between 5 and 10 years (1). Accordingly in our study most patients were in the first decade of life and in the pediatric group (age < 15). The mean and median age was 8 years. But the ratio of adult medulloblastoma (age 15 or older) in our study population was 35%, which is different to the 15-20% mentioned in standard oncology texts (1,2), though very close to the 34% reported from the Piedmont population, Italy (3). Mean and median age of our adult patient population was 27 years, which was similar to the median age of about 25 years generally mentioned for adult medulloblastoma (1).

Excess of males has been noted in many medulloblastoma studies. The male-to-female ratio in both pediatric and adult groups of our study was 1.5, in contrast to 2.1 in Denmark pediatric population (4) and 2.5 in Piedmont adult population (3).

Staging in nearly all patients included only pre- or post-operative CT scanning. Spinal MRI or myelography had not been performed at all, and CSF cytology had been performed in only 4 patients. This partly resulted from difficult access to MRI in Iran in the study period and may somewhat explain the relatively large number of spinal recurrences seen. Considering this incomplete staging, the patients' risk status could not be judged accurately, though 56% had some tumor residue.

In half of the patients, treated mostly before 1991,

the spinal canal had not been irradiated (WBI group). This was due to policies current at that time and resulted from the heavy workload of the department and lack of suitable supporting staff and facilities. After that time, craniospinal irradiation was the policy of the department and simple immobilizing devices, such as the wooden device in figure 2, were used for patients' set-up. This device, though not elegant, was a great help for quick and reproducible set-up of the patients. The doses used for CSI were within the standards of treatment for medulloblastoma, usually somewhat lowered for smaller children.

As expected in the WBI group with their untreated spine, the number of recurrences was markedly higher than the CSI group (55% vs. 25%, $p < 0.01$) and nearly all the recurrences occurred in spine. But in the CSI patients too the number of spinal recurrences was relatively high; half of the recurrences occurred in spine. As said before, this might have partly resulted from the lack of spinal imaging and CSF cytology, the positive result of which either pre- or post-operatively predicts for a poor outcome (5). Patients in the CSI group had a much higher DFS duration ($p < 0.01$). The 2-years DFS was 62% in these patients, which compared acceptably with the results presented in literature (6,7) considering the incomplete pre-treatment evaluations. Notably, the only factor with a significant effect on DFS in multifactorial analysis was the radiotherapy extent (CSI vs. WBI, $p < 0.001$). None of the other factors tested, including age, sex, tumor size, presence of CSF shunts, post-operative residue, radiation dose, and adjuvant chemotherapy, showed statistical significance.

Age (excluding very young children in whom lower radiation doses were used) has generally not been seen important and comparable survivals have been mentioned for children and adults (8,9). Our study too did not show any statistically significant difference between the number of recurrences or DFS of pediatric and adult patients, and this was the case in the CSI and WBI groups in addition to the total patient population.

But other studies have found sex to be a significant risk factor favoring females, both in children (10) and adults (8). Tumor size (2) or the amount of tumor residue after surgery (1,11) is an important risk factor, though not statistically shown to be the same here.

CSI in the study patients was mostly given with full and reasonably constant neuraxis (3,000-3,600 cGy) and posterior fossa (5,000-5,400 cGy) doses. Lower radiation doses to the primary site predispose to a worse survival (11,12). While some authorities propose that using a lower radiation dose in the cerebrospinal axis with chemotherapy and treating the posterior fossa to the full dose might lead to the same survival with less late effects (13), others suggest that lowering the neuraxis radiation dose is harmful (14) and that

chemotherapy can not replace adequate radiation dosing in this setting (12). Chemotherapy, of course was not used in a systematic manner in our patients, and no conclusion can be drawn about its use in medulloblastoma from this study. Others have emphasized its use in either all or the high-risk medulloblastoma patients (11,15,16), but there is no consensus about timing of the chemotherapy in relation to irradiation. Some studies show increased risk of disease progression (17) or subsequent radiotherapy myelosuppression (18) with longer pre-irradiation chemotherapies, while others emphasize its use before radiotherapy (6), before and after radiotherapy (19) or during and after radiotherapy (13).

No serious side effect of radiotherapy was seen in this study, though with a longer and more complete follow-up the late effects would certainly present themselves. Other studies have found neuropsychologic defects, impaired growth hormone secretion, shorter spine, hypothyroidism, and second cancers as serious delayed effects in medulloblastoma survivors treated at a young age (20-24).

In conclusion, mean age in our patients was higher than what is commonly reported in literature, and the study showed a 35% rate of adult medulloblastoma. The immobilization device introduced was a simple and useful accessory to CSI. Considering the number of relapses and DFS, CSI in our department was acceptably comparable to literature results and significantly superior to WBI. With regard to relatively high spinal recurrence rate even in CSI, the importance of suitable spinal imaging evaluation and CSF cytology prior to treatment is again emphasized.

Acknowledgement

The authors wish to thank Dr. Hooman Dehdad for his role in early CSI treatments in our department.

REFERENCES

1. Wara WM, Bauman GS and Sneed PK. Brain, brain stem and cerebellum. In: Perez CA, Brady LW, editors. Principles and practice of radiation oncology. 3rd ed. Philadelphia: Lippincott-Raven Publishers; 1998: 777-828.
2. Prados MD and Wilson CB. Neoplasms of the central nervous system. In: Holland IF, Bast RC, Morton DL, Frei E, Kufe DW, Weichselbaum RR, editors. Cancer medicine. 4th ed. Baltimore: Williams & Wilkins; 1997:1471-1514.
3. Giordana MT, Schiffer P and Lanotte M. Epidemiology of adult medulloblastoma. *Int. J. Cancer*; 80(5):689-92; 1999.
4. Agerlin N, Gjerris F and Brincker H. Childhood medulloblastoma in Denmark 1960-1984: A population-based retrospective study. *Childs Nerv Syst*. 15(1):29-36; 1999.
5. Miralbell R, Bieri S and Huguenin P. Prognostic value of cerebrospinal fluid cytology in pediatric medulloblastoma; Swiss Pediatric Oncology Group. *Ann. Oncol.* 10(2):239-41; 1999.
6. Brandes AA, Palmisano V and Monfardini S. Medulloblastoma in adults: clinical characteristics and treatment. *Cancer Treat Rev.* 25(1):3-12; 1999.
7. Danjoux CE, Jenkin RD and McLaughlin J. Childhood medulloblastoma in Ontario, 1977-1987: population-based results. *Med. Pediatr. Oncol.* 26(1): 1-9; 1996.
8. Le QT, Weil MD and Wara WM. Adult medulloblastoma: an analysis of survival and prognostic factors. *Cancer J. Sci. Am.* 3(4):238-45; 1997.
9. Giordana MT, Cavalla P and Dutto A. Is medulloblastoma the same tumor in children and adults? *J. Neurooncol.* 35(2):169-76; 1997.
10. Weil MD, Lamborn K and Edwards MS. Influence of a child's sex on medulloblastoma outcome. *JAMA.* 13279(18):1474-6; 1998.
11. Zeltzer PM, Boyett JM and Finlay IL. Metastasis stage, adjuvant treatment, and residual tumor are prognostic factors for medulloblastoma in children: conclusions from the Children's Cancer Group 921 randomized phase III study. *J. Clin. Oncol.* 17(3):832-45; 1999.
12. Saran FH, Driever PH and Thilmann C. Survival of very young children with medulloblastoma (primitive neuroectodermal tumor of the posterior fossa) treated with craniospinal irradiation. *Int. J. Radiat. Oncol. Biol. Phys.* 42(5):959-67; 1998.
13. Goldwein JW, Radcliffe J and Johnson J. Updated results of a pilot study of low dose craniospinal irradiation plus chemotherapy for children under five with cerebellar primitive neuroectodermal tumors (medulloblastoma). *Int. J. Radiat. Oncol. Biol. Phys.* 34(4):899-904; 1996.
14. Deutsch M, Thomas PR and Krischer J. Results of a prospective randomized trial comparing standard dose neuraxis irradiation (3,600 cGy/20) with reduced neuraxis irradiation (2,340 cGy/13) in patients with low-stage medulloblastoma; A Combined Children's Cancer Group-Pediatric Oncology Group Study. *Pediatr. Neurosurg.* 24(4):167-176; 1996.

15. Calaminus G, Janssen G and Lenard HG. Combined therapy of medulloblastoma: review of 46 patients treated in a single institution. *Neuropediatrics*. 29(2): 102-7; 1998.
16. Urban C, Benesch M and Pakisch B. Synchronous radiochemotherapy in unfavorable brain tumors of children and young adults. *J. Neurooncol*. 39(1):71-80; 1998.
17. Hartsell WF, Gajjar A and Heideman RL. Patterns of failure in children with medulloblastoma effects of preirradiation chemotherapy. *Int. J. Radiat. Oncol. Biol. Phys.* 39(1):15-24; 1997.
18. Kortmann RD, Kuhl J and Timmermann B. Postoperative neoadjuvant chemotherapy before radiotherapy as compared to immediate radiotherapy followed by maintenance chemotherapy in the treatment of medulloblastoma in childhood: results of the German prospective randomized trial HIT 91. *Int. J. Radiat. Oncol. Biol. Phys.* 46(2):269-79; 2000.
19. Lopez-Aguilar E, Sepulveda-Vildosola AC and Rivera-Marquez H. Survival of patients with medulloblastoma treated with carboplatin and etoposide before and after radiotherapy. *Arch. Med. Res.* 29(4):313-7; 1998.
20. Mulhern RK, Kepner JL and Thomas PR. Neuropsychologic functioning of survivors of childhood medulloblastoma randomized to receive conventional or reduced-dose craniospinal irradiation: a Pediatric Oncology Group study. *J. Clin. Oncol.* 16(5):1723-81; 1998.
21. Heikens I, Michiels EM and Behrendt H. Long-term neuro-endocrine sequelae after treatment for childhood medulloblastoma. *Eur. J. Cancer*. 34(10): 1592-7; 1998.
22. Kiltie AE, Lashford LS and Gattamaneni HR. Survival and late effects in medulloblastoma patients treated with craniospinal irradiation under three years old. *Med. Pediatr. Oncol.* 28(5):348-54; 1997.
23. Chin D, Sklar C and Donahue B. Thyroid dysfunction as a late effect in survivors of pediatric medulloblastoma/primitive neuroectodermal tumors: a comparison of hyperfractionated versus conventional radiotherapy. *Cancer*. 80(4):798-804; 1997.
24. Goldstein AM, Yuen I and Tucker MA. Second cancers after medulloblastoma: population-based results from the United States and Sweden. *Cancer Causes Control*. 8(6):865-71; 1997.