

CONGENITAL CYSTIC ADENOMATOID MALFORMATION OF THE LUNG ASSOCIATED WITH MEDIASTINAL SHIFT

M. Pourissa and S. Refahi

Department of Ultrasonography, Faculty of Medicine, Tabriz University of Medical Sciences, Tabriz, Iran

Abstract - Congenital cystic adenomatoid malformation of the lung (CCAML) is a rare lesion and is characterized by a multicystic mass of pulmonary tissue with an abnormal proliferation of bronchial structures. We report a case of CCAML type I presenting with heart displacement that was diagnosed prenatally.

Acta Medica Iranica 39 (1): 51-53; 2001

Key Words: Prenatal ultrasonography, congenital cystic adenomatoid malformation of the lung

INTRODUCTION

Congenital cystic adenomatoid malformation of the lung (CCAML) is an uncommon congenital anomaly (1). The cause of CCAML is described as developmental arrest of the lung (2). CCAML represents 25% of all congenital lung lesions. One theory regarding pathogenesis of CCAML is that it represents a failure of normal maturation of bronchiolar structures occurring around the sixth week of gestation (3). The authors describe a case of type I congenital cystic adenomatoid malformation of the lung (CCAML) associated with a severe mediastinal shift.

Case report

A 38-year-old woman, gravida 3, para 2 was admitted at 28 weeks of gestation in the department of ultrasonography because of fetal abnormalities. Parents were healthy and first-degree cousins. The mother's first and second pregnancy had resulted in two healthy boys.

The mother did not report any history of drugs, teratogens, vaccination, X-ray or illnesses during her early pregnancy with the fetus described in this report. Prenatal ultrasonography was (US) performed. Fetus was male and had a massive hyperchoic multicystic mass in the right lung with resultant severe heart shift to the left side of the chest (Fig. 1). There was polyhydramnios due to esophageal compression.

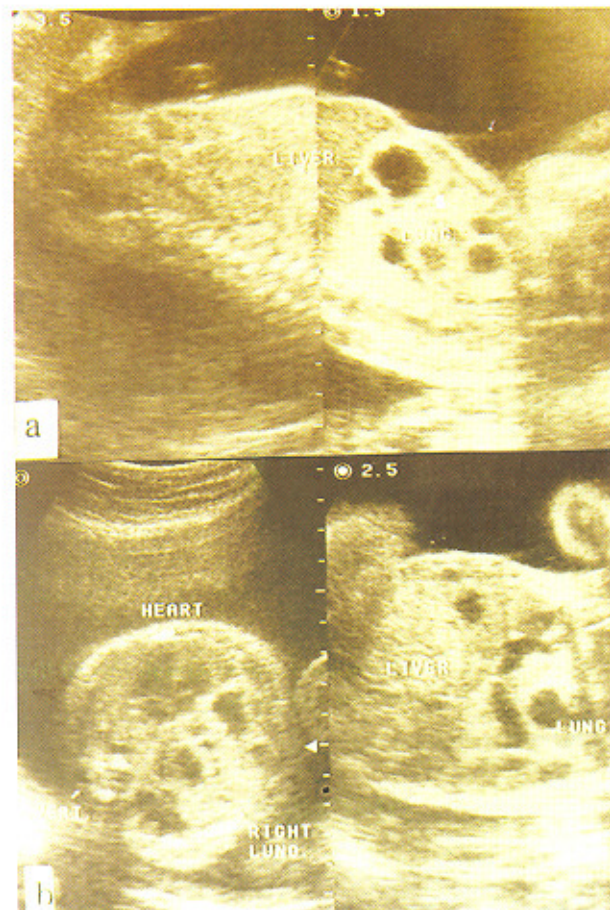


Fig. 1. Sonogram of the fetus shows a: multiple cystic adenomatoid mass of the right lung, b: associated with mediastinal shift to the left side of the chest.

The prenatal ultrasonography examination was repeated at 29 weeks gestation, and demonstrated fetal death. Therefore, pregnancy was terminated by cesarean section and CCAML was confirmed. Histological examination findings showed CCAML type I of Stocker's classification (Fig. 2).

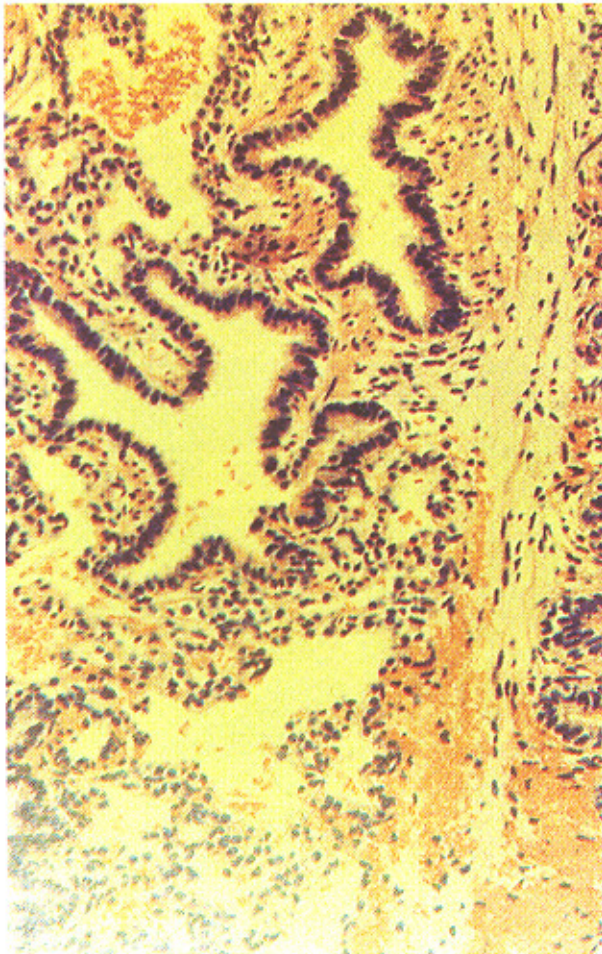


Fig. 2. The lesion histologically consists of multiple cyst-like spaces lined by bronchiolar epithelium.

DISCUSSION

Marked improvements in the resolution of ultrasonography (US) in the past ten years have increased our ability to diagnose fetal anomalies in utero. Congenital cystic adenomatoid malformation of the lung (CCAML) is a rare lesion and is characterized by a multicystic mass of pulmonary tissue with an abnormal proliferation of bronchial structures. A CCAML lesion communicates with the normal tracheal - bronchial tree and usually receives its blood supply from the pulmonary vessels (4). CCAML occurs slightly more often in males than females. These lesions are almost always unilateral (85% to 95%) but occasionally arise bilaterally (2%) (5,6).

The histopathology of CCAML has been classified into three types (3). Type I consists of single or multiple large cysts, easily visualized on ultrasound examination. Type II consists of more numerous smaller cysts, less than 1 cm in size. On ultrasound examination it appears as an echogenic mass containing small cysts. This type of CCAML is associated with a high incidence of other fetal anomalies. Type III is the least common consisting of a homogenous microcystic mass, which may appear solid on ultrasound examination. The natural history and prognosis of these lesions are extremely variable (7). The prognosis primarily depends on the size rather than the type of lesion. Large lesions have a higher incidence of mediastinal shift, polyhydramnios, pulmonary hypoplasia, vascular compromise, and hydrops, which may lead to intrauterine fetal demise or neonatal death. Hypoplasia is most commonly seen when the lesion occupies intrathoracic space. Careful ultrasound examination is important to rule out associated anomalies.

To our knowledge US has been useful for accurate predictions about fetal lung abnormalities to avoid giving birth to newborns with thorax abnormalities.

Acknowledgements

The authors thank the Department of Obstetrics and Gynecology at the Shafa Hospital, Tabriz, Iran, for helpful assistance.

REFERENCES

1. Cloutier MM, Schaeffet DA and Hight D. Congenital cystic adenomatoid malformation. *Chest* 103: 761-764, 1993.
2. Kuga T, Esato K, Kaneko J, Yamagata Y, Hoshii Y and Yamaguchi MT. Congenital cystic adenomatoid malformation with extramedullary hematopoiesis of the lung. *J Pediatr Surg* 32 (12): 1751-1753, 1997.
3. Hubbard AM and Crombleholme TM. Anomalies and malformations affecting the fetal/neonatal chest. *Semin Roentgenol* 32(2): 117-125, 1998.
4. Hubbard AM, Crombleholme TM, Coleman BG, Howell LJ, Haselgrove JC and Mahboubi S. Congenital chest lesions : Diagnosis and characterization with prenatal MR imaging. *Radiology*. 212(1): 43-48, 1999.
5. Shaaban AF, Kim HB, Milner R and Crombleholme TM. The role of ultrasonography in fetal surgery and invasive fetal procedures. *Semin Roentgenol* 34(1): 62-79, 1999.

6. Uroz Tristan J, Cabrera Roca G, Wiehoff Neumann A, Hernandez Briz MJ, Ceballos Esparragon J and Garcia Urgelles X, Bilateral and multilobar cystic adenomatoid malformation of the lung. *Eur J Pediatr Surg*. 8(6): 364-367, 1998.

7. Mac Gillivray TE, Harrison MR, Goldstein RB and Adzick NS. Disappearing fetal lung lesions. *J Pediatr Surg*. 28(10): 1321-1325, 1993.