

DEFECTIVE ANTERIOR WALL OF INGUINAL CANAL AND ITS ROLE IN THE PATHOPHYSIOLOGY OF DIRECT INGUINAL HERNIAS

S.A. Abdolvahabi

Department of Anatomy, School of Medicine, Tehran University of Medical Sciences, Tehran, Iran

Abstract- Regarding pathophysiology of direct inguinal hernias the following are pointed out:

1- Absence of contribution of fascia of transversus abdominis muscle along with fascia transversalis in making posterior wall of the inguinal canal causing defect point in Hesselbach's triangle.

2- Defects in protecting mechanisms of the inguinal canal such as: i) Shutter like effect of the arch of internal oblique and transversus abdominis muscles. ii) Sphincter like effect of fascia of oblique muscle (anterior wall of canal).

During several years of observation and practice in the field of surgical repair of hernias, a new phenomenon was observed regarding the etiology of direct hernias. Evaluation of superficial ring and Ant. Wall of inguinal canal in 25 patients showed that the Ant. Wall was not perfect and the defect was seen as a spectrum of moderate defect to complete absence of the wall. This phenomenon may be a newly observed mechanism in pathology of direct inguinal hernia that might help the operative repair. Taking this into account, i.e. repair of this defect, might help the classic herniorrhaphy techniques. *Acta Medica Iranica*: 40(2): 106-108; 2002

Key Words: Inguinal hernia, anterior wall defect, superficial ring, herniorrhaphy

INTRODUCTION

Inguinal hernias are among the most prevalent surgical diseases and comprise many surgical clinic visits.

The indirect type is much more prevalent than the direct form (3) and its pathophysiology is linked to vaginal process development. Conversely, direct inguinal hernias are much less prevalent and their etiology is linked to all factors comprising and strengthening the posterior wall of the inguinal canal. So, rational surgical treatment of hernias depends on complete knowledge of anatomy and physiology of

the region and familiarity with different surgical methods.

In this paper we report a new pathophysiologic factor in the production of direct inguinal hernias, hoping that it may contribute to emergence of new surgical operative techniques for treatment of this group of patients.

MATERIALS AND METHODS

During 1375-1380, among the patients admitted for surgical repair of inguinal hernias 150 patients were chosen to be studied.

Criteria for inclusion in the study were:

- male gender
- age 15-50 years
- negative history of previous herniorrhaphy or abdominal surgery
- negative history of severe trauma to the abdomen or inguinal area
- absence of any signs or symptoms of connective tissue, muscle or nervous system disease

The following points were looked for during the operation:

- 1- type of hernia (whether direct or indirect)
- 2- position and characteristics of anterior wall of the inguinal canal, i.e. external oblique muscle fascia, regarding the size and position of superficial ring.

RESULTS

Hernial sac: in 30 cases the hernial sac was a direct one. In two cases there was a combination of two types and in the rest the hernia was indirect.

Superficial ring: the superficial ring was triangular in all cases, the base of which was lying over pubic crest, but there was a surprising difference in the distance of top to base of the triangle between the two types of hernia. So that in all indirect cases the triangle and its dimensions were nearly similar and normal. On the other hand in the cases with direct hernias the measurements from top to bottom of the triangles were interestingly far more longer than the indirect ones, in a way that in 25 patients

Correspondence:

S.A. Abdolvahabi
Department of Anatomy, Tehran University of Medical Sciences, Tehran, Iran
Tel: +98212587569

because of elongation of triangular ring, the anterior wall of the canal was devoid of full coverage, i.e. the covering fascia was incomplete at various proportions and in some cases in which the tip of the triangular superficial ring was superimposed over the deep ring, the canal was practically devoid of any coverage (Fig. 1).

DISCUSSION

Normally the shutter mechanisms of the anterolateral abdominal muscles, i.e. internal oblique and transversus abdominis and also the sphincter like effect of the fascia of external oblique muscle (anterior wall of the canal) work together to maintain the integrity and resistance of inguinal canal against

elevated intra abdominal pressure. Supposedly, any abnormality or inappropriateness in the function of these elements can facilitate the production of hernias.

Most investigators have recognized posterior wall (Hesselbach's triangle) weakness as the main cause of direct hernias which is the result of non-sharing of transversus abdominis muscle fascia with fascia transversalis in making the posterior wall. Defects in or absence of anterior wall of the inguinal canal should be considered as possible etiologic factors in the pathogenesis of direct inguinal hernias.

Regarding the above, we propose that during operative surgery of inguinal hernias, besides repairing the posterior wall (classic herniography), the anterior wall defects be taken into account and using various techniques to repair this defect be considered as well.

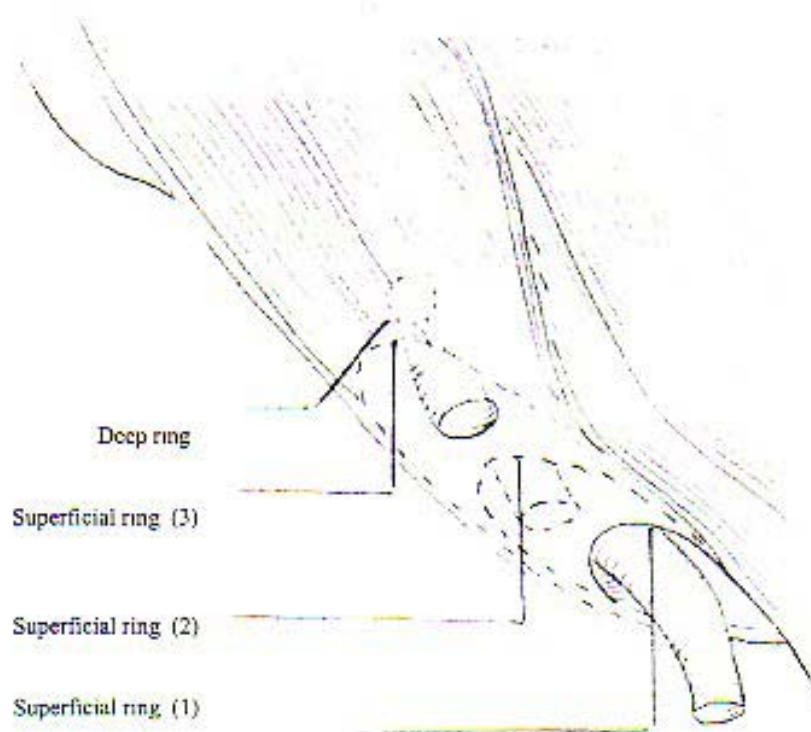


Fig. 1. Anatomical positions (1,2,3) of superfiscial ring

REFERENCES

1. Shwartz, principles of surgery, seventh edition, Churchill livingstone 1999; 1590-6.
2. Philip Thorek, Anatomy in surgery, third edition, New York springer-verlag 1985; 380-97.
3. Lloyd M, Onyhus Robert E, Condon, third edition, J. B. Lippincott company 1987; 65-6, 39-40, 60-63.

Archive of SID