

# CHANGES IN CARTILAGE OF RATS AFTER TREATMENT WITH QUINOLONE AND IN MAGNESIUM-DEFICIENT DIET

M. Shakibaei<sup>1</sup> and R. Stahlmann<sup>2</sup>

1) Institute of Anatomy, Freie Universität Berlin, Berlin, Germany

2) Institute of Clinical Pharmacology and Toxicology, Benjamin Franklin Medical Center, Freie Universität Berlin, Berlin, Germany

**Abstract-** Ultrastructural changes in immature articular cartilage were studied after treatment of 5-weeks-old rats with ofloxacin, a fluoroquinolone, and in magnesium deficiency.

We concluded that quinolone-induced arthropathy is probably due to chelation of functionally available magnesium in joint cartilage as magnesium deficiency in joint cartilage could impair chondrocyte-matrix-interaction which is mediated by cation-dependent integrin-receptors of the  $\beta_1$ -subfamily. With immunohistochemical methods using monoclonal and polyclonal antibodies we showed that  $B_1$  integrins were expressed in rat joint cartilage. Joint cartilage lesions were detected in ofloxacin-treated and magnesium-deficient rats. Lesions were more pronounced in the quinolone-treated group. Expression of several integrins was reduced in the vicinity of lesions after oral treatment with 2×600 mg ofloxacin/kg body wt for one day. Gross-structural lesions (e.g. cleft formation, unmasked collagen fibres) in magnesium deficient rats were very similar but changes in integrin expression were less pronounced. Alterations observed on the ultrastructural level showed striking similarities in magnesium-deficient rats and in rats treated with single doses of 600 mg ofloxacin per kg body wt. Typical observations were: bundle shaped, electron-dense aggregates on the surface and in the cytoplasm of chondrocytes, detachment of the cell membrane from the matrix and necrotic chondrocytes, reduced synthesis and/or reduced of extracellular matrix and swelling of cell organelles such as mitochondria.

The results of this study confirm our previously reported finding that quinolone-induced arthropathy probably is caused by a reduction of functionally available magnesium (ionized  $Mg^{2+}$ ) in cartilage. Furthermore, they provide a basis for aimed studies with human cartilage samples from quinolone-treated patients which might be available postmortal or after hip replacement surgery.

*Acta Medica Iranica*, 40(3);171-176 : 2002

**Key Words:** Cartilage, quinolone, magnesium-deficient, diet, rats

## Correspondence:

M. Shakibaei, Institute of Anatomy, Freie Universität Berlin, Berlin, Germany  
Tel: ++4930 84451916  
Fax: ++4930 84451931  
E-mail: mehshaki@zedat.fu-berlin.de

## INTRODUCTION

Quinolone-induced cartilage degeneration is an important toxic effect in juvenile animals which has led to restrictions on the therapeutic use of these antimicrobial agents (Kato and Onodera, 1988 a-b, Stahlmann et al., 1990, 1993; Burkhardt et al., 1993). Fluoroquinolones are widely used antimicrobial agents for treatment of bacterial infections such as urinary tract, respiratory tract and others (Neu, 1992). Since quinolones are known to form stable chelate complexes with dior trivalent cations and to accumulate in cartilage, we investigated the effect of ofloxacin on cation-dependent cell-surface receptors (integrins) on mouse epiphyseal chondrocytes. Integrins are heterodimeric adhesion molecules and they mediate cell-cell as well as cell-matrix interaction and thus mediate an interaction between the cytoskeleton and extracellular matrix (Hynes, 1992). Immuno-morphological investigations of chondrocytes have shown the presence of  $\beta_1$  - integrins in vivo and in vitro (Enomoto et al., 1993; Mirr et al., 1993; Shakibaei et al., 1993, 1995 a-b).

In this paper we report ultrastructural changes in articular cartilage from three groups of rats which were (a) treated with ofloxacin, (b) received a magnesium deficient diet. The results of our experimental work might also have important implications for the aimed examination of human cartilage samples which would help to clarify the question of a possible human risk for the quinolone-induced arthropathy.

## MATERIALS AND METHODS

### Treatment of rats

Five groups of 35-day-old male and female Wistar rats (each group: n= 6 to 7) were treated with a single dose of ofloxacin (100, 300, 600 or 1200 mg/kg body wt) by gastric intubation. The dosing solution was prepared by suspending commercially available tablets (Tarivid<sup>®</sup>) in a 2% starch solution. Control animals received the vehicle. Rats were kept in Macrolon<sup>®</sup> cages at a room temperature of 23± 1°C and 50± 5% relative humidity, constant light/dark schedule (light: from 7a.m. to 7 p.m.); they

received Altromin® 1324 pellet feed ( $Mg^{2+}$  content: >1000 mg/kg) and tap water ad libitum.

### Magnesium deficiency

Five additional groups were fed a magnesium deficient diet (Altromin® C1035) for 9 days starting on day 28 postnatally. Experimental conditions were otherwise identical for these rats.

### Light microscopy

All rats were sacrificed 72 hours after treatment with the quinolone, the knee joints were prepared, fixed in formaline, decalcified in 10% EDTA solution (pH= 7.4) and after toluidine staining examined by light microscopy.

### Transmission electron microscopy (TEM)

Tissue samples were fixed in 1% glutaraldehyde plus 1% tannic acid in 0.1 M phosphate buffer, pH 7.4, post-fixed in 2%  $OsO_4$  in the same buffer. After rinsing and dehydration in ethanol, the samples were embedded in Epon (Plano, Marburg, FRG), cut with an Ultracut E (Reichert) and the sections contrasted with 2% uranyl acetate and lead citrate and investigated under a transmission electron microscope (Zeiss EM 10).

## RESULTS

### Light microscopy

The results of representative examples of light microscopic evaluation show the lesions. The lesions induced by magnesium deficiency could not be distinguished microscopically from ofloxacin-induced alterations and were found in all animals of this group. Interestingly, the predilection sites were different in both groups: after one-day treatment with 2×600 mg ofloxacin/kg body weight lesions were found in the femoral and tibial condyles whereas the typical location in the magnesium deficient group was the ventral part of the femoral condyles. Treatment of magnesium-deficient rats with low doses of ofloxacin (which are not arthropathogenic in rats with a normal  $Mg^{+2}$ -status) induced more severe lesions which typically were found not only in one part of the joint, but often affected femoral and tibial cartilage.

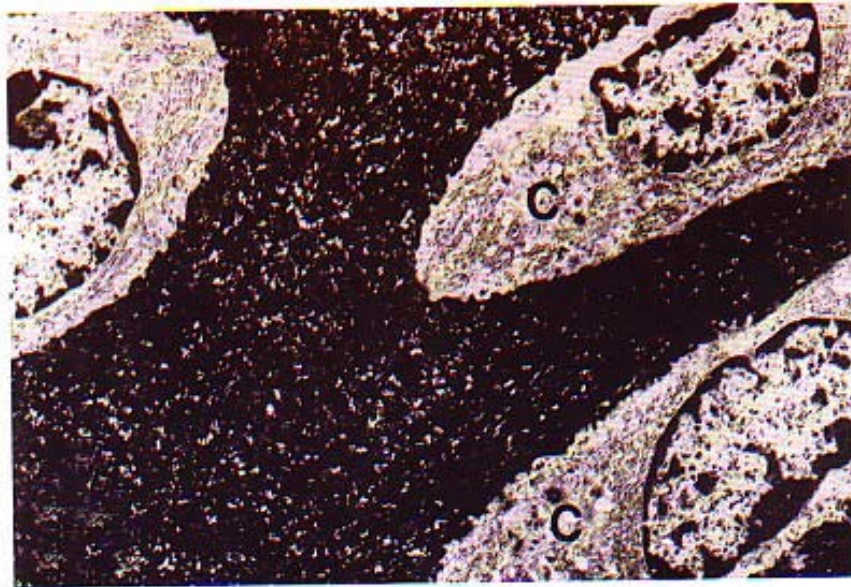### Electron microscopy

The ultrastructural features of joint cartilage (femoral head) from control juvenile rats showed typical chondrocytes embedded in the cartilage matrix. The chondrocytes were oval and had intact organelles and showed numerous thin cell processes. Cartilage matrix was well developed consisting of thin irregularly running fibrils attached to the chondrocyte membrane. After tannic acid fixation,

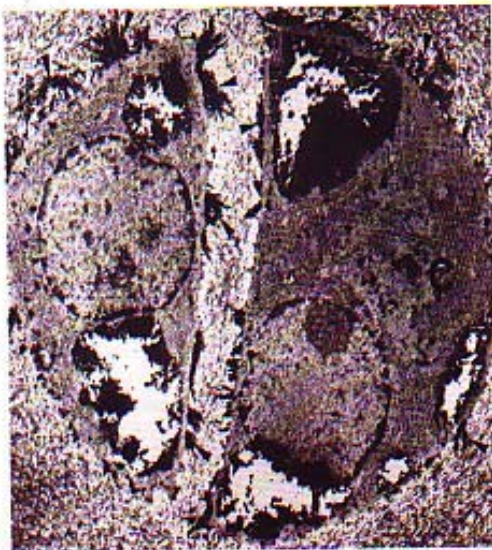they came into contact with the surface coat of the cell membrane (Fig. 1a). Cartilage of ofloxacin rats (with a normal- $Mg^{+2}$ -status) showed cells which seemed to be intact or necrotic (Fig. 1b) with large electron-dense aggregates on and in the cells. The cell membrane got detached from the matrix and a space developed between cell membrane and matrix. The chondrocytes changed their phenotype, swelling of cell organelles (mitochondria, rough endoplasmic reticulum). An extensive breakdown of cartilage matrix was observed. Cartilage of magnesium-deficient rats showed similar morphological changes on chondrocytes and in cartilage matrix (Fig. 1c). Treatment of magnesium-deficient rats with low doses of ofloxacin showed similar ultrastructural changes on chondrocytes and breakdown of cartilage matrix. Initially the pericellular matrix was degraded and the entire matrix was affected (not shown). We found areas in middle zone, where the number of chondrocytes showing the above-mentioned changes was increased and necrotic cells with completely degraded matrix could be observed.

## DISCUSSION

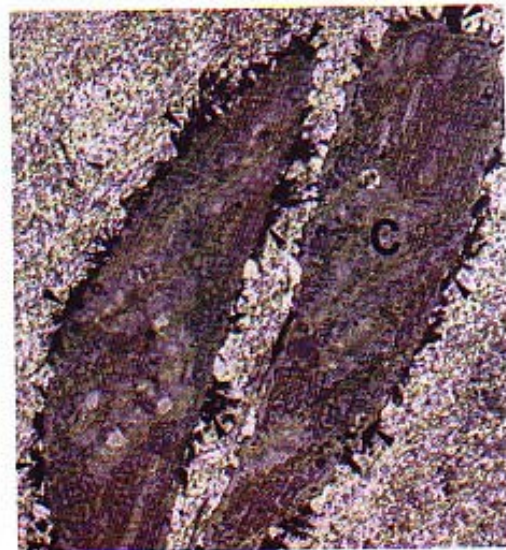
The results in this paper underline the hypothesis that most probably quinolone-induced arthropathy is caused by interference of the drugs with extracellular magnesium in joint cartilage since a dietary induced magnesium deficiency caused cartilage lesions which were identical to quinolone-induced lesions also on an ultrastructural level. The organ specificity of the effect can be explained by the fact that quinolones accumulate in cartilage (e. g. Okazaki et al., 1984) and that ion disturbances are not as readily balanced in the poorly nutrient-supplied joint cartilage as in other tissues. The ofloxacin doses used in this study are high in comparison to therapeutically applied doses. However, we could show before that with gastric intubation of 600 mg ofloxacin/kg body wt-representing approximately a 100 fold human dose plasma concentrations in immature rats were only approximately 10 fold higher than concentrations measured in man (Stahlmann et al., 1990). This relationship between dose and kinetics has to be taken into account if toxicological and therapeutic data are compared. Quinolone-induced arthropathy can be induced in immature animals of multiple species such as dogs (Burkhardt et al., 1992; Burkhardt et al., 1993), rats (Kato and Onodera, 1988a), non-human primates (Stahlmann et al., 1990) and others. Since fluoroquinolones possess the unique combination of a high antimicrobial activity against gram-negative pathogens-including *Pseudomonas aeruginosa*- plus good bioavailability after oral administration (Neu, 1992) more and more pediatricians have demanded a limited use of these drugs also in pediatrics (Adam, 1989; Schaad, 1992 a-b).



1a



1b



1c

**Fig. 1.** Electron microscopy of knee joints from immature rats

a: Control. Electron micrograph of chondrocytes in articular cartilage of the femur. Chondrocytes show normal morphology, have intact organelles, the cell membrane has extensive contact with pericellular matrix. Matrix is very thick. X 4.000.

b: Ofloxacin-treated. Ultrathin section through articular cartilage of the femur. Electron-dense material (arrowheads) are on and in the cell, showing intense loosening and reduction of the matrix with matrix-free pericellular areas of chondroblasts (C). These changes occurred on chondrocytes which appeared to be intact and on necrotic. X 4.000.

c: Cartilage of magnesium-deficient rats shows similar changes as to ofloxacin-treated rats (b). X 4.000.

Certainly, the chondrotoxic potential of quinolones under therapeutic conditions is low and the vast majority of juvenile patients have shown no clinical signs of arthropathy after treatment with a quinolone. However, it remains unclear if minor lesions might also occur in humans after therapeutic doses. Arthropathy has been reported in a considerable number of case reports of juveniles and even adult patients (Chevalier et al., 1992; Samuelson et al., 1993; for review see: Stahlmann et al., 1993). The possible risk for humans is still a matter of controversy as the causal relationship in these cases remains obscure. Light microscopic investigation of joint cartilage from ofloxacin-treated juvenile rats revealed lesions that were very similar to joint damage induced by magnesium deficiency alone. Electron microscopic investigation of cartilage samples from both ofloxacin-treated and from magnesium deficient rats showed 3 characteristic ultrastructural changes: (1) electron dense aggregates on the surface of chondrocytes and in the cells, (2) the chondrocytes detached from the pericellular matrix and their changed phenotype, swelling of cell organelles (3) extensive breakdown of the cartilage matrix and necrotic cells. The occurrence of a pericellular halo around the chondrocytes indicates damage of cell-matrix binding. Recently, several authors have shown that integrin receptors of the  $\beta_1$ -subfamily play an important role to mediate cell-matrix interaction in different cartilage, in vivo and in vitro (Salter et al., 1992; Diirr et al., 1993; Enomoto, 1993; Shakibaei, 1993, 1995 a-b, Fbrster, 1995). This observed finding might represent an initial step in chondrocyte damage and is accompanied by formation of electron dense bundle-like aggregates on the cell surface and cartilage matrix breakdown, giving rise to the following considerations: I: Damage of interaction between cells and matrix and detachment of the cells might be from the chondroblasts themselves. Magnesium-deficiency and ofloxacin might cause a high  $Ca^{2+}$ -concentration in the cells. These stimulate release of lysosomal enzyme and hence enable them to breakdown the pericellular matrix. II: It is well known, IL-1 (interleukin-1) and TNF- $\alpha$  (tumor necrosis factor alpha) plasma levels in magnesium-deficient rats are higher than plasma levels in rats with regular magnesium concentration (Weglicki et al., 1993; Giinther et al., 1995). TNF- $\alpha$  is known to be an inducer of IL-1 (Nawroth, 1986) and these cytokines are known for inhibit proteoglycan synthesis and breakdown of cartilaginous matrix by chondrocytes (Pettipher et al., 1986; Dingle et al., 1987; Mohammed-Ali, 1985). Several authors pointed to synergistic effects between IL-1 and TNF- $\alpha$  (Henderson and Pettipher, 1989; Saklatvala, 1986). III: The cells produced atypically aggregates of molecules which as electron dense aggregates were observed. These aggregates might indicate early

pathological changes and reflect proteoglycans synthesis. Additionally proteoglycan synthesis may decrease, as observed by reduced uptake of  $^{35}S$  in chondrocytes and matrix from ofloxacin-treated rats (Kato und Onodera, 1988b; Kato et al., 1995) or by decreased matrix staining with toluidine blue (e.g. Burkhardt et al., 1990; Stahlmann et al., 1995) is known to be a characteristic finding after quinolone treatment. These aggregates caused additional detachment with extracellular matrix. The breakdown of the matrix and disappearance of cell-matrix interaction caused the cell degeneration and necrosis. The extracellular matrix in cartilage plays an essential role in the behaviour, differentiation and proliferation of chondrocytes (Kosher et al., 1973; Kosher and Church, 1975; Hewitt et al., 1982; Sommarin et al., 1989; Ramachandrala et al., 1992). Since pericellular matrix components are linked with cell via surface receptors, integrins (Dtirr et al. 1993; Enomoto et al., 1993; Shakibaei et al., 1993, 1995 a-b; Fbrster et al., 1995) disappearance of these receptors results in a disarrangement of cell-matrix interaction. This leads to an enhanced effect of degrading effect of magnesium deficient with/without ofloxacin in the pericellular area and additionally causes the occurrence of morphological changes of the cell. Further studies are necessary to define these events in quinolone-induced arthropathy.

### Acknowledgements

This work was supported by grants from the Deutsche Forschungsgemeinschaft. Mrs. Barbara Steyn's help with the manuscript, Mrs. Ingrid Wolffs expert photographic work and Helga SWrje and Mrs. Angelika Steuer's expert technical assistance are gratefully acknowledged.

### REFERENCES

1. Adam D. Use of quinolones in pediatric patients. *Rev Infect Dis* 1989; 11(Suppl 5): 1113-1116.
2. Burkhardt JE, Hill MA, Carlton WW, Kesterson JW. Histologic and histochemical changes in articular cartilage of immature beagle dogs dosed with difloxacin, a fluoroquinolone. *Vet Pathol* 1990; 27: 162-170
3. Burkhardt JE, Hill MA, Carlton WW. Morphologic and biochemical changes in articular cartilages of immature Beagle dogs dosed with difloxacin. *Toxicologic Pathol* 1992 a; 20: 246-252.
4. Burkhardt JE, Hill MA, Lamar CH, Smith GN, Carlton WW. Effects of difloxacin on the metabolism of glycosaminoglycans and collagen in organ cultures of articular cartilage. *Fundamental and Applied Toxicology* 1993; 20: 257-263.

5. Chevalier X, Albengres E, Voisin M-C, Tillement J-P, Larget-Piet B. A case of destructive polyarthropathy in a 17-year-old youth following pefloxacin treatment. *Drug Safety* 1992; 7: 310-314.
6. Dingle JT, Page TPD, King B, Bard DR. In vivo studies of articular tissue damage mediated by catabolin/interleukin 1. *Ann Rheum Dis* 1987; 46: 527-533.
7. Dtirr J, Goodman S, Potocnik A, von der Mark H, Vonder Mark K (1993). Localization of  $\beta_1$ -integrins in human cartilage and their role in chondrocyte adhesion to collagen and fibronectin *Exp Cell Res* 207: 235-244.
8. Enomoto M, Leboy PS, Menko AS, Boettiger D.  $\beta_1$ -Integrins mediate chondrocyte interaction with type I collagen, type II collagen, and fibronectin. *Exp Cell Res* 1993; 205:276-285.
9. Fbrster C, Kociok K, Shakibaei M, Merker HJ, Vormann J, Giinther T, Stahlmann R. Integrins on joint cartilage chondrocytes and alterations by ofloxacin or magnesium deficiency in immature rates. *Arch Toxicol* 1996; 70: 261-270.
10. Gough AW, Kasali OB, Sigler RE, Baragi V. Quinolone arthropathy-acute toxicity to immature cartilage. *Toxicol Pathol* 1992; 20: 436-450.
11. Giinther T, Shtimann K, Vormann J. Tumor necrosis factor- $\alpha$ , Prostanoids and immunoglobulins in magnesium deficiency. *J Magnes Bull* 1995; 17: 109-114.
12. Henderson B, Pettipher ER. Arthritogenic actions of recombinent ILA and tumor necrosis factor in the rabbit: evidence for synergistic interactions between cytokines in vivo. *Clin Exp Immunol* 1989; 75: 306-310.
13. Hewitt AT, Varner HH, Silver MH, Dessau W, Wilkes CM, Martin GR. The isolation and partial characterization of chondronectin, an attachment factor for chondrocytes. *J Cell Biol* 1982; 257: 2330-2334.
14. Hynes RO. Integrins: Versatility, modulation, and signaling in cell adhesion. *Cell* 1992; 69:11-25.
15. Kato M, Onodera T. Morphological investigation of cavity formation in articular cartilage induced by ofloxacin in rats. *Fund Appl Toxicol* 1988 a; 11: 110-119.
16. Kato M, Onodera T. Effect of ofloxacin on the uptake of [3H] thymidine by articular cartilage cells in the rat. *Toxicology Letters* 1988 b; 44: 131-42.
17. Kato M, Takada S, Ogawara S, Takayama S. Effect of levofloxacin on glycosaminoglycan and DNA synthesis of cultured rabbit chondrocytes at concentrations inducing cartilage lesions in vivo. *Antimicrobial Agents and Chemotherapy* 1995; 39: 1979-1983.
18. Koshier RA, Lash JW, Minor RR. Environmental enhancement of in vitro chondrogenesis. IV. Stimulation of somite chondrogenesis by exogenous chondromucoprotein. *Developmental Biology* 1973; 3 5: 210-220.
19. Koshier RA, Church RL. Stimulation of in vitro somite chondrogenesis by procollagen and collagen. *Nature* 1975; 258: 327-330.
20. Mohamed-Ali H. Influence of interleukin-1 $\beta$ , tumor necrosis factor alpha and prostaglandin E2 on chondrogenesis and cartilage matrix breakdown in vitro. *Rheumatol Int* 1995; 14: 191-199.
21. Nawroth PP, Bank L, Handley D, Cassimeris J, Chess L, Stern D. Tumor necrosis factor/cachectin interacts with endothelial cell receptors to induce release of interleukin 1. *J Exp Med* 1986; 163: 1363-1375.
22. Neu HC. Quinolone antimicrobial agents, *Annual Reviews in Medicine* 1992; 43: 465-486.
23. Okazaki O, Kurata T, Hashimoto K, Sudo K, Tsumura M, Tachizawa H. Metabolic disposition of DL-8280. The second report: Absorption, distribution and excretion of 14C-DL-8280 in various animal species. *Chemotherapy* 1984; 32 (Suppl 1), 1185-1202.
24. Pettipher ER, Higgs GA, Henderson B. Interleukin 1 induces leukocyte infiltration and cartilage proteoglycan degradation in the synovial joint. *Proc Natl Acad Sci USA* 1986; 83: 8749-8753.
25. Ramachandrule A, Tiku K, Tiku ML. Tripeptide RGD-dependent adhesion of articular chondrocytes to synovial fibroblasts. *J Cell Biol* 1992; 101: 859-871.
26. Saklatvala J. Tumor necrosis factor  $\alpha$  stimulates resorption and inhibits synthesis of proteoglycan in cartilage. *Nature* 1986; 322: 547-549.
27. Salter DM, Hughes DE, Simpson R, Gardner DL. Integrin expression by human articular chondrocytes. *Brit J Rheumat* 1992; 31: 231-234.



## Chondrotoxicity of quinolone

28. Samuelson WM, Pleasants RA, Whitaker MS. Arthropathy secondary to ciprofloxacin in an adult cystic fibrosis patient. *Ann Pharmacotherapy* 1993; 27: 302-303.
29. Schaad UB, Wedgwood J. Lack of quinolone-induced arthropathy in children. *J Antimicrobial Chemotherapy* 1992 a; 30: 414-416.
30. Schaad UB. Role of the new quinolones in pediatric practice. *Pediatric Infectious Disease J* 1992 b; 11: 1043-1046.
31. Shakibaei M, Abou-Rebyeh H, Merker H-J. Integrins in ageing cartilage tissue in vitro. *Histol Histochem* 1993; 8: 715-723.
32. Shakibaei M, Forster C, Merker H-J, Stahlmann R. Effects of ofloxacin on integrin expression on epiphyseal mouse chondrocytes in vitro. *Toxic in vitro* 1995 a; 9: 107-116.
33. Shakibaei M, Zimmen-nann B, Merker H-J. Changes in integrin expression during chondrogenesis in vitro (An immunomorphological study). *J Histochem Cytochem* 1995 b; 43: 1061-1069.
34. Sommarin Y, Larsson T, Heinegard D. Chondrocyte-matrix interactions: attachment to proteins isolated from cartilage. *Exp Cell Res* 1989; 184: 181-192.
35. Stahlmann R, Merker H-J, Hinz N, Chahoud-I, Webb J, Heger W, Neubert D. Ofloxacin in juvenile non-human primates and rats. Arthropathia and drug plasma concentrations. *Arch of Toxicology* 1990; 64: 193-204.
36. Stahlmann R. Safety profile of the quinolones. *J of Antimicrobial Chemotherapy* 1990; 26 (Suppl D): 31-44.
37. Stahlmann R, Forster C, Van Sickle D. Quinolones in children: are concerns over arthropathy justified? *Drug Safety* 1993; 9: 3 97-403.
38. Stahlmann R, Forster C, Shakibaei M, Vormann J, Gunther T, Merker H-J. Magnesium deficiency induces joint cartilage lesions in juvenile rats which are identical with quinolone-induced arthropathy. *Antimicrobial Agents and Chemotherapy* 1995; 39: 2013-2018.
39. Weglicki W13, Stafford RE, Dickens BF, Mak IT, Cassidy MM, Phillips TM (1993). Inhibition of tumor necrosis factor-alpha by thalidomide in magnesium deficiency. *Molecular and Cellular Biochemistry* 1993; 129: 195-200.