

EFFECTIVENESS OF ABDOMINAL WALL ELEVATOR IN REDUCING INTRA-ABDOMINAL PRESSURE AND CO₂ VOLUME DURING LAPAROSCOPIC CHOLECYSTECTOMY

A. Yaghoobi Notash*, Sh. Bahrpeyma and M. H. Modaghegh

Department of Surgery, Sina Hospital, School of Medicine, Tehran University of Medical Sciences, Tehran, Iran

Abstract- Since CO₂ pneumoperitoneum is the dominant method of laparoscopic exposure due to facility and good view, its physiologic effects are most relevant to the surgeons. CO₂ pneumoperitoneum may affect hemodynamics by increased intra-abdominal pressure (IAP) and the physiologic effects of absorbed CO₂. The adverse effects of both mechanisms relate directly to the duration of the pneumoperitoneum and the elevation of IAP. Gasless laparoscopy involves obtaining exposure for laparoscopy by placing an internal retracting device through a small incision and lifting the anterior abdominal wall. We designed and made a mechanical wall elevator and used it in 24 patients, compared with a control group (52 cases) using a conventional laparoscopic cholecystectomy. A prospective trial was undertaken in Sina Hospital, Tehran University of Medical Sciences from 1998 to 2000. The patients were assigned randomly to two groups. There was a significant decrease in IAP and CO₂ consumption in the group using mechanical wall elevator as compared to conventional laparoscopic cholecystectomy, (mean IAP of 3.5 mmHg compared to 11.4 mmHg in the control group, mean CO₂ volume 17 liters compared to 73 liters in the control group). We recommend this semi-gasless method in laparoscopy due to safety in performance and significant reduction in IAP through the surgery. This method provides a satisfactory view and easy performance without any increase in time or complications. The hospital stay and costs did not increase.

Acta Medica Iranica, 42(2): 131-135; 2004

Key words: Laparoscopic cholecystectomy, abdominal wall, pneumoperitoneum, intra-abdominal pressure

INTRODUCTION

Since CO₂ pneumoperitoneum is the dominant method of laparoscopic exposure due to the facility and good view, its physiologic effects are more relevant to the surgeons. CO₂ pneumoperitoneum may affect hemodynamics by increasing intra-abdominal pressure (IAP) and the physiologic effects of absorbed CO₂. Adverse effects of CO₂ pneumoperitoneum range in severity, by way of

multiple mechanisms. Some of these adverse effects may be physiologic responses and some of them are unusual or complications (1).

The adverse effects of both primary mechanisms relate directly to the duration of the pneumoperitoneum and elevation of intra-abdominal pressure during the operation. Adequate pneumoperitoneum is usually achieved at a pressure of 10 to 15 mmHg.

This level of intra-abdominal pressure seldom causes complications. Gasless laparoscopy involves obtaining exposure for laparoscopy by placing an internal retracting device through a small incision and lifting the anterior abdominal wall (2-4). This trial introduced a semi-gasless technique with significant

Received: 24 Apr. 2002, Revised: 8 Sep. 2002, Accepted: 25 Jun. 2003

*** Corresponding Author:**

A. Yaghoobi Notash, Department of Surgery, School of Medicine, Tehran University of Medical Sciences, Tehran, Iran
Tel: +98 21 6701041-9, Fax: +98 21 6716545
E-mail: Ayaqhoobi@sina.tums.ac.ir

reduction of intra-abdominal pressure and CO₂ volume to eliminate the complications of pneumoperitoneum, with no increase in duration of procedure.

MATERIALS AND METHODS

We designed and made a mechanical abdominal wall elevator including: Base, Arm, Holder and Needle (Fig. 1). In order to elevate the intra-abdominal pressure to 12-14 mmHg, we first insufflated the abdomen with 1.5 to 2.5 liters of CO₂ depending on the size of the abdominal cavity. After inserting trocars at routine sites and performing laparoscopy, the needle was inserted through a 3 mm incision at a point between mid-clavicular and anterior axillary ports and fixed to the holder. The holder was then fixed to the arm that had been screwed to the base (Fig. 2). CO₂ flow was stopped, and the procedure continued. Intra-abdominal pressures and CO₂ volumes were recorded throughout the procedure. This study was a descriptive, consecutive and prospective trial that was carried out from 1998 to the end of 2000, in Sina Hospital of Tehran University of Medical Sciences. The patients were randomly assigned to two groups:

the study group (24 cases) in whom the elevator was used, and the control group (52 cases) with no use of the abdominal wall elevator. The intra-abdominal pressure (IAP), CO₂ volume, and duration of surgery were recorded. The criteria for laparoscopic cholecystectomy were gallstones without any common bile duct (CBD) obstruction or liver damage, with normal liver function tests. The sonographic criteria consisted of gallstones with normal or thickened gallbladder wall, normal diameters of CBD and intra- or extra-hepatic ducts, and a normal sonographic pattern of the liver and pancreas.

RESULTS

There was a significant decrease in intra-abdominal pressure and CO₂ consumption. The average intra-abdominal pressure in study group was 3.547 mmHg compared with 11.459 mmHg in control group (Fig. 3). The average CO₂ volume in study group was 17.22 liters compared with 73.22 liters in control group (Fig. 4). Finally there was no significant difference in operation time, with an average of 58 minutes in study group and 61 minutes in control group (Table 1).

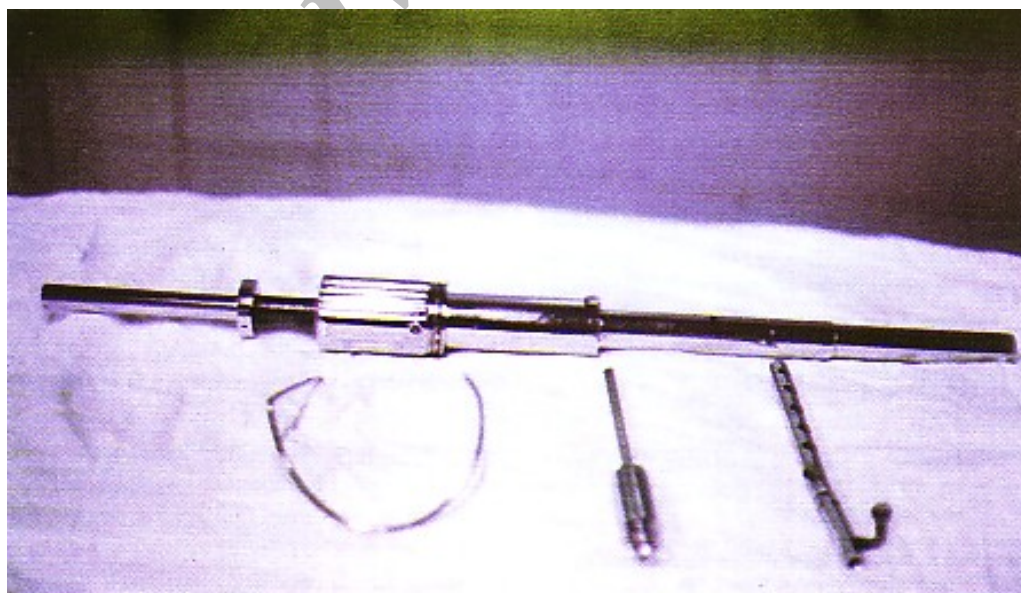


Fig. 1. Abdominal wall elevator

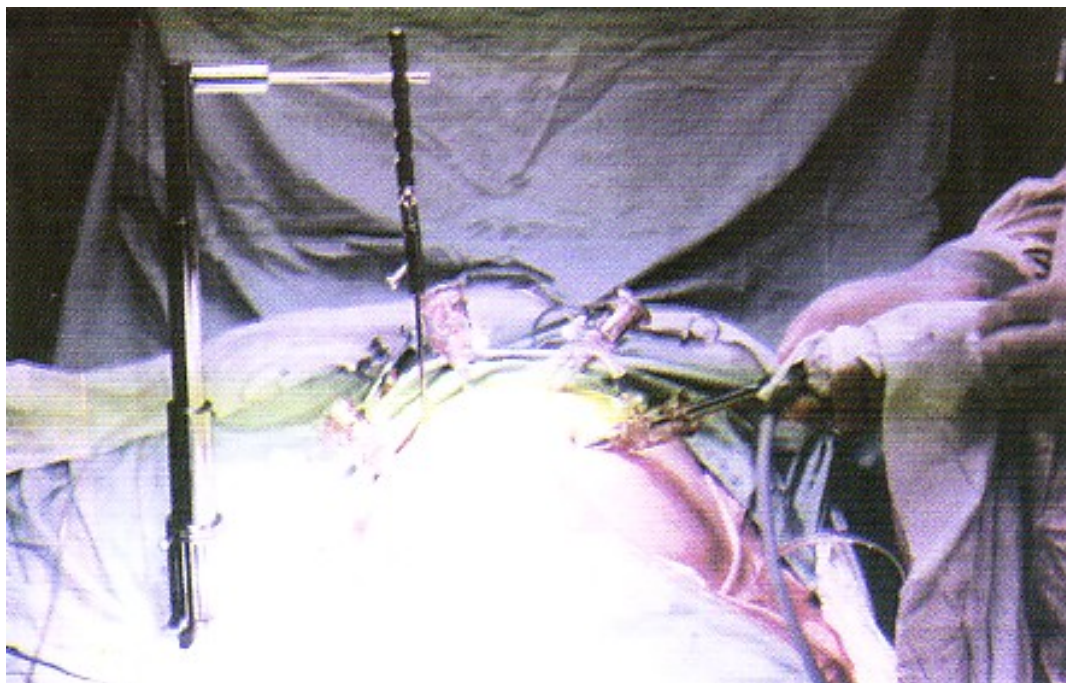


Fig. 2. Abdominal wall elevator

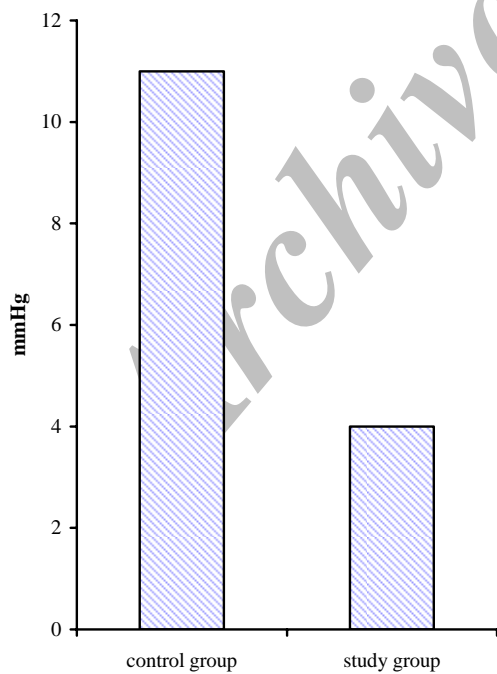


Fig. 3. Comparison of mean IAP between control and study groups (mmHg)

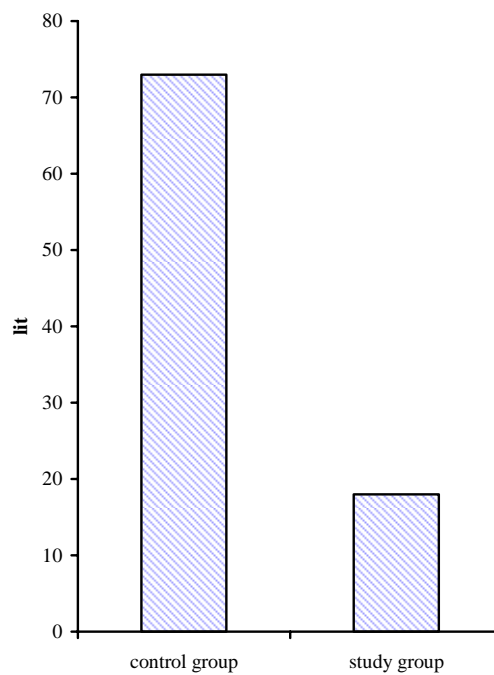


Fig. 4. Comparison of average CO₂ volume (lit) between

control and study groups.

Table 1. Results of study

Criteria	Max		Min		Mean		SD		NO	
	SG	CG	SG	CG	SG	CG	SG	CG	SG	CG
IAP (mmHg)	11	15	1	10	3.547	11.459	1.45	1.28	24	52
CO ₂ (liter)	66	200	4.1	14	17.22	73.22	17.6	55	24	52
Time (minute)	150	180	30	35	58	61	0.25	0.27	24	52

SG= Study group, CG= Control group

DISCUSSION

Pneumoperitoneum is not an entirely safe modality based on the experience of surgeons (5-7). The risks of pneumoperitoneum may be divided into several types including: a) during the operation b) during the maintenance and c) at the termination (1,6,8). The most important complications and risks that take place during the maintenance of pneumoperitoneum are due to elevation of intra-abdominal pressure and physiologic effects of absorbed CO₂. CO₂ pneumoperitoneum with increased IAP impairs splanchnic circulation by compressing vessels. Cardiovascular complications related to pneumoperitoneum including gas embolism, decrease in cardiac output, dysrhythmia, hypotension or hypertension. are well-defined (6,7,9). In addition to the intra-operative compression of intra-abdominal organs by CO₂ pneumoperitoneum, the slow release of stored CO₂ postoperatively is a possible explanation for the long-lasting effect of impairment in pH. With the retractor method, pH value does not decrease perioperatively. Thus the risk of splanchnic ischemia is minimal with gasless method. Also, the pulmonary and hemodynamic changes and the effect of CO₂ pneumoperitoneum on renal and abdominal visceral blood flow and other rare complications have been discussed (6,7,9). Gasless laparoscopy for decreasing or elimination of the above complications has been described (2,3,10), but the complications observed with gasless laparoscopy such as intestinal hooking, abdominal wall pain and necrosis, wound complications and impaired view and exposure must parallel those seen in standard laparoscopy. Johnson *et al.* used a butterfly-shaped abdominal wall elevator in laparoscopy for tubal ligation. They did not recommend their method due to limitation of view.

On the other hand the Japanese researchers (11,12) recommend the use of an abdominal wall elevator. They have not found any differences between conventional and gasless laparoscopic cholecystectomy (10,13-18). Koivusalo *et al.* found that mean arterial pressure was higher in conventional group throughout the operation. Urine output was significantly higher with retractor group (9). In order to have a good view and exposure and reducing the other complications, we describe semi-gasless technique and recommend this method due to safety in performance and significant reduction in intra-abdominal pressure and CO₂ consumption through the surgery. In conclusion, gasless laparoscopic surgery is recommended due to reduction in pulmonary and cardiovascular effects associated with conventional methods. There are several types of abdominal wall elevators used in laparoscopic surgery with different success rates. We recommend this semi-gasless method in laparoscopy due to safety in performance and significant reduction in IAP throughout surgery. It provides a good view and easy performance without any increase in time or complications. The hospital stay and costs did not increase.

REFERENCES

1. Koivusalo AM, Kellokumpu I, Ristkari S, Lindgren L. Splanchnic and renal deterioration during and after laparoscopic cholecystectomy: A comparison of the carbon dioxide pneumoperitoneum and the abdominal wall lift method. *Anesthesia Analgesia* 1997; 85(4): 886-891.
2. Hashimoto D, Nayeem SA, Kajwara S, Hashimoto. Laparoscopic cholecystectomy. An approach without pneumoperitoneum. *Surgical Endoscopy* 1993-7: 54-56.
3. Banting S, Shimi S, Vandurvelpeng, Guschieri A.

- Abdominal wall Lift. Low-pressure pneumoperitoneum, laparoscopic surgery. *Surg Endosc* 1993; 7: 57-59.
4. Sequier JC, Barbier F, Hibbert F, Sinda P, Julienne P, Morre PH, Montariol TH. Limitation of capnography during anaesthesia for laparoscopic surgery with intraperitoneal CO₂. *Brit J of Surg* 1992; 79 (suppl.): 69.
 5. Carry PY, Gallet D, Francois Y, Perdrin JP, Sayag A, et al. Respiratory mechanics during laparoscopic cholecystectomy: The effects of abdominal wall lift. *Anesthesia Analgesia* 1998; 87(6): 1393-1397.
 6. Koivasalo AM, Kellokumpu I, Sheinin M, Tikkanen I, et al. A comparison of gasless mechanical and conventional carbon dioxide pneumoperitoneum methods for laparoscopic cholecystectomy. *Anesthesia Analgesia* 1998; 6(1): 153-158.
 7. Koivusalo AM, Kellokumpu I, Scheinin M, Tikkanen I, Halmel, et al. Randomized comparison of the neuroendocrine response to laparoscopic cholecystectomy using either conventional or abdominal wall lift technique. *Br J Surg* 1996; 83(11): 1532-1536.
 8. Stewart, B. Corbet, y. Abdominal wall lift in laparoscopic colorectal surgery. *Disease of the colon and rectum* 1999; 42(4) A22.
 9. Rishimani A SN, Gautam SC. Hemodynamic and respiratory changes during laparoscopic cholecystectomy with high and response to laparoscopic cholecystectomy with abdominal wall lift or conventional method. *Eur J Anesth* 1996; 13(2): 147.
 10. Holzman M. Sharp K, Richards W. Hypercarbia during CO₂ gas insufflation for therapeutic laparoscopy. A note of caution. *Surg Laparosc Endosc* 1992; 2: 11-14.
 11. Koivusclo A, Kellokumpu I, Ristkari S, Lindgren L. Splanchnic and renal deterioration during and after laparoscopic cholecystectomy: a comparison of CO₂ pneumoperitoneum and the abdominal wall lift method. *Anesthesia Analgesia* 1997; 85(4): 886-891.
 12. Otani T, Ku T, Fukasaw T, Osawa T, Seki F, Ykoyama T, Kawamura Y, Makuuchi M. A flower-shaped cannula for three incision laparoscopic cholecystectomy. *Surgical Endoscopy* 1998; 12(2): 79-80.
 13. Brampton WJ, Watson RJ. Arterial to end-tidal CO₂ tension difference during laparoscopy. *Anaesthesia* 1990; 45: 210-214.
 14. Dubais F, Berthelot G, Levard H. Laparoscopic cholecystectomy, historical perspective and personal experience. *Surg Laparosc Endosc* 1991; 1: 52-57.
 15. Craig DB. Postoperative recovery of pulmonary function. *Anaesthesia Analgesia* 1981; 60: 46-52.
 16. Wittgen CM, Andrus CH, Fitzgerald SD, et al. Analysis of the hemodynamic and ventilatory effects of laparoscopic cholecystectomy. *Arch Surg* 1991; 126:997-1001.
 17. Ponsky JL. Complications of laparoscopic cholecystectomy. *Am J Surg* 1991; 161: 393-395.
 18. Johnson PL, Sibert KS. Laparoscopy, gasless vs. CO₂ pneumoperitoneum. *J Rep Surg* 1997; 42(5): 255-259.