

ACUTE GENERALIZED PUSTULAR PSORIASIS AND IDIOPATHIC HYPOPARATHYROIDISM IN AN ADOLESCENT GIRL

Sh.S.Ashkevari* and A.Maboodi

Department of Dermatology, Razi Medical Center, School of Medicine, Guilan University of Medical Sciences, Rasht, Iran

Abstract- Generalized pustular psoriasis with hypoparathyroidism has been reported previously often as a post thyroidectomy syndrome with hypoalbuminemia and hypocalcemia. But reports on association of pustular psoriasis with idiopathic hypoparathyroidism are very rare, and almost all of them occurred in patients with known psoriasis vulgaris. We report one of the youngest cases of this association in a 17 year old girl without previous history of psoriasis which her eruption disappeared completely after the correction of hypocalcemia and remained free of eruptions until 6 months afterward. This case adds further evidence to the importance of calcium in the pathogenesis of at least some forms of psoriasis.

Acta Medica Iranica, 42(4): 300-302; 2004

Key words: Psoriasis, hypoparathyroidism, hypocalcemia

INTRODUCTION

Psoriasis, a common papulosquamous disease of the skin, affects about 1-3% of the population, with a peak incidence in the third decade of life.

The cause of psoriasis remains obscure, but a family history is found in 30% of patients and HLA-CW6 is most strongly associated with it (relative risk of 24). Despite the elucidation of numerous biochemical abnormalities affecting cyclic nucleotides, polyamines and arachidonic acid metabolism, immunological abnormalities of both humoral and cell mediate immunity and recently free radical generation abnormality, the pathogenesis of psoriasis has remained unclear; but some factors are known to be able to trigger, precipitate or aggravate the disease process, including drugs, severe sunlight and rarely metabolic disorders such as hypocalcemia of primary or secondary type.

We report a very rare association of generalized

pustular psoriasis with idiopathic hypoparathyroidism responding completely to calcium supplementation that adds further evidence of possible etiologic role for calcium in the pathogenesis of at least some forms of psoriasis.

CASE REPORT

A 17 year old female patient with known idiopathic hypoparathyroidism of 4 years duration was admitted in the dermatologic ward of the Razi Hospital of Rasht with one month history of acute generalized cutaneous eruption, in August 2001. She had been under treatment with calcium carbonate and rocaltrol irregularly, but ceased taking her medications about 6 months before admission.

Physical examination on admission showed a febrile patient (oral temperature of 38.2°C) with widespread rupioid erythematous plaques on scalp, trunk, axillary and crural areas, and extremities with sparing of the palms and soles (Figures 1 and 2). Soon the majority of lesions became pustular and many new pustular eruptions appeared. Hair, nail and mucosa were normal. Trousseau's and Chvostek's signs were positive.

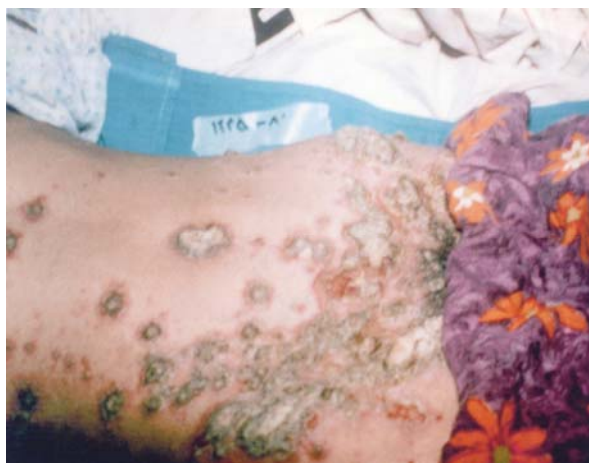Received: 9 March 2003, Revised: 21 Dec. 2003, Accepted: 24 Dec. 2003

*Corresponding Author:

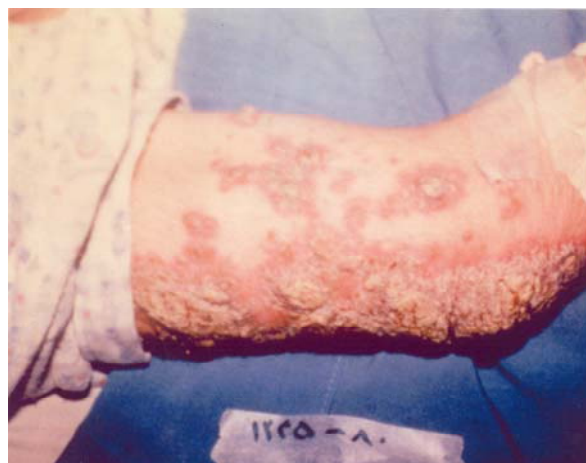Sh. S. Ashkevari, Department of Dermatology, Razi Medical Center, School of Medicine, Guilan University of Medical Sciences, Rasht, Iran

Tel: +98 131 5550028, Fax: +98 131 5559787

E-mail: Amaboodi@yahoo.com



A



B

Fig. 1. Disseminated pustular lesions, in abdomen (A) and arm (B).

Laboratory studies revealed a white blood count of 17,000 (PMN, 88%), total serum calcium of 6.5 mg/dl, serum phosphorus of 10.7 mg/dl and a serum albumin of 3.9 g/L with total protein of 6.8 g/L. Other paraclinical tests such as CRP, ESR, FBS, LFT, Mg and thyroid tests were normal.

A skin biopsy was taken from a pustular lesion and light microscopic examination revealed a subcorneal spongiform pustule filled with neutrophils that was consistent with the clinical diagnosis of

generalized pustular psoriasis (GPP) (Fig 3).

Treatment was started with parenteral rehydration, intravenous calcium gluconate (1g/day/2days), syrup of Al(oh)3, oral calcium carbonate (500 mg TDS) and vitamin D, 600,000 units stat. Over the next days, serum calcium levels became normal and after 10 days the pustular lesions cleared completely (Fig 4), and on the follow up visits 6 months afterward the patient was devoid of psoriatic lesions without any antipsoriatic medications.

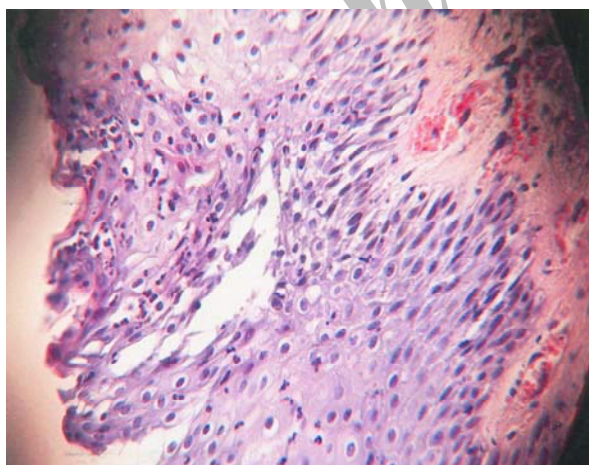


Fig. 2. Subcorneal pustule filled with neutrophils (H&E x 100).

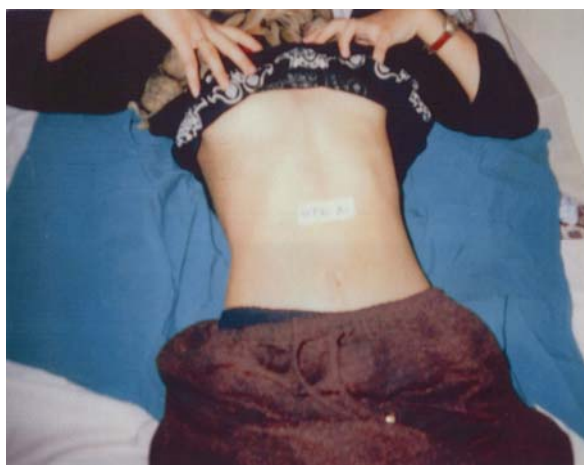

Fig. 3. Complete clearing of the pustular lesions after 10 days.

DISCUSSION

Despite the elucidation of numerous biochemical, immunological, genetic and recently free radical generation abnormalities, the exact pathogenesis of psoriasis has remained unclear, but some factors are known to be able to trigger, participate or aggravate the disease process. One of these factors is hypocalcemia of primary (IHP) or secondary (due to hypoalbuminemia or malabsorption or as a post thyroidectomy syndrome of HP with hypoalbuminemia) origin. It has been suggested that calcium hemostasis may be involved in the development or exacerbation of psoriasis because hypocalcemia may damage cell adhesion molecules, such as cadherins which dependent on calcium (1). On the other hand vitamin D and its analogs affect cell differentiation, proliferation and immunity.

Hypocalcemia is often revealed in impetigo herpetiformis of pregnancy and GPP as a secondary phenomenon related to hypoalbuminemia or malabsorption (2). Also there are reports on GPP occurring in patients with hypoparathyroidism that the majority of them belong to postthyroidectomy HP patients, and very rare cases have been reported on GPP occurring in patients with IHP which were cured by correction of hypocalcemia using calcium and vitamin D3 (3-5). This low calcium level was not seen to be due to hypoalbuminemia, since the serum albumin level was not low in IHP as it was normal in our case. On the other hand almost all reported cases

of GPP occurring in HP belong to middle aged patients with known previous psoriasis vulgaris (2-5), where as we report one of the youngest cases of this very rare association of GPP with IHP with dramatic response to calcium and vitamin D3 that had no previous personal or family history of psoriasis until admission. So with regard to literature and our report, we stress in considering an important but not well understood role for calcium in pathogenesis of at least some forms of psoriasis especially in GPP.

REFERENCES

1. Hosomi J, Hosoi J, Abe E, Suda T, Kuroki T. Regulation of terminal differentiation of cultured mouse epidermal cells by 1 alpha,25- dihydroxyvitamin D3. *Endocrinology*. 1983; 113(6): 1950-1957.
2. Moynihan GD, Ruppe JP Jr. Impetigo herpetiformis and hypoparathyroidism. *Arch Dermatol*. 1985; 121(10): 1330-1331.
3. Stewart AF, Battaglini-Sabetta J, Millstone L. Hypocalcemia-induced pustular psoriasis of von Zumbusch. New experience with an old syndrome. *Ann Intern Med*. 1984; 100(5): 677-680.
4. Risum G. Psoriasis exacerbated by hypoparathyroidism with hypocalcemia. *Br J Dermatol*. 1973; 89(3): 309-312.
5. Kawamura A, Kinoshita MT, Suzuki H. Generalized pustular psoriasis with hypoparathyroidism. *Eur J Dermatol*. 1999; 9(7): 574-576.