

# A CASE OF SEVERE NECK AND UPPER THORACIC SUBCUTANEOUS EMPHYSEMA AFTER POSTOPERATIVE VOMITING

A. Movafegh\*, G. Shoeibi and MH. Ghaffari

Department of Anesthesiology, Shariati Hospital, Tehran University of Medical Sciences, Tehran, Iran

**Abstract-** Subcutaneous emphysema is a rare complication of postoperative nausea and vomiting and can lead to airway compromise. We describe a case of delayed, severe subcutaneous emphysema after postoperative vomiting which fortunately did not lead to airway compromise and eliminated with conservative management. Rough and difficult laryngoscopy and intubation, presence of clots and bloody discharge after extubation, beginning of subcutaneous emphysema in the neck spreading caudally to the chest and fibroptic bronchoscopic findings all confirmed tracheal trauma as the cause. In this case the late onset of the subcutaneous emphysema, good response to conservative treatment and spontaneous resolution is considerable.

*Acta Medica Iranica*, 42(4): 303-306; 2004

**Key words:** Postoperative nausea and vomiting, subcutaneous emphysema, airway compromise

## INTRODUCTION

Although postoperative nausea and vomiting is the most common complication after general anesthesia (1), it rarely produces life threatening complications in the patient. One of these rare complications is subcutaneous emphysema which can lead to airway compromise and necessitate intubation (2). We describe here a case of subcutaneous emphysema after postoperative vomiting which fortunately did not lead to airway compromise.

## CASE REPORT

A 14-year old boy had sustained multiple trauma two years before admission after the ceiling of his house fell down on him. At that time he had abdominal trauma, laceration of the guts and bladder, intraperitoneal hemorrhage and fracture of the pelvic

and right femur. After a few operations he left bedridden in the ICU and home for a long period of time and this ended up in bedsores, along with deformities of pelvis and lower extremities. He was admitted to the hospital for repair of these deformities.

The significant points in his physical examination were obesity (BMI, 30), Mallampati class 1 assessment and a thyromental length of more than 6 cm. He was a candidate for general anesthesia. After administration of 10 µg sufentanil, 300 mg of sodium thiopental and 35 mg of atracurium, a number 3 blade was used to intubate the patient with a disposable cuffed endotracheal tube (ID, 7). The patient experienced a rough, difficult intubation performed several times by an inexperienced person. The anesthesia was maintained by the use of 0.7% halothane, N<sub>2</sub>O (50%) and at times sufentanil and atracurium. Neuromuscular blockade was reversed by administration of neostigmin and atropine at the end of operation. When the patient awoke, the trachea was extubated. Blood clots were seen along endotracheal tube. On suctioning of the oral cavity the discharge was bloody. Patient was kept in recovery room under close observation for a longer

Received: 9 Aug. 2003, Revised: 5 Nov. 2003, Accepted: 3 March 2004

**\*Corresponding Author:**

A. Movafegh, Department of Anesthesiology, Shariati Hospital, School of Medicine, Tehran University of Medical Sciences, Tehran, Iran  
Tel: +98 21 (09123021389), Fax: +98 21  
E-mail: movafegh@sina.tums.ac.ir

### Subcutaneous emphysema after postoperative vomiting

than usual period and eventually was transferred without any complication. Two hours later he first had nausea and then a severe attack of vomiting in the radiology room. His attendants then noticed an edema over the neck region. The patient was alert and had no breathing problem such as dyspnea or tachypnea. The physical exam revealed visible, progressive swelling and palpable crepitus over the neck and upper thorax, but the auscultation of the lungs was normal. There was no evidence of pneumomediastinum or pneumothorax on the post operative chest radiography but subcutaneous emphysema was seen (Fig 1).

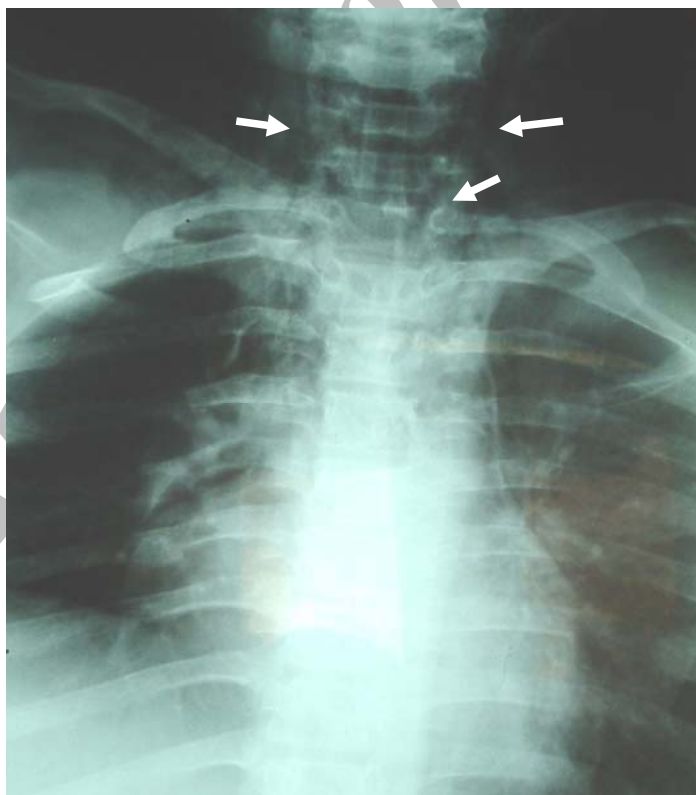
The patient received antibiotics (cefazolin 1g bid). The esophagus was normal in esophagography with barium contrast but some evidence of laryngeal and subglottic lesions were found on fibroptic bronchoscopy. After two days, the emphysema diminished considerably but recurrent vomiting aggravated the problem once again. By the tenth postoperative day the subcutaneous air was

completely reabsorbed with conservative treatment and the patient was discharged.

## DISCUSSION

Three differential diagnoses are considered for emphysema after vomiting: 1) spontaneous rupture of esophagus caused by vomiting (Boerhaave's syndrome), 2) alveolar rupture and 3) trauma to the trachea and hypopharynx.

Boerhaave's syndrome leads to mediastinitis and presents with the triad of vomiting, chest pain and subcutaneous emphysema (2, 3), all three of them may not be present at the same time. Today, the morbidity and mortality of mediastinitis has been reduced due to early diagnosis and aggressive surgical treatment. Several reports have shown successful medical treatment, when the tearing and leakage from the esophagus is minimal (3, 4). In our patient there was no chest pain and x-ray study did not approve this diagnosis.



**Fig. 1.** Subcutaneous emphysema in neck and upper chest (white arrows). Note that subcutaneous emphysema in neck is more than chest and no evidence of pneumothorax or pneumomediastinum is present.

Alveolar rupture is other differential diagnosis. Increased alveolar pressure produced by Valsalva's maneuver during retching and vomiting causes alveolar rupture (4, 5). Air enters the lung intersitium and then travels up along the pulmonary vascular sheaths, where it enters the mediastinum and then dissects the soft tissue planes of the neck, producing pneumomediastinum and subcutaneous emphysema. Some reports have been published previously but few of them have caused serious airway compromise (2, 5-7). Although probable, this was not the best diagnosis in our patient, because no sign of pneumomediastinum could be found in his chest x-ray while alveolar rupture certainly leads to pneumomediastinum preceding subcutaneous emphysema. On the other hand clinical signs in alveolar rupture are first observed in the lower parts of the chest, and then they progress upward to the neck region. In our case subcutaneous emphysema started from the neck spreading downward to the chest.

Trauma to the soft tissue of the pharynx, hypopharynx and trachea which lead to subcutaneous emphysema are caused by laryngoscopy, intubation and over inflation of the endotracheal tube cuff (8, 9). Tracheal rupture is a rare complication of intubation and most commonly associated with direct trauma to the neck and thorax. Factors predisposing to tracheal rupture during intubation are as below:

1. Mechanical causes of tracheal injury during intubation:
  - a. overinflation of the endotracheal tube cuff.
  - b. multiple attempts at intubation
  - c. repositioning the tube without deflating the cuff.
  - d. stylet protruding from the endotracheal tube.
  - e. patient coughing while intubated.
  - f. abrupt head and neck movement while intubated.
2. Anatomical factors associated with tracheal injury:
  - a. congenital tracheal abnormalities.
  - b. weakness of the membranous trachea.
  - c. chronic obstructive airway disease.
  - d. chronic steroid use.

The most frequent cause of tracheal injury associated with intubation is excessive cuff-to-

tracheal wall pressure. In a large percentage of cases, these injuries have been associated in using endotracheal tubes with high pressure, low volume cuffs (10). In our case high volume, low pressure endotracheal tube was used and cuff was not overinflated.

In patients who survive an acute tracheobronchial disruption after intubation, radiography invariably shows signs suggesting the injury. These include subcutaneous emphysema, tracheal bleeding, pneumothorax or pneumomediastinum. There is also difficulty with mechanical ventilation. The time of onset of symptoms varies widely, from immediately after intubation to several days after that. The treatment of tracheal rupture is usually surgical, although conservative measures have also been shown to be effective (11). Fortunately this case responded well to conservative treatment.

In our patient, rough and difficult laryngoscopy and intubation, presence of clots and bloody discharge after extubation, beginning of subcutaneous emphysema in the neck spreading caudally to the chest and fibroptic bronchoscopic findings all confirmed tracheal trauma. But why didn't the emphysema start during or immediately after anesthesia? Probably it was the retching, vomiting and Valsalva maneuver which completed the rupture of trachea initiated by the intubation. This is why air leakage stopped and subcutaneous emphysema diminished while resting and increased after vomiting.

In conclusion, nausea and vomiting is a common postoperative complication but rarely does it cause or aggravate subcutaneous emphysema which may lead to airway compromise. In this case the late onset of the subcutaneous emphysema, good response to conservative treatment and spontaneous resolution is considerable.

## REFERENCES

1. Feely TW, Macario A. The postoperative care unit. In: Miller RD, editor. Anesthesia. 5<sup>th</sup> ed. Philadelphia: Churchill Livingstone; 2000. p. 2302-2323.
2. Schumann R, Polaner DM. Massive subcutaneous emphysema and sudden airway compromise after postoperative vomiting. *Anesth Analg*. 1999; 89(3): 796-797.

### Subcutaneous emphysema after postoperative vomiting

3. Brauer RB, Liebermann-Meffert D, Stein HJ, Bartels H, Siewert JR. Boerhavve's syndrome: analysis of the literature and report of 18 new cases. *Dis Esophagus*. 1997; 10(1): 64-68.
4. Pate JW, Walker WA, Cole FH Jr, Owen EW, Johnson WH. Spontaneous rupture of the esophagus: a 30-year experience. *Ann Thorac Surg*. 1989; 47(5): 689-692.
5. Bremner WG, Kumar CM. Delayed surgical emphysema, pneumomediastinum and bilateral pneumothoraces after postoperative vomiting. *Br J Anaesth*. 1993; 71(2): 296-297.
6. Maunder RJ, Pierson DJ, Hudson LD. Subcutaneous and mediastinal emphysema. Pathophysiology, diagnosis and management. *Arch Intern Med*. 1984; 144(7): 1447-1453.
7. Dolinski SY, Meek E, Groban L. An unusual case of subcutaneous emphysema. *Anesth Analg*. 1999; 89(1): 150-151.
8. Marty-Ane CH, Picard E, Jonquet O, Mary H. Membranous tracheal rupture after endotracheal intubation. *Ann Thorac Surg*. 1995; 60(5): 1367-1371.
9. Levine PA. Hypopharyngeal perforation. An untoward complication of endotracheal intubation. *Arch Otolaryngol*. 1980; 106(9): 578-580.
10. Harris R, Joseph A. Acute tracheal rupture related to endotracheal intubation: case report. *J Emerg Med*. 2000; 18(1): 35-39.
11. Sternfeld D, Wright S. Tracheal rupture and the creation of a false passage after emergency intubation. *Ann Emerg Med*. 2003; 42(1): 88-92.

Archive of SID