

ILIZAROV METHOD IN TREATMENT OF TIBIAL AND FEMORAL INFECTED NON-UNIONS IN PATIENTS WITH HIGH-ENERGY TRAUMA AND BATTLE-FIELD WOUNDS

M. N. Tahmasebi* and Sh. Jalali Mazlouman

Department of Orthopedic Surgery, Shariati Hospital, School of Medicine, Tehran University of Medical Sciences, Tehran, Iran

Abstract- This study was performed to evaluate the results of 14 years of application of Ilizarov method in treatment of infected non-unions of tibia and femur in patients with severe trauma and battlefield wounds. Seventeen patients with long bone nonunion (14 were with infected nonunion of tibia out of whom two were associated with tibial bone defects and 3 with infected non-union of femur) were admitted for the study. After preliminary debridement (in infected cases with draining fistulae) and preparation for external fixation, ring fixator was introduced and compression alone or compression and distraction (in atrophic non-unions) were enforced on fragments to induce union. Bone transfer was used in cases with bone defects. All cases resulted in complete union and had infection controlled. The mean time of union was 8 months in tibial infected non-unions and 10 months in infected femoral non-unions. In cases with bone defects, the mean union time was 12 months. In selected cases of infected tibial and femoral non-union, Ilizarov is an efficient method of treatment, especially with bone transfer in cases with bone defects. The application of this method in battle-field wounds has resulted in noticeable outcomes. Patient's tolerance was low in cases of femoral Ilizarov, but this is the method of choice for tibial infected non-unions, taking into account the lack of the need for long-term antibiotic use.

Acta Medica Iranica, 42(5): 343-349; 2004

Key words: Ilizarov method, non-union, battle-field wounds, tibia

INTRODUCTION

Ilizarov method, which is used in the treatment of complicated fractures of long bones, was first introduced in 1950 by Gavril Abramovich Ilizarov, who was born in Caucasus, in the Soviet Union, and worked in Siberia. This revolutionary method for treating fractures, non-unions, deformities and other bone defects involved the use of a circular external fixator.

During the next decade his research led him to the techniques of physal distraction, corticotomy lengthening, bone transport and the theory of tension stress, which was the method by which Ilizarov showed that controlled, mechanically applied tension stress would produce reliable and reproducible regeneration of bone and soft tissue. It was not until 1967 that his first case was reported. Ilizarov's methods were brought to the west in 1981 by an Italian doctor, Bianchi-Maiocchi (1).

The history of Ilizarov method in Iran goes back to 1987, when one of the authors attended a conference held by Ilizarov himself in Switzerland. Back then, a number of war-time veterans were referred to Sasan and Shariati hospitals in Tehran due to battle-field wound complications, especially septic non-union of femur and tibia. These patients had

Received: 3 May 2003, Revised: 3 Jan. 2003, Accepted: 3 Mar. 2004

* Corresponding Author:

M. N. Tahmasebi, Department of Orthopedic Surgery, Shariati Hospital, School of Medicine, Tehran University of Medical Sciences, Tehran, Iran

Tel: +98 21 84902388, Fax: +98 21

E-mail: mntahmasebi@hotmail.com

been previously managed in other centers both in and outside the country with several fruitless classic operative episodes and methods. After return from Switzerland, Ilizarov method was used on these war-time veterans by one of the authors for the first time in Iran. The results were such astonishing that it was soon used by other surgeons throughout the country for battle wounds and to-date, is being used for other patients routinely. The following paper reports on the results of treatment of tibial and femoral infected non-unions by this method in the past 14 years.

MATERIALS AND METHODS

This is a case-series study performed on patients with high-velocity trauma or battle-field wounds who were admitted in the department of Orthopedic Surgery in Shariati and Sassan Hospitals between 1987 and 2002 with septic non-union of tibia or femur. Our cases were included in the study taking into account the method of treatment used for their management, regardless of age, gender or other epidemiologic variables. These patients had been referred to orthopedic clinic due to septic non-union of tibia and femur and had already undergone several unsuccessful operations to eradicate infection and induction of union before admission. They had been finally referred to the mentioned centers and were treated with Ilizarov method.

The method was chosen depended on the type of septic non-union that had occurred. In cases with septic non-union without atrophy, inter-fragmental compression alone and in atrophic non-unions intermittent inter-fragmental compression and distraction were enforced by Ilizarov apparatus. To prevent angulation, in cases with femoral infected non-union, we first used intramedullary femoral nailing and then applied Ilizarov external fixator and compression distraction was performed along the femoral nail.

Cases were followed up as outpatients in clinic until complete union occurred. These patients were evaluated by taking a meticulous history and performing a detailed physical examination. Imaging methods (plain radiography, CT and bone scans when necessary), peripheral hematological indices and

serum biochemical and inflammatory markers were checked in all patients. Our main tool for follow-up was physical examination and plain radiography. Our definition for non-union was a minimum elapsed time of 9 months since surgery without progressive signs of healing (clinical and radiographic) for 3 months.

Our variables in this study, apart from epidemiologic data, were type of non-union, the method of treatment with Ilizarov apparatus, union and its duration, eradication of infection and the number of operations before introduction of Ilizarov apparatus.

We investigated 17 cases in this study who were 20 to 65 year-old male patients. Cases were referred with septic non-union of tibia and femur among which, 2 had associated tibial bone defects. Three of the cases were admitted with femoral infected non-union and 14 with septic non-union of tibia. We used ring Ilizarov with 2 rings in proximal and 2 rings in distal fragments for infected tibial non-unions (Fig. 1). On the other hand, in cases with septic non union of femur, after inserting a femoral intramedullary nail, two half rings were used in proximal and 2 half rings in distal fragment (Fig. 2). In cases with frank infection and purulence, debridement and extraction of necrotic tissues were performed at first and then Ilizarov apparatus for compression was introduced. In cases with hypertrophic non-union, 0.25 mm compression four times a day, and in cases with atrophic non-union, intermittent compression and distraction on 3-day cycles, 0.25 mm four times a day, and in cases with bone transfer, 0.25 mm, four times a day for transfer of the bone segment were enforced with Ilizarov apparatus.

RESULTS

From 17 investigated cases, 3 cases were due to septic non-union of femur and the other 14 were due to infected non-union of tibia (Fig. 3) out of which, 2 cases were associated with tibial bone defects. Cases that were evaluated in this study were in the age-range of 20 to 65 years, with a mean age of 35.7 years. Patients were all males with union times of 3 to 17 months in tibial fractures with a mean union time of 8 months. The mean union time in patients

with infected femoral non-union was 10 months. In patients with bone transport the mean transfer and union time was 12 months. Infections were controlled spontaneously without antibiotic usage.

Table 1 shows a detailed profile of cases presented in this study. One of our cases was a femoral septic nonunion that was complicated upon a femoral segmental comminuted fracture and had undergone 20 operative sessions before treatment with Ilizarov. Alternative compression and distraction was enforced by Ilizarov apparatus. With complete weight bearing union occurred after 12 months and normal limb function returned. In the two cases which were associated with bone defect, bone transfer was used as an adjunctive measure to Ilizarov fixation. One of them was associated with a 10 cm bone defect and the bone transport took about

3.5 months, but union was delayed and after 17 months of fixation with Ilizarov, due to pain and mild pin-tract infection, patients' intolerance and associated psychological problems Ilizarov fixator was removed and the limb was immobilized with PTB cast.

After 3 months of weight bearing, union was obtained. In this patient mild reflex sympathetic dystrophy occurred that was managed with physio- and pharmacotherapy. The other case was a 47 year old man in whom bone transport was completed after 4 months with Ilizarov fixation but union did not happen until 8 months and the case was complicated with atrophic non-union of tibia that was treated with bone grafting. Also a mild ankle equinus deformity happened due to patients' weight-bearing that was controlled with physiotherapy.

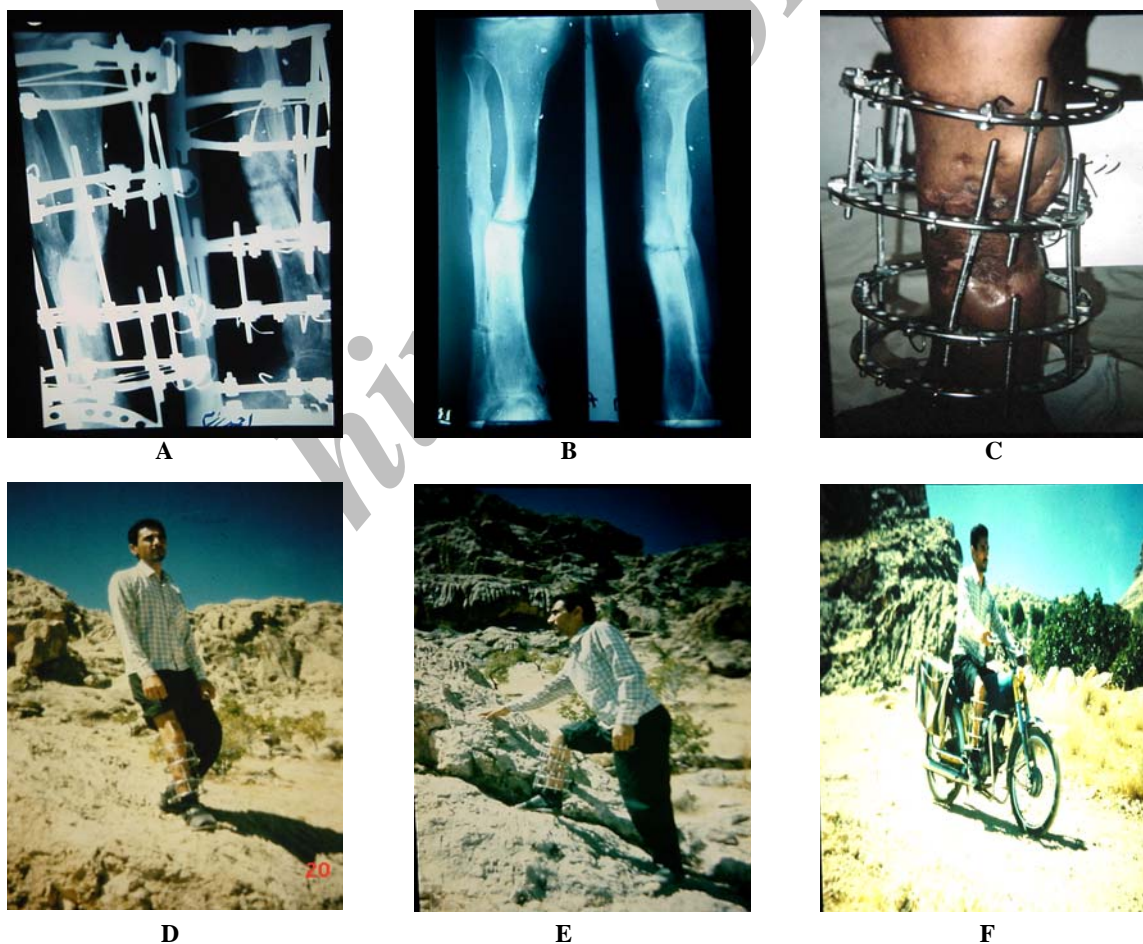


Fig. 1. Ilizarov fixator (A) used in an Iraq-war veteran with OTA type C3.3 tibial fracture (B). Patient had scarred poor skin condition (C) that precluded the use of conventional surgical techniques. The patient soon returned to normal daily activities (D-F).

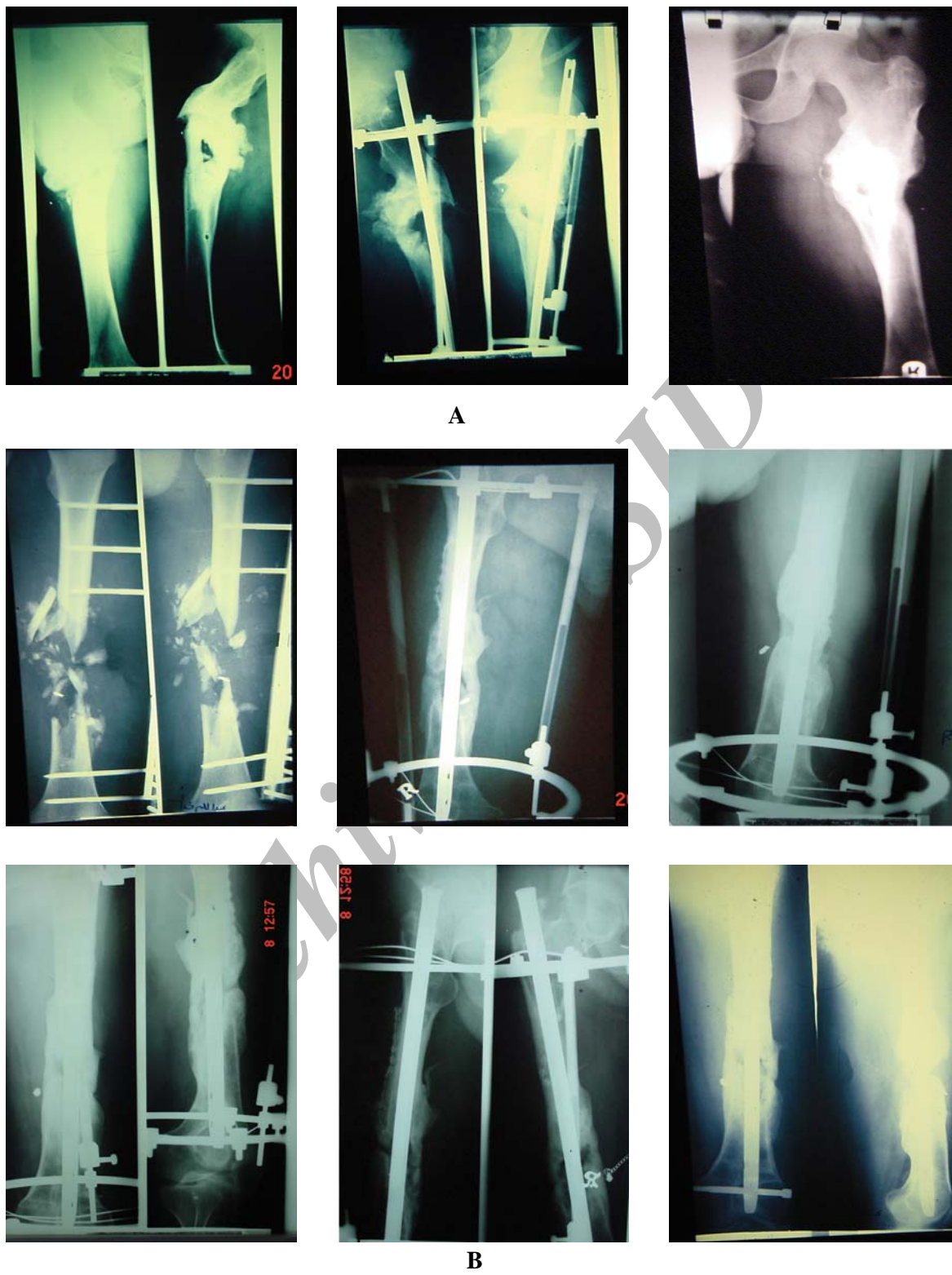

Fig. 2. Ilizarov fixator in association with femoral intramedullary nailing used in a proximal femoral shaft fracture (A) and femoral diaphyseal fracture (B).

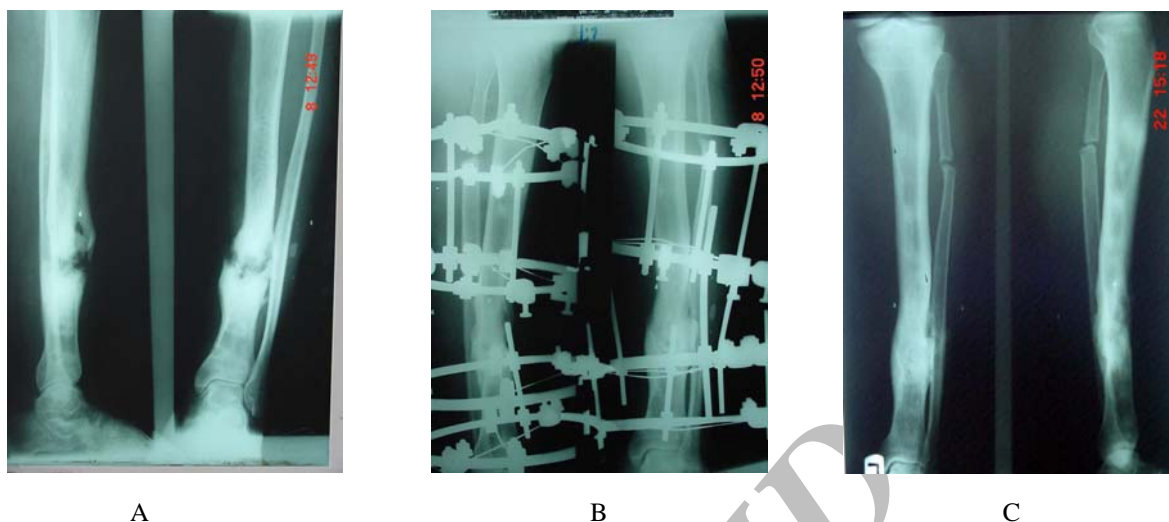


Fig. 3. Ilizarov method was used successfully in treatment of severe battle field injuries. This patient, an Iraq-war veteran, was an example. Preoperative (A), in the course of treatment (B) and today's situation (C).

Table 1. Detailed characteristics of cases presented in this study

Age of the Patient	Location of Septic Nonunion	Type of Septic Nonunion	Number of previous Operations	Type of treatment with Ilizarov	Time of Union (Months)
29	Tibia	Hypertrophic	4	Compression	3
20	Tibia	Atrophic	4	Compression	6
37	Femur	Hypertrophic	18	Alternate Compression, Distraction	12
30	Tibia	Atrophic	5	Alternate Compression, Distraction	11
44	Tibia	Hypertrophic	3	Compression	5
28	Tibia	Hypertrophic	3	Compression	7
34	Femur	Hypertrophic	4	Compression	11
26	Tibia	Hypertrophic	3	Compression	7
34	Tibia	Atrophic	4	Compression	8
39	Tibia	Hypertrophic	3	Compression	6
30	Tibia	Atrophic	5	Alternate Compression, Distraction	10
25	Femur	Hypertrophic	7	Alternate Compression, Distraction	7
32	Tibia	Atrophic	2	Compression	9
24	Tibia	Hypertrophic	2	Compression	8
65	Tibia	Hypertrophic	1	Compression	5
37	Tibia	Atrophic	2	Compression	11
45	Tibia	Atrophic	2	Compression	17

DISCUSSION

In high-energy traumatic wounds and battlefield injuries certain severe complications like infection, non-union with or without bone defect and deformity are common. It is due to severe destruction of soft tissue and comminution of underlying bone and elimination of local humeral and cellular defense mechanisms and destruction of periosteal layer and endosteal vasculature. Septic non-union is one of these complications that make conventional management methods ineffective and requires several operations and long term treatment. Due to disruption of periosteal vascular bed and dysfunction of local defense mechanism, biologic methods of treatment like Ilizarov that increase the injured site circulation and osteogenesis are the preferred methods of treatment in these injuries (2).

The Ilizarov method has proved its efficacy in treatment of post-traumatic infected non-unions of tibia where other types of treatment had failed.

In this study 14 cases with septic nonunion of tibia were evaluated. The mean time for union (between the application of fixator and radiologic and clinical union) was 8 months in tibial infected non-unions and 10 months in femoral non-unions. In cases with bone defects the mean union time was 12 months. In a study performed by Tranquilli *et al.* in Italy on 20 patients with non-union of tibia the mean time of union was 4.5 months and the result was always union (3). In another study by Marsh *et al.* 40 out of 46 non-unions and all infected cases were eliminated by Ilizarov method and a high level of patient satisfaction was obtained (4). Menon *et al.*, in a study with similar results to ours concluded that there was a role for the use of the Ilizarov fixator with nail retention in resistant long bone diaphyseal nonunion in carefully selected patients and that this method could achieve high union rates where other treatment methods had failed (5). These studies exemplify the applicability of Ilizarov method in treatment of infected non-unions. The main advantages of this method are:

1) Spontaneous control of infection in presence of osteogenesis even without the need for the use of antibiotics, as infection dissolves in osteogenesis.

2) Provision of needed stability for weight-bearing and patient mobilization, again an important factor in induction of osteogenesis and union (Fig. 1).

3) Minimal tissue destruction with least interference with normal local healing process due to the structure of apparatus, which is itself helpful in reunion.

Ilizarov method has undergone several modifications to increase the efficacy of treatment and patient's acceptability; for example, Rozbruch *et al.* used a computer programmable Ilizarov spatial frame in two cases of hypertrophic non-union of the tibia with deformity for which distraction was utilized, yielding noticeable results (6).

Despite the mentioned advantages and capabilities of Ilizarov method in correction of non-union, one should not forget the associated complications and set-backs in this method. In a study to determine the sources and magnitude of residual morbidity after successful treatment of tibial nonunion using the Ilizarov device and techniques, Sanders *et al.* concluded that ankle pain with disability is the major source of residual disability after successful use of the Ilizarov device for the treatment of tibial non-union (7). In our study, ankle complaints happened in only one patient and the reflex sympathetic dystrophy was observed in another one, demonstrating considerable difference from the results of the above mentioned study.

Ilizarov method has been most commonly applied upon infected nonunion of tibia. In present study, three cases of hypertrophic infected nonunion of femur were evaluated with a mean union time of 10 months and mean number of 9 operative episodes before admission for Ilizarov application, pointing to the applicability of this method in other bones of body. Application of Ilizarov method is more difficult in femoral region. In both femoral and tibial non-unions with profuse purulence, primary debridement should be performed to enhance the rate of union.

To finalize, we conclude that Ilizarov external fixation is a useful method with several advantages and certain set-backs in treatment of tibial and femoral septic non-unions, especially in high-energy traumatic and battle field wounds where other methods of treatment have failed.

REFERENCES

1. Catagni M, Villa A. Non-union of the leg (tibia). In: Maiocchi AB, Aronson J, editors. Operative principles of Ilizarov: fracture, treatment, nonunion, osteomyelitis, lengthening deformity correction. Lippincott, Williams and Wilkins; 1991. p. 199-244.
2. Ilizarov GA, Green SA. The transosseous osteosynthesis: theoretical and clinical aspects of the regeneration and growth of tissue. Berlin-Heidelberg: Springer-Verlag Telos; 1992.
3. Tranquilli Leali P, Merolli A, Perrone V, Caruso L, Giannotta L. The effectiveness of the circular external fixator in the treatment of post-traumatic of the tibia nonunion. *Chir Organi Mov.* 2000 Jul-Sep;85(3):235-242.
4. Marsh DR, Shah S, Elliott J, Kurdy N. The Ilizarov method in nonunion, malunion and infection of fractures. *J Bone Joint Surg Br.* 1997 Mar;79(2):273-279.
5. Menon DK, Dougall TW, Pool RD, Simonis RB. Augmentative Ilizarov external fixation after failure of diaphyseal union with intramedullary nailing. *J Orthop Trauma.* 2002 Aug;16(7):491-497.
6. Rozbruch SR, Helfet DL, Blyakher A. Distraction of hypertrophic nonunion of tibia with deformity using Ilizarov/Taylor Spatial Frame. Report of two cases. *Arch Orthop Trauma Surg.* 2002 Jun;122(5):295-298.
7. Sanders DW, Galpin RD, Hosseini M, MacLeod MD. Morbidity resulting from the treatment of tibial nonunion with the Ilizarov frame. *Can J Surg.* 2002 Jun;45(3):196-200.

Archive of SID