

VULVAR LYMPHANGIOMA CIRCUMSCRIPTUM: A CASE REPORT

H. Sharami¹, F. Ghaemmaghami^{*2}, F. Yarandi², F. Milani² and N. Alizadeh²

1) Department of Gynecology and Obstetrics, School of Medicine, Gilan University of Medical Sciences, Gilan, Iran

2) Department of Gynecology and Obstetrics, School of Medicine, Tehran University of Medical Sciences, Tehran, Iran

Abstract- Lymphangioma circumscriptum is a benign lymphatic malformation which is localized to the skin and subcutaneous tissues. It consists of dilated lymph channels lined by normal endothelium. Primary vulvar involvement is very rare and only 28 cases have been reported till 2002. Here we report a case in an 18 years old girl who was referred to our gynecologic clinic with symptoms of pain, swelling and erythema of both labia majors of 5 years duration. She had taken various drugs but all had failed and the lesion was exterminated only after wide local excision surgery. Histological examination revealed multiple dilated vascular channels with an inflammatory infiltrate in papillary dermis and diagnosis of vulvar lymphangioma circumscriptum was made. After ten months follow up, there was no evidence of recurrence. Wide local excision may be the best treatment for extensive vulvar lymphangioma circumscriptum.

Acta Medica Iranica, 42(6): 458-460; 2004

Keywords: Vulvar lymphangioma circumscriptum, Lymphatic malformation, Lymphangioma circumscriptum

INTRODUCTION

Lymphangioma circumscriptum is a benign lymphatic malformation which is localized to the skin and subcutaneous tissues (1, 2). It consists of dilated lymph channels lined by normal endothelium (1). The typical picture involves a small number of vesicles on the skin which are usually present at birth or appear in early childhood (3-6). In subsequent years they tend to increase in number and size.

Vulvar involvement is very rare and often occurs as secondary type due to radical hysterectomy, pelvic lymphadenectomy, radiation for cervical cancer and Crohn's disease (3-6).

It clinically manifests with pseudovesicles, which bulge on the skin surface and can be mistaken for warts (7). The traditional treatment is surgical removal; recently, laser therapy has been recommended as an alternative procedure (3).

We report an unusual case of vulvar lymphangioma circumscriptum in a young girl without obvious cause.

CASE REPORT

An 18 years-old girl was referred to gynecologic clinic with diagnosis of labia major cellulites. She had a lesion with swelling, mild pruritus and watery secretion in vulvar surface for the past 5 years. The lesion had progressed in size and severity gradually. During the course of illness, she had experienced four episodes of recurrent acute cellulites, treated with antibiotics. The last acute presentation of her disease

Received: 9 Dec. 2003, Revised: 2 June 2004, Accepted: 23 Jun. 2004

***Corresponding Author:**

F. Ghaemmaghami, Department of Gynecology and Obstetrics, School of Medicine, Tehran University of Medical Sciences, Tehran, Iran

Tel: +98 21 6939320, Fax: +98 21 6937321

E-mail: valrec2@yahoo.com

had started with pain, swelling and erythema of both labia majors since 4 days before admission.

In physical examination, there were swelling, erythema and tenderness of both labia majors with clusters of vesicles in vulvar surface as well as skin thickness (Fig. 1). She had no lymph edema on mons or foot. She had taken various anti-fungus and anti-herpes drugs and corticosteroids for her problem without any benefit. No work up had been done for finding the cause of her disease. She had no lymphangiography because lymphangioma was superficial. She had no history of surgery, radiotherapy or gastrointestinal disease. After a course of antibiotic therapy and suppression of patient's acute signs and symptoms, she was examined again. Bilateral swelling of labia major with erythema, numerous papules, clusters of vesicles, skin thickness and wartlike lesions mostly on right labia major, were found. There was no specific finding in general examination.

Considering the clinical course of the disease, she underwent a biopsy from vulvar skin with suspicion of vulvar wart, in spite of her virginity and no history of sexual intercourse.

Since the patient was young and the lesion was extensive, we decided to perform an operation. We removed all involved area by a wide excision with 3 cm diameter in depth. After surgery, the sample was sent to pathology center and histological examination revealed multiple dilated vascular channels in the papillary dermis containing few erythrocytes and mostly fibrin, lined by a thin wall, consisting only of endothelial cells. There was an inflammatory infiltrate in the papillary dermis.

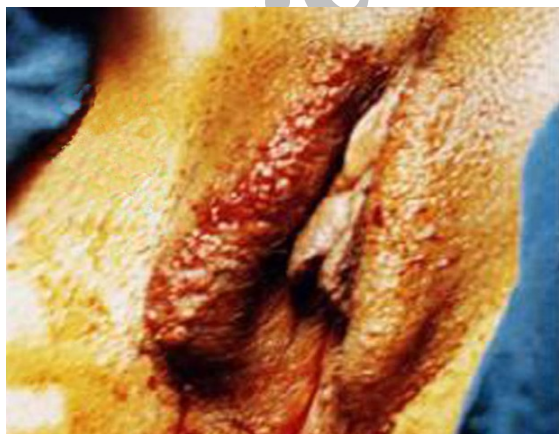

Fig. 1. Gross anatomy of lymphangioma circumscriptum.

The overlying epidermis was partly hyperkeratotic, with thinning of the stratum malpighii (Figures 2 and 3). There was no evidence of malignancy. The diagnosis was vulvar lymphangioma circumscriptum. After ten-month follow up, there was no evidence of recurrence.

DISCUSSION

Lymphangioma circumscriptum is rare in the vulva and only 28 cases have been reported till 2002 (8). The exact etiology of this malformation is unknown (1). This tumor may be congenital or acquired. Congenital forms of this tumor appear at birth or before 5 years of age. Acquired forms of it often occur in aged women secondary to radical hysterectomy, pelvic lymphadenectomy or radiotherapy after cervical cancer, which can cause damage to lymphatic system (8-11).

This patient had the symptoms of disease at the age of 13 years, with no history of surgery, radiation or Crohn's disease. But she had four episodes of acute cellulites. Since lymphatic system damage is suggested in pathophysiology of lymphangioma circumscriptum, her disease may be due to lymphatic system damage after recurrent cellulites, or an underlying lymphatic abnormality predisposed her to cellulites, resulting in lymphatic fibrosis and vulvar lymphangioma (6, 7). Another hypothesis is a congenital disease with late onset.

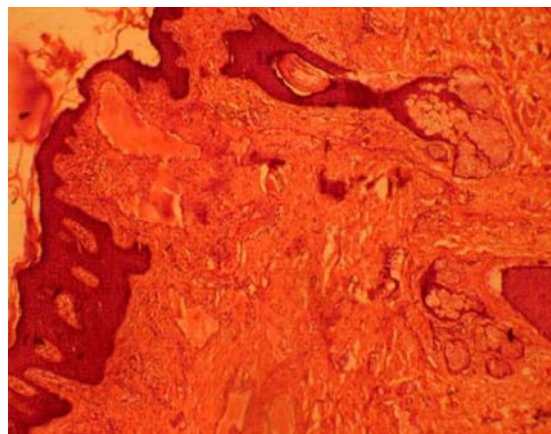


Fig. 2. Pathology of vulvar lymphangioma circumscriptum.

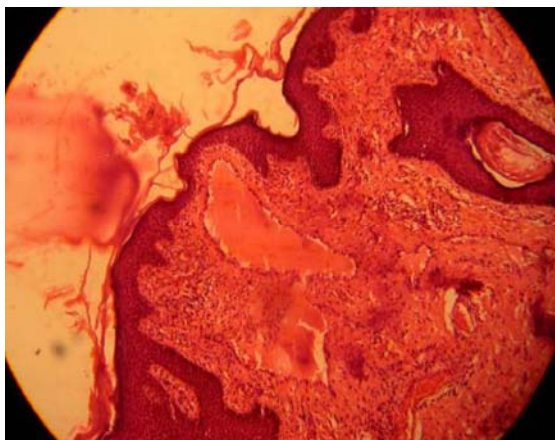


Fig. 3. Pathology of vulvar lymphangioma circumscriptum

Lymphangioma circumscriptum usually manifests with clusters of pseudovesicles with thin walls. But it may appear rarely as papules, nodules or wart-like lesions with pruritus, pain, secretion and cellulites. Since our patient's lesions were diffuse and extensive and the duration of disease was long (more than 5 years), hyperkeratosis and wart-like lesions may be due to long-term skin irritation.

There is no proven medical treatment for lymphangioma circumscriptum. The preferred treatment of lymphangioma circumscriptum is complete surgical excision, which sometimes fails and early recurrence is common. In this case lymphangioma was superficial and the lesion did not recur.

Recently, laser-therapy with CO₂ has been applied as an effective treatment for lymphangioma circumscriptum (6, 7, 12, 13). But in some cases, especially in those with extensive and deep lesions, it causes keloid formation (8). Because our patient was young and virgin and cosmetic aspect of treatment was important, we preferred excision by surgery because the lesion was extensive and there was possibility of keloid formation after laser-therapy.

Fortunately, after ten-month follow up, there was no evidence of postoperative complications or recurrence of lymphangioma circumscriptum.

REFERENCES

1. Mortimer PC. Disorders of lymphatic vessels. In: Champion RH, Burton JL, Burns DA, Breathnach SM. Rook/ Wilkinson/ Ebling textbook of dermatology. 6th ed. Boston: Blackwell Science; 1998. p. 2292.
2. Esquivias Gomez JI, Miranda-Romero A, Cuadrado Valles C, Bajo del Pozo C, Sanchez Sambucety P, Martinez Fernandez M, Aragonese Fraile H, Garcia Munoz M. Lymphangioma circumscriptum of the vulva. *Cutis*. 2001 Mar; 67(3):229-232.
3. Haas AF, Narurkar VA. Recalcitrant breast lymphangioma circumscriptum treated by UltraPulse carbon dioxide laser. *Dermatol Surg*. 1998 Aug; 24(8):893-895.
4. Weyers W, Nilles M, Konig M. [Lymphangioma circumscriptum cysticum following surgical and radiologic therapy]. *Hautarzt*. 1990 Feb; 41(2):102-104.
5. Celis AV, Gaughf CN, Sanguenza OP, Gourdin FW. Acquired lymphangiectasis. *South Med J*. 1999 Jan; 92(1):69-72.
6. Dap RF, van der Meijden WI. [Vulvar lymphangiectasias in Crohn's disease]. *Ned Tijdschr Geneesk*. 2000 Aug 26; 144(35):1692-1695.
7. Buckley DA, Barnes L. Vulvar lymphangiectasia due to recurrent cellulitis. *Clin Exp Dermatol*. 1996 May; 21(3):215-216.
8. Jappe U, Zimmermann T, Kahle B, Petzoldt D. Lymphangioma circumscriptum of the vulva following surgical and radiological therapy of cervical cancer. *Sex Transm Dis*. 2002 Sep; 29(9): 533-535.
9. Smith H, Genesen MC, Feddersen RM. Dermal lymphangiomas of the vulva and laser therapy: a case report and literature review. *Eur J Gynaecol Oncol*. 1999; 20(5-6):373-378.
10. Abu-Hamad A, Provencher D, Ganjei P, Penalver M. Lymphangioma circumscriptum of the vulva: case report and review of the literature. *Obstet Gynecol*. 1989 Mar; 73 (3 Pt 2):496-499.
11. Serpier H, Frecourt C, Cambie MP, Salmon-Ehr V, Esteve E, Kalis B. [Vulvar lymphangiectasis 14 years after treatment for epidermoid carcinoma of the cervix. Treatment with cryosurgery]. *Ann Dermatol Venereol*. 1996; 123(2):96-99.
12. Huilgol SC, Neill S, Barlow RJ. CO₂ laser therapy of vulval lymphangiectasia and lymphangioma circumscriptum. *Dermatol Surg*. 2002 Jul; 28(7):575-577.
13. Bartels U, Krauss T, Sattler B, Maghsudi M, Kuhn W. [Therapy of extensive lymphangioma of the vulva]. *Zentralbl Gynakol*. 1995; 117(4):220-223.