

DIAGNOSTIC VALUE OF SILVER-STAINED NUCLEOLAR ORGANIZER REGIONS IN OSTEOSARCOMA, FIBROUS DYSPLASIA AND OSSIFYING FIBROMA OF THE JAWS

M. Eslami¹, F. Baghaee¹ and M. Alaeddini^{2*}

1) Department of Oral Pathology, School of Dentistry, Tehran University of Medical Sciences, Tehran, Iran

2) Dental Research Center, School of Dentistry, Tehran University of Medical Sciences, Tehran, Iran

Abstract- It is sometimes difficult to recognize a jaw lesion as osteosarcoma, ossifying fibroma or fibrous dysplasia in routine hematoxylin and eosin staining and a more accurate technique is needed to differentiate these lesions. Many studies have shown the potential usefulness of silver-stained nucleolar organizer region (AgNOR) parameters for the diagnosis of various neoplasms. This study was carried out on 42 archival biopsy specimens of jaw lesions including 14 fibrous dysplasias, 14 ossifying fibromas and 14 osteosarcomas (10 well differentiated and 4 poorly differentiated). Number of AgNORs was evaluated on formalin-fixed, paraffin embedded sections. The mean AgNOR counts showed significant differences between these lesions. The mean counts of AgNORs were < 1 for fibrous dysplasia, 1 to 2.5 for ossifying fibroma and well differentiated osteosarcoma, and > 6 for poorly differentiated osteosarcoma. By considering a cutoff point of 1.81-2.5 for well differentiated osteosarcoma and 1-1.8 for ossifying fibroma, well differentiated osteosarcoma can be differentiated from ossifying fibroma with a sensitivity of 90% and a specificity of 64.3%. The area under the ROC curve was 0.84. The results in this study indicate that AgNOR staining is a useful technique for differential diagnosis of osteosarcoma, ossifying fibroma and fibrous dysplasia of jaws when it is difficult to recognize these lesions in routine hematoxylin and eosin staining.

Acta Medica Iranica, 43(4): 243-248; 2005

Key words: Ossifying fibroma, osteosarcoma, fibrous dysplasia, AgNOR staining

INTRODUCTION

Histopathologic appearances of some jaw lesions such as osteosarcoma, ossifying fibroma and fibrous dysplasia occupy a spectrum that may have considerable overlap. In some cases, a classic histopathologic appearance makes the diagnosis clear; however, when the picture is that of new bone formation in a background of cellular fibrous

connective tissue, the diagnosis is more difficult. These same features could occur in well differentiated osteosarcoma, ossifying fibroma and fibrous dysplasia (1). The primary differential diagnosis for fibrous dysplasia of the jaw is ossifying fibroma. Historically, attempts at differentiating the two lesions were based only on histological criteria, but most authorities now acknowledge that these criteria are unreliable (2). Low grade, well differentiated osteosarcoma may show only minimal cellular atypia of the lesional cells and abundant bone formation. On microscopic examinations, these lesions may be difficult to differentiate from benign bone lesions such as fibrous dysplasia or ossifying fibroma. Most osteosarcomas of the jaws tend to be

Received: 31 July 2004, Revised: 3 Oct. 2004, Accepted: 18 Dec. 2004

* Corresponding Author:

M. Eslami, Department of Oral Pathology, Faculty of Dentistry, Tehran University of Medical Sciences, Tehran, Iran
Tel: +98 21 66112432
Fax: +98 21 64432330
E-mail: malaeddini@tums.sina.ac.ir

better differentiated than osteosarcomas of the extragnathic skeleton (3).

Nucleolar organizer regions (NORs) represent loops of DNA activity transcribing to ribosomal RNA and thus to ribosomes and ultimately to protein. The NORs are associated with acidic, argyrophilic non-histonic proteins that are visualized with the use of a silver staining technique, the AgNOR technique (4). Silver stainable nucleolar organizer regions have been shown to be replicatory markers and many studies have shown the potential usefulness of AgNOR parameters like mean count area of distribution in the nucleus for the diagnosis of various neoplasms (5-8). AgNOR staining is an accurate and an easily performed technique (9).

To our knowledge, there have been no studies concerning diagnostic value of AgNOR staining in osteosarcoma, fibrous dysplasia, and ossifying fibroma of the jaws. The aim of this study is to determine the value of AgNOR staining in the differential diagnosis of these lesions.

MATERIAL AND METHODS

Material for the present study consisted of 42 archival biopsy specimens including 14 fibrous dysplasia, 14 ossifying fibroma, and 14 osteosarcomas. All osteosarcomas were graded according to Broders' classification to 10 well differentiated and 4 poorly differentiated osteosarcomas. All specimens were obtained from biopsy tissues arriving at the Department of Oral and Maxillofacial Pathology of the School of Dentistry and the archives of the Cancer Institute (Tehran University of Medical Sciences, Tehran, Iran) from

1966 to 2001. Diagnoses of these specimens were established by two of the authors following hematoxylin and eosin staining. This staining was used as the correct/ "gold standard" for comparison with the AgNOR-based diagnoses.

AgNOR staining was performed according to the guidelines established by the Committee on AgNOR Quantification (10). Each section was immersed in sodium citrate buffer (at pH 6.0) incubated in wet autoclave at 120°C for 20 min, then allowed to cool down to 37°C. The slides were then immersed in a freshly prepared silver staining solution containing one part by volume of 2% gelatin in 1% formic acid two parts of 25% aqueous silver nitrate solution at 37°C in a thermostatically controlled environment for 11 min. Then, washing the slides with double-distilled de-ionized water the reaction was stopped. All stained sections were dehydrated in increasing grades of concentration of ethanol, then clarified in xylene.

The numbers of AgNORs in 100 cells of each defined type were counted in all specimens under $\times 100$ oil immersion lens using Crocker *et al.* criteria (11). Closely aggregated dots were counted and recorded as separate dots. The distribution pattern of NORs was not objectively evaluated. Nonparametric analysis of variance, Tukey test, and receiver operating characteristic (ROC) curve were used for statistical analysis.

RESULTS

The patients characteristics are shown in table 1. Mean AgNORs counts were as follows: fibrous dysplasia, 0.73 ± 0.15 (Fig. 1), ossifying fibroma,

Table 1. Patient characteristics

| | Fibrous dysplasia | Ossifying fibroma | Well differentiated osteosarcoma | Poorly differentiated osteosarcoma |
|-------------------------|-------------------|-------------------|----------------------------------|------------------------------------|
| Number | 14 | 14 | 10 | 4 |
| Sex: male/ female | 9/5 | 3/11 | 6/4 | 3/1 |
| Age: median (range), yr | 16 (16-18) | 33 (26-38) | 34 (16-45) | 31 (19-38) |
| Site: maxilla/ mandible | 10/4 | 5/9 | 6/4 | 2/2 |

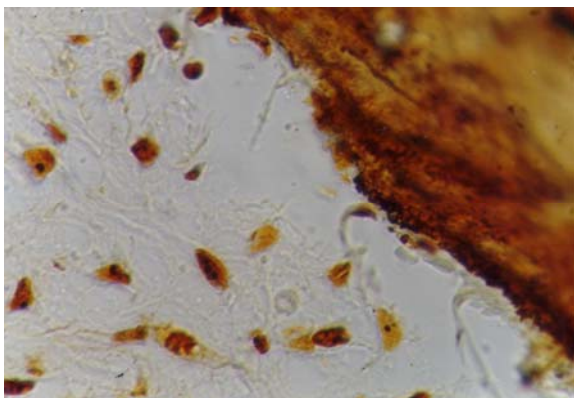


Fig. 1. The AgNOR dots in fibrous dysplasia (silver staining; $\times 1000$).

1.75 ± 0.11 (Fig. 2), well differentiated osteosarcoma, 1.90 ± 0.12 (Fig. 3) and poorly differentiated osteosarcoma, 6.54 ± 0.25 (Fig. 4).

One-way analysis of variance indicated that the mean AgNOR counts were significantly different among the 4 groups ($P < 0.001$). Post-hoc Tukey test showed that all groups differed with each others ($P < 0.01$).

The mean counts of AgNORs were < 1 for fibrous dysplasia, 1 to 2.5 for ossifying fibroma and well differentiated osteosarcoma and > 6 for poorly differentiated osteosarcoma (Table 2). On the basis of this classification, poorly differentiated osteosarcoma and fibrous dysplasia easily could be differentiated from well differentiated osteosarcoma and ossifying fibroma.

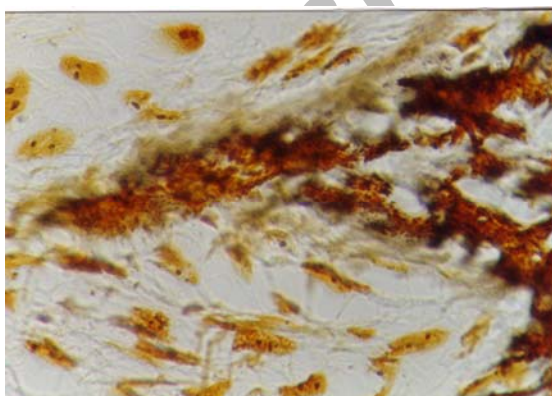


Fig. 2. The silver-stained nucleolar organizer regions (AgNOR) dots in ossifying fibroma (silver staining; $\times 1000$).

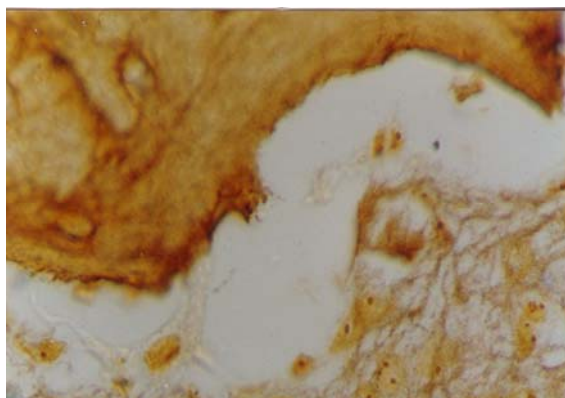


Fig. 3. The AgNOR dots in well differentiated osteosarcoma (silver staining; $\times 1000$).

If mean AgNOR count is to be meaningful as a test to distinguish between well differentiated osteosarcoma and ossifying fibroma, one must determine a cut-point for diagnosis. A ROC analysis was done and the ROC curve plotted area under the curve (AUC), potential cut points, sensitivity, specificity and their 95% confidence intervals (CI) were obtained from the ROC analysis. Every obtained mean AgNOR count was considered as a potential cut-off point. Using ROC analysis, we determined a mean AgNOR count cut-off point of 1.8 that can be used to distinguish between well differentiated osteosarcoma and ossifying fibroma (Table3). The test had a sensitivity of 90% and specificity of 64.3% with area under the curve being 84% (Fig 5).

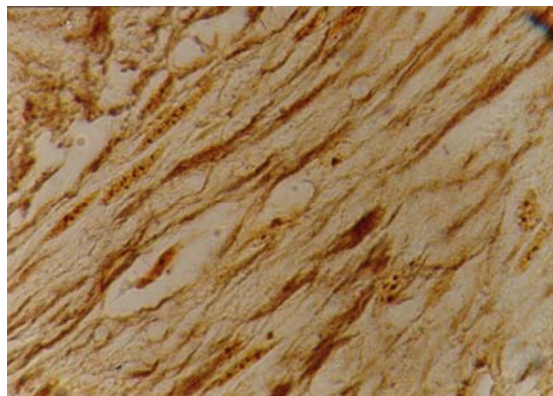


Fig. 4. The AgNOR dots in poorly differentiated osteosarcoma (silver staining; $\times 1000$).

Table 2. Distribution of the NOR count in four lesion groups

| Group | Number | Mean | SD | 95% CI | Range |
|------------------------------------|--------|------|------|-----------|-----------|
| Fibrous dysplasia | 14 | 0.73 | 0.15 | 0.65-0.82 | 0.46-0.98 |
| Ossifying fibroma | 14 | 1.75 | 0.11 | 1.69-1.81 | 1.54-1.92 |
| Well differentiated osteosarcoma | 10 | 1.90 | 0.12 | 1.98-1.82 | 1.76-2.12 |
| Poorly differentiated osteosarcoma | 4 | 6.54 | 0.25 | 6.14-6.94 | 6.22-6.81 |

Abbreviations: SD, standard deviation; CI, confidence interval.

DISCUSSION

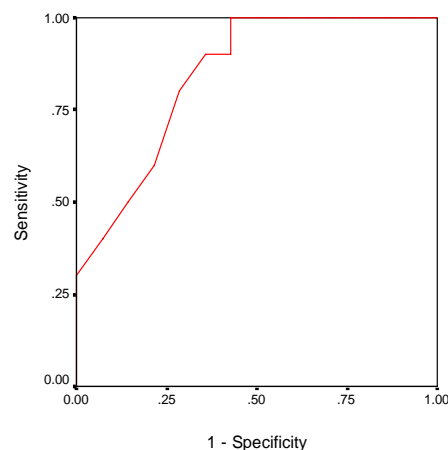
The NOR were first described as weakly staining chromatic regions around which nucleoli reorganize during telophase. These regions correspond to the secondary constrictions of metaphase chromosomes in human, *i.e.* chromosome 13, 14, 15, 21 and 22. A peculiar group of acidic proteins which have a high affinity for silver (AgNOR proteins) are also located in the NORs (12). These silver stained proteins represent a good marker for ribosomal genes both in metaphase chromosome and interphase nuclei (13). In 1986 Ploton and co-workers succeeded in visualizing interphase NORs at the light microscopic level in routine paraffin sections by applying a rapid, simple silver-staining method for the NOR proteins (14). In cells stimulated to proliferate, the quantity of interphase AgNORs progressively increases from early G₁ phase, reaches a maximum value during S phase and remains constant up to the late G₂ phase. It is not surprising to observe that proliferating tissues exhibit interphase AgNOR values greater than non-proliferating ones (15). Tumors of different origin exhibit a highly significant correlation between the interphase AgNOR quantity and cell proliferation rate evaluated by Ki-67 immunostaining and/or bromodeoxyuridine (BrdU) *in vitro* labelling (16, 17).

Table 3. Distribution of absolute and relative frequency of well differentiated osteosarcoma and ossifying fibroma lesions in the two mean groups of AgNOR counts

| | Well differentiated osteosarcoma | Ossifying fibroma |
|------------|-------------------------------------|----------------------|
| Mean group | | |
| 1.81-2.5 | 9 (90) | 5 (35.7) |
| 1-1.81 | 1 (10) | 9 (64.3) |
| Sum | 10 (100) | 14 (100) |

It appears therefore that quantification of interphase AgNOR can actually represent a useful tool for cell kinetics evaluation (18). For about a decade, there have been numerous reports suggesting the usefulness of AgNORs as replicatory markers/diagnostic aids and prognostic markers for various neoplastic lesions. It is important to note that AgNOR staining is a good and an easily performed technique (19-22).

To our knowledge, there is no published information regarding the diagnostic value of silver-stained nucleolar organizer regions (AgNOR staining) in osteosarcoma, fibrous dysplasia, and ossifying fibroma of the jaws. We investigated the mean AgNORs counts in these lesions. In the present study, the mean AgNORs counts showed significant differences between these lesions. If the mean counts of AgNORs were < 1, the lesions should be diagnosed as fibrous dysplasia and if > 6, it should be diagnosed as poorly differentiated osteosarcoma.

**Fig. 5.** ROC curve: sensitivity (%) vs. 1-specificity (%) for mean AgNOR score to distinguish between ossifying fibroma and well differentiated osteosarcoma.

The main focus of this study was to distinguish between well differentiated osteosarcoma and ossifying fibroma with a mean counts of 1 to 2.5. By considering a cut off point of 1.81-2.5 for well differentiated osteosarcoma and 1-1.8 for ossifying fibroma, well differentiated osteosarcoma can be differentiated from ossifying fibroma with a sensitivity of 90% and a specificity of 64.3. The area under the ROC curve was 0.84.

Okada and colleagues demonstrated the number of AgNOR per nucleus and MIB-I-positive rate being significantly higher in low-grade intraosseous osteosarcoma than in fibrous dysplasia in the lower limb, (Mean AgNORs counts were as follows: fibrous dysplasia, 0.6 ± 0.4 ; well differentiated osteosarcoma 1.8 ± 0.3) the mean counts of AgNORs were ≤ 1 for fibrous dysplasia and 1-2 for osteosarcoma. These findings indicate that the results of AgNOR and immunohistochemical MIB-I staining might be helpful in differentiating low-grade intraosseous osteosarcoma from fibrous dysplasia in the lower limb (23). Fibrous dysplasia is a developmental tumorlike condition, ossifying fibroma is a benign, slow-growing neoplasm of the jaws and osteosarcoma is a malignancy of mesenchymal cells (3). The analysis of interphase AgNOR distribution in a series of human cancers has demonstrated that, generally speaking, cancer cells have a greater quantity of interphase AgNOR than the corresponding hyperplastic and normal cell (13).

The findings of the current study show that AgNOR staining is a useful technique for differential diagnosis of osteosarcoma, ossifying fibroma and fibrous dysplasia in jaws when it is difficult to recognize these lesions in routine H&E staining.

REFERENCES

- Petrikowski CG, Pharoah MJ, Lee L, Grace MG. Radiographic differentiation of osteogenic sarcoma, osteomyelitis, and fibrous dysplasia of the jaws. *Oral Surg Oral Med Oral Pathol Oral Radiol Endod.* 1995 Dec; 80(6):744-750.
- Regezi JA, Sciubba JJ. *Oral pathology.* 3rd ed. Philadelphia: Saunders; 1999. p. 357-363.
- Neville BW, Damm DD. *Oral and maxillofacial pathology.* 1st ed. Philadelphia: Saunders; 1995. p. 464-470.
- Crocker J, Nar P. Nucleolar organizer regions in lymphomas. *J Pathol.* 1987 Feb; 151(2):111-118.
- Crocker J, Skilbeck N. Nucleolar organiser region associated proteins in cutaneous melanotic lesions: a quantitative study. *J Clin Pathol.* 1987 Aug; 40(8):885-889.
- Howat AJ, Giri DD, Cotton DW, Slater DN. Nucleolar organizer regions in Spitz nevi and malignant melanomas. *Cancer.* 1989 Feb 1; 63(3):474-478.
- Derenzini M, Romagnoli T, Mingazzini P, Marinozzi V. Interphasic nucleolar organizer region distribution as a diagnostic parameter to differentiate benign from malignant epithelial tumors of human intestine. *Virchows Arch B Cell Pathol Incl Mol Pathol.* 1988; 54(6):334-340.
- Crocker J, Ayres J, McGovern J. Nucleolar organiser regions in small cell carcinoma of the bronchus. *Thorax.* 1987 Dec; 42(12):972-975.
- Chattopadhyay A, Ray JG, Caplan DJ. AgNOR count as objective marker for dysplastic features in oral leukoplakia. *J Oral Pathol Med.* 2002 Oct; 31(9):512-517.
- Ofner D, Aubele M, Biesterfeld S, et al. Guidelines of AgNOR quantification: first update. *Virchows Arch* 1995; 427: 341.
- Crocker J, Boldy DA, Egan MJ. How should we count AgNORS? Proposals for a standardized approach. *J Pathol.* 1989 Jul; 158(3):185-188.
- Hernandez-Verdun D, Derenzini M. Non-nucleosomal configuration of chromatin in nucleolar organizer regions of metaphase chromosomes in situ. *Eur J Cell Biol.* 1983 Sep; 31(2):360-365.
- Crocker J. *Molecular Biology in Histopathology.* 1st ed. Indianapolis: John Wiley & Son Ltd; 1994.
- Ploton D, Menager M, Jeannesson P, Himber G, Pigeon F, Adnet JJ. Improvement in the staining and in the visualization of the argyrophilic proteins of the nucleolar organizer region at the optical level. *Histochem J.* 1986 Jan; 18(1):5-14.
- Hernandez-Verdun D, Derenzini M, Bouteille M. The morphological relationship in electron microscopy between NOR-silver proteins and intranucleolar chromatin. *Chromosoma.* 1982; 85(4):461-473.
- Trere D, Farabegoli F, Cancellieri A, Ceccarelli C, Eusebi V, Derenzini M. AgNOR area in interphase nuclei of human tumours correlates with the proliferative activity evaluated by bromodeoxyuridine labelling and Ki-67 immunostaining. *J Pathol.* 1991 Sep; 165(1):53-59.
- Dervan PA, Gilmartin LG, Loftus BM, Carney DN. Breast carcinoma kinetics. Argyrophilic nucleolar organizer region counts correlate with Ki67 scores. *Am J Clin Pathol.* 1989 Oct; 92(4):401-407.

18. Derenzini M, Ploton D. Interphase nucleolar organizer regions in cancer cells. *Int Rev Exp Pathol*. 1991; 32:149-192.
19. Sano K, Takahashi H, Fujita S, Inokuchi T, Pe MB, Okabe H, Tsuda N. Prognostic implication of silver-binding nucleolar organizer regions (AgNORs) in oral squamous cell carcinoma. *J Oral Pathol Med*. 1991 Feb; 20(2):53-56.
20. Kakeji Y, Korenaga D, Tsujitani S, Haraguchi M, Maehara Y, Sugimachi K. Predictive value of Ki-67 and argyrophilic nucleolar organizer region staining for lymph node metastasis in gastric cancer. *Cancer Res*. 1991 Jul 1; 51(13):3503-3506.
21. Ceccarelli C, Trere D, Santini D, Taffurelli M, Chieco P, Derenzini M. AgNORs in breast tumours. *Micron*. 2000 Apr; 31(2):143-149.
22. Kobayashi I, matsuo K, Ozeki S, Ohishi M, Ishibashi Y, Sakai H. The proliferative activity in oral epithelial dysplasia analyzed by proliferating cell nuclear antigen immunostaining and argyrophilic nucleolar organizer region staining. *Hum Pathol*. 1995 Aug; 26(8):907-913.
23. Okada K, Nishida J, Morita T, Kakizaki H, Ishikawa A, Hotta T. Low-grade intraosseous osteosarcoma in northern Japan: advantage of AgNOR and MIB-1 staining in differential diagnosis. *Hum Pathol*. 2000 Jun; 31(6):633-639.

Archive of SID