

# RETROGRADE DUCTUS VENOSUS ATRIO-WAVE AS A SPECIFIC PREDICTOR OF PERINATAL MORTALITY: A CASE REPORT

V. Marsoosi

Department of Perinatology, Shariati Hospital, School of Medicine, Tehran University of Medical Sciences, Tehran, Iran.

**Abstract-** As fetal compensation against hypoxemia progresses, the afterload on the heart increases, peripheral vascular resistance also increases. Eventually, the right heart fails, which is transmitted to the fetal venous system, causing decreased flow during late diastole or atrial contraction and increased resistance in the ductus venosus and inferior vena cava. The ductus has forward flow during atrial contraction, the disappearance of which is always pathologic. This is a report of a case of retrograde ductus venosus atrio-wave in a fetus referred with decreased movement for fetal assessment.

*Acta Medica Iranica*, 43(4): 306-308; 2005

**Key words:** Fetal asphyxia, ductus venosus, perinatal mortality

## INTRODUCTION

Venous Doppler provides important data about stressed fetal circulation but which venous wave form and which specific analysis provide the best information are still being investigated (1,2). Potential targets are the umbilical vein, inferior vena cava (IVC) and ductus venosus. The ductus venosus is probably the vein of choice (3).

The IVC waveform and its indices have a wide variation within normal fetuses, so the predictive value for asphyxia or even stillbirth is poor (4, 5, 6). The umbilical vein provides a very specific indication of stillbirth risk, *i.e.* few false positives for the most abnormal umbilical vein triphasic pulsation (7-10), but is so uncommon, even in sick fetuses, that its sensitivity is subclinical (1, 2). The ductus venosus provides a unique combination of advantages: it is a primary regulation of venous return in both normal and abnormal fetuses, it is a direct conduit of right

atrial retrograde pulse waves, it is responsive to changes in oxygenation, independent of cardiac function, and it is readily imaged because of its very focal high velocity color Doppler signal and characteristic audio signal from 12 to 40 weeks. Finally, although all provide a valuable correlation with fetal and neonatal morbidities, the retrograde ductus venosus atrial-wave is simplest to recognize and is the best predictor of perinatal mortality, neonatal circulatory collapse and other critical morbidities (1, 2, 11)

## CASE REPORT

A 38 weeks pregnant woman with decreased fetal movement was referred to perinatology unit at Shariati Hospital for fetal assessment. In ultrasound examination, the biometry showed an asymmetric IUGR, with oligohydramnios. Fetal tococardiography showed flat tracing without long term and short term variability and there was shallow deceleration (late deceleration) on tracing; the score of biophysical profile was 0. In Doppler assessment there was reverse end diastolic flow in umbilical artery and a retrograde a wave in ductus venosus. Cesarean section performed immediately for fetal indication.

Received: 23 Feb. 2004, Revised: 9 Oct. 2004, Accepted: 31 Oct. 2004

**\* Corresponding Author:**

V. Marsoosi, Department of Perinatology, Shariati Hospital, School of Medicine, Tehran University of Medical Sciences, Tehran, Iran  
Tel: +98 21 66112432  
Fax: +98 21 66112432  
E-mail: v\_marsoosi@sina.tums.ac.ir

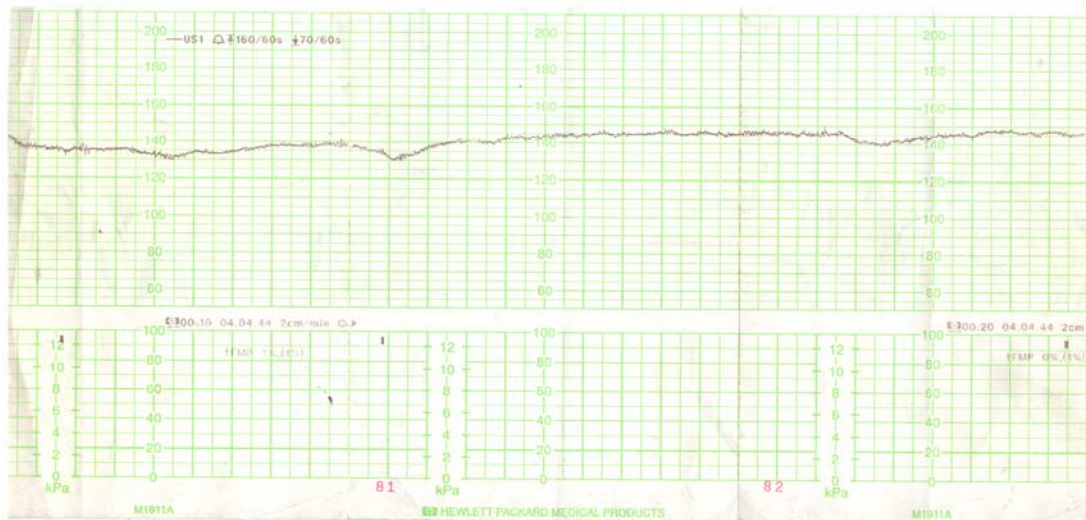


Fig. 1. Flat tracing with late deceleration

The one minute Apgar score was 2. After resuscitation five minute Apgar score raised to 8, the umbilical cord pH was 7.12 (metabolic acidosis). There was no congenital anomaly.

The neonate was hypotonic and had seizures. On the next day the neonate expired. The diagnosis was severe perinatal asphyxia.

## DISCUSSION

In the healthy near term fetus, the steeply tapered ductus venosus (wide end pointed towards the placenta) limits the amount of highest oxygenated blood to 20% of umbilical vein return (12, 13).

This relative restriction provides two distinct effects: first, it directs a large amount of venous return in to the low-mpedance hepatic parenchyma, where nutrient extraction is maximized at very little oxygen cost, less than a 15% drop across the left lobe (11,12), second, the venturi effect of its trumpet shape means that the 20% that does enter the heart most directly is a high velocity jet keeping the foramen ovale open and transmitting the optimal brain supply from right to left (11). In the fetus compromised by anemia or hypoxemia, ductus venosus has critical dual role. Its dilation and increased left lobe shunting recruit more oxygen to central distribution while minimizing preload excess (14).

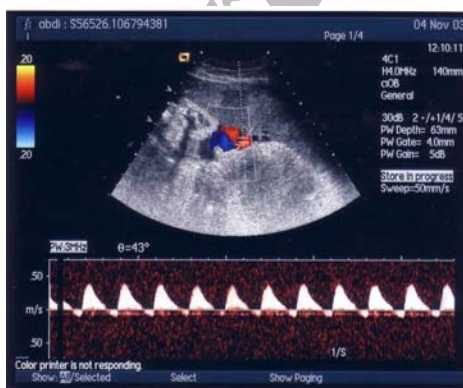


Fig. 2. Reverse end diastolic flow in the umbilical artery

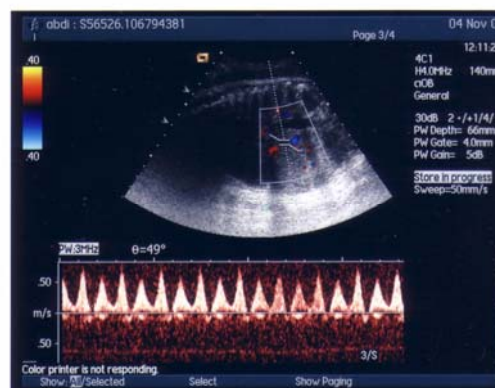


Fig. 3. Retrograde ductus venosus atrio-wave

## Retrograde ductus venosus atrio-wave

Ductus venosus wave form deterioration precedes, and strongly predicts changes in the biophysical profile score requiring delivery (15). This deterioration is complex and our understanding is just beginning (16, 17).

## REFERENCES

1. Baschat AA, Gembruch U, Weiner CP, Harman CR. Qualitative venous Doppler waveform analysis improves prediction of critical perinatal outcomes in premature growth-restricted fetuses. *Ultrasound Obstet Gynecol.* 2003 Sep; 22(3): 240-245.
  2. Harman CR, Baschat AA, Gembruch. Venous Doppler in IUGR. Which vessel? Which parameter? *Am j obstet Gynecol* 2001; 185: 53.
  3. Huisman TWA, Stewart PA, Wladimiroff JW. Flow velocity wave forms in the fetal inferior vena cava during the second half of normal pregnancy. *Ultra sound Med Biol* 1991; 17: 679-682.
  4. Reed KL, Appleton CP, Anderson CF, Shenker L, Sahn DJ. Doppler studies of vena cava flows in human fetuses. Insights into normal and abnormal cardiac physiology. *Circulation.* 1990 Feb; 81(2):498-505.
  5. Rizzo G, Arduini D, Romanini C. Inferior vena cava flow velocity waveforms in appropriate- and small-for-gestational-age fetuses. *Am J Obstet Gynecol.* 1992 Apr; 166(4):1271-1280.
  6. Rizzo, Arduini D, caforio L and co-workers. Effects of sampling sites on inferior vena cava flow velocity waveforms. *J Matern fetal Inves* 1992; 2: 153-156.
  7. Hofstaetter C, Gudmundsson S, Hansmann M. Venous Doppler velocimetry in the surveillance of severely compromised fetuses. *Ultrasound Obstet Gynecol.* 2002 Sep; 20(3):233-239.
  8. Hofstaetter C, Dubiel M, Gudmundssons. Two types of umbilical venous pulsation and outcome of high risk pregnancy. *Early Hum Dev* 2001; 61: 111-117. The degree of umbilical venous pulsations—is directly related to the severity of perinatal compromise.
  9. Baschat AA, Gembruch U. Triphasic umbilical venous blood flow with prolonged survival in severe intrauterine growth retardation: a case report. *Ultrasound Obstet Gynecol.* 1996 Sep; 8(3): 201-205.
  10. Rizzo G, Capponi A, Soregaroli M, Arduini D, Romanini C. Umbilical vein pulsations and acid-base status at cordocentesis in growth-retarded fetuses with absent end-diastolic velocity in umbilical artery. *Biol Neonate.* 1995; 68(3): 163-168.
  11. Muller T, Nanan R, Rehn M, Kristen P, Dietl J. Arterial and ductus venosus Doppler in fetuses with absent or reverse end-diastolic flow in the umbilical artery: correlation with short-term perinatal outcome. *Acta Obstet Gynecol Scand.* 2002 Sep; 81(9):860-866.
  12. Bellotti M, Pennati G, De Gasperi C, Battaglia FC, Ferrazzi E. Role of ductus venosus in distribution of umbilical blood flow in human fetuses during second half of pregnancy. *Am J Physiol Heart Circ Physiol.* 2000 Sep; 279(3):H1256-1263.
  13. Mavrides E, Moscoso G, Carvalho JS, Campbell S, Thilaganathan B. The human ductus venosus between 13 and 17 weeks of gestation: histological and morphometric studies. *Ultrasound Obstet Gynecol.* 2002 Jan; 19(1):39-46.
  14. Tchirikov M, Kertschamkas, Sturenberg HJ, Schroeder HJ. Liver blood perfusion as a possible instrument for fetal growth regulation. *Placenta* 2002; 23: 5153-5158.
  15. Baschat AA, Gembruch U, Harman CR. The sequence of changes in Doppler and biophysical parameters as severe fetal growth restriction worsens. *Ultrasound Obstet Gynecol.* 2001 Dec; 18(6):571-577.
  16. Tchirikov M, Eisermann K, Rybakowski C, Schroeder HJ. Doppler ultrasound evaluation of ductus venosus blood flow during acute hypoxemia in fetal lambs. *Ultrasound Obstet Gynecol.* 1998 Jun; 11(6):426-431.
  17. Schroeder HJ, Tchirikov M, Rybakowski C. Pressure pulses and flow velocities in central veins of the anesthetized sheep fetus. *Am J Physiol Heart Circ Physiol.* 2003 Apr; 284(4): H1205-1211.
- Different veins reflect fetal stress under different conditions. In fetuses with severe compromise of placental circulation, sudden changes in venous waveforms may be utilized to decide the need for urgent delivery.