

OUTCOME OF PROSTHETIC THIGH VASCULAR ACCESS GRAFT IN HEMODIALYSIS PATIENTS: A PROSPECTIVE SIX YEAR STUDY

J. Salimi^{1*}, A. Shojaee¹, A.P. Meisami², H. Dinparast¹ and A.Rabbani¹

1) Department of Surgery, Sina Hospital, Medical Sciences/ University of Tehran, Tehran, Iran

2) Department of Epidemiology, School of Medicine, Medical Sciences/ University of Tehran, Tehran, Iran

Abstract- Arteriovenous fistulae traditionally have been placed in the upper extremity. Experience with groin hemodialysis access has been discouraging because of high infection rates and associated limb amputation. The aim of this study was to determine infection rates, patency rates, and possible predictive factors for prosthetic thigh angioaccess outcomes in our hemodialysis patient population. A prospective study was performed for 53 patients who underwent placement of thigh vascular access graft at Sina Hospital, Tehran University of Medical Sciences, between Jan 2000 and July 2005. Demographics, complications, and subsequent treatment were recorded. Survival distributions were plotted using the Kaplan-Meier method for graft survival (primary patency). Log rank tests were used to evaluate for statistical differences in survival distribution between different groups. The primary patency rates were, 78.4%, 61.2%, 56.2%, and 50% at 3, 6, 9 and 12 months, respectively. There were 15 (28.3%) access failures, related to infection in 2 cases (3.7%), thrombosis in 10 cases (18.9%) and bleeding in 3 case (5.7%). There was no limb ischemia. No significant differences in infection rate or graft patency rates were found by patients' age and gender. A PTFE vascular access in the thigh is not associated with higher morbidity compared with the upper extremity, and should be considered as a promising alternative when upper extremity arteriovenous fistulas cannot be constructed. The incidence of infection and thrombosis in our series is comparable with rates reported in the literature for lower extremity polytetrafluoroethylene angioaccess grafts.

© 2008 Tehran University of Medical Sciences. All rights reserved.

Acta Medica Iranica, 46(1): 17-20; 2008

Key words: Hemodialysis, vascular access, lower extremity graft

INTRODUCTION

Dialysis access procedures and complications are important causes of morbidity and hospitalization for chronic hemodialysis patients. The number of complicated subjects on dialysis is increasing, and

creating a successful vascular access for these patients is a challenge (1).

Because some individuals are not candidates for native fistula, synthetic grafts were developed and have been shown to be suitable substitutes (2-4). The National Kidney Foundation Clinical guidelines on vascular access recommend preferential placement of arteriovenous fistulas (A-VF) in hemodialysis patients, with A-V grafts reserved for patients whose vascular anatomy precludes fistula placement. The rationale for this recommendation is that fistulas require substantially fewer interventions than do

Received: 8 Nov. 2005, Revised: 28 Feb. 2006, Accepted: 20 May 2006

*** Corresponding Author:**

Javad Salimi, Department of Surgery, School of Medicine, Medical Sciences/Tehran University, Tehran, Iran
Tel: +98 21 667350181
Fax: +98 21 667350181
E-mail: mjsalimi@sina.tums.ac.ir

Outcome of thigh vascular access graft in hemodialysis patients

grafts to maintain long-term patency for dialysis (5,6).

Surgeons are often tasked to provide dialysis access for patients with no sites available for access in the upper extremity, because of arterial steal syndrome or ischemic complications, severe axillary or subclavian arterial disease and venous thrombosis (2,3). Although some studies report a high rate of infection and limb amputation associated with prosthetic thigh AV access, others report favorable results, with patency and infection rates comparable to those achieved for prosthetic AV access in the upper extremity (3). With the improvements in surgical techniques and advent of polytetrafluoroethylene (PTFE) for hemodialysis access, the groin has again received attention as a valuable hemodialysis access site (2-5).

We report in a prospective study, our experience with angioaccess grafts in the groin using the reporting standards for outcome developed by the Society for Vascular Surgery and the American Association for Vascular Surgery (SVS/AAVS) to assess the safety and durability, infection rate, and patient factors that influence outcome.

MATERIALS AND METHODS

Patients and study design

The vascular surgeons at Sina Hospital, a teaching hospital of Tehran University Medical Sciences, create vascular access for approximately 500 hemodialysis patients yearly. The lower extremity was used only when no other permanent access site was available. We excluded arterial insufficiency and venous obstruction in suspicious patients by physical examination and doppler study. All information regarding placement of new thigh vascular access grafts between Jan 2000-July 2005 and subsequent graft complications was maintained prospectively in a computerized file maintained by the general surgery resident. Fifty-three thigh vascular access procedures were performed for 53 patients by the one of three vascular surgeons or by their two fellowship. Consent to review the clinical database for research purposes was obtained from Tehran University of Medical Sciences Review

Board and patients were included in the study after informed consent.

Operative Technique

A bolus of antibiotic (Vancomycin 1g, I.V.) was given before access surgery and 1 week later. Under spinal anesthesia, a 6- to 8-cm longitudinal incision, starting 2 cm below the crease of the inguinal ligament toward the knee was made. The saphenous vein and superficial femoral artery were exposed and proximal and distal control was performed. In each instance, a looped bridged PTFE graft (8mm) vascular access was created. The graft were sewn end to side to the common or superficial femoral artery with 5-0 polypropylene sutures. The arterial inflow was the common femoral artery in 13 patients and the superficial femoral artery in 40 patients. The proximal saphenous vein was used as the outflow vessel (Fig. 1). Dialysis through the grafts were began on 14-20 days postoperatively.

Statistical Analysis

Primary patency was defined as normal function from the time of placement until graft failure or development of any malfunction requiring surgical correction such as thrombosis, infection, aneurysm

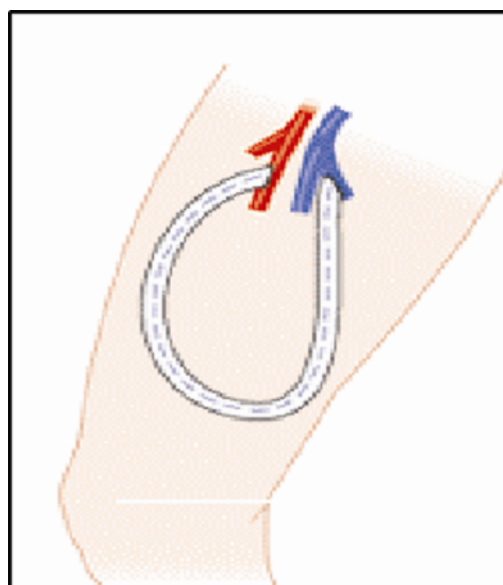


Fig. 1. Thigh vascular access graft :Proximal superficial femoral artery –saphenous vein loop graft

formation. Graft adequacy was defined prospectively as the ability to use it for hemodialysis with two needles and a blood flow of at least 350 mL/min on at least six dialysis sessions in 1 month. Survival distributions were plotted using the Kaplan-Meier method for graft survival (primary patency). Log rank tests were used to evaluate for statistical differences in survival distribution between different groups. Grafts that were functioning on last follow-up examination but were discontinued for reasons other than failure (such as transplantation or death) were censored in the life-table analysis.

RESULTS

During the study period From January 2000 to July 2005, 53 thigh AV accesses graft were performed in 53 patients, among approximately 937 access-related open surgical procedures. Thus, thigh grafts accounted for approximately 12% of all grafts placed during the study period. Postoperative follow-up from time of creation access graft to at least 12 months was available for each of the 53 grafts in the study.

The demographics of our patients were as follows: the mean patient age was 54 ± 13 years, 28.3% of the patients were age 65 or older; 47% of the patients were female. Hypertension in 19 (35.8%) cases and diabetes in 9 (17%) cases were the leading causes of ESRD. Demographic data are shown in the Table 1. There were no operative (30 day) deaths in the series; however, 13 patients died from systemic complications of their renal disease during the follow-up period for a late mortality of 25 percent. None of these deaths were directly graft-related.

Table 1. Patients demographics & Co-morbidity

| | |
|-------------------------------|-------|
| No. of patients | 53 |
| Mean age (years) | 54 |
| Sex (male: female ratio) | 28:25 |
| Cause of renal failure | |
| Hypertension | 19 |
| Diabetes | 9 |
| Hypertension & Diabetes | 6 |
| Other | 4 |
| None | 15 |

As shown in Fig 2, the primary patency rates were, 78.4%, 61.2%, 56.2% and 50% at 3, 6, 9 and 12 months, respectively. Early access failure, defined as access abandonment less than 30 days after placement. There was no early access failure in our study. Late access failure, defined as access abandonment more than 30 days after placement, occurred in 15 (28.3%) patients, and the most common event causing graft failure and thus loss of patency was thrombosis in 10(18.9%) patients. Two of 53 grafts (3.7%) had frank infection and required surgery for graft removal infection. Other causes of graft failure included bleeding form graft aneurysmal degeneration (n = 3). None episode of limb ischemia and amputation was occurred.

There were no significant differences in the incidence of thrombosis and infection between male or female patients by using Log Rank test.

DISCUSSION

Maintaining patients on dialysis for more than a decade is not unusual and the treatment of such patients may be limited primarily by the availability of vascular access (2,7). Access to the circulation has remained the Achilles' heel of most patients undergoing hemodialysis and it is the responsibility of the surgeon to create a strategy of dialysis access that maximizes the use of potential access sites.

Ideally, any patient undergoing hemodialysis should receive an autogenous fistula that could be accessed throughout the patient's life .

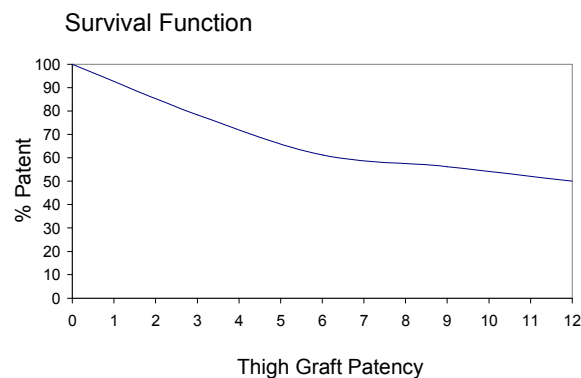


Fig. 2. Life-table analysis results for graft patency rates.

An end-to-side vein-artery anastomosis of the cephalic vein and radial artery distally in the non-dominant upper extremity is widely regarded as the favorite vascular access procedure. Successful native arteriovenous fistulas can also be performed more proximally in the upper extremity in the elbow region or in the upper arm. Unfortunately, autogenous access is often impossible because of the obliteration of important superficial veins by prior medical intervention. After exhausting the above-mentioned possibilities in the two upper extremities, we use synthetic graft in upper extremity. In patients with primarily unsuitable or secondarily surgically exhausted arm sites, a thigh fistula, either native with saphenous vein or as a bridge graft, can be performed. We have used as an alternative a polytetrafluoroethylene (PTFE) AV access graft placed in the thigh between the femoral artery and saphenous vein. Several recently published studies have reported the outcome of prosthetic thigh AV access. The conclusions of these studies differ dramatically. Some suggest that thigh AV access is safe, with excellent long-term patency, others consider it a procedure of last resort, because of the high rate of complications, such as infection and arterial steal (2-4,7,8). Khadra et al, and Tashjian et al reported the only two large series of groin grafts with which this series can be compared (2,3,8). Khadra, Dwyer, and Thompson reviewed 74 polytetrafluoroethylene loop grafts placed in 61 patients between 1985 and 1991. Twelve of 74 (16%) grafts had complications involving graft infection, with a graft salvage rate of more than 50% and no major limb amputation (8). Tashjian, Lipkowitz and Madden reported one year primary patency rate of 71% for 73 prosthetic thigh AV access placed between 1990-1998. The incidence of infection in their series was 22% (2). The incidence rate of infection for our grafts was 3.7% that is lower than Khadra and Tashjian reports that being 16% and 22% respectively. This is also lower than reports of upper extremity polytetra-fluoroethylene access infection rates that have been reported to range from 12% to 25%. Our one year primary patency rate of 50% compares with a 1-year patency rate of 50% shown by Khadra and lower than 71% in Thompson study (2,8). In conclusion, thigh AV access graft is a

viable option, it can provide prolonged, reliable dialysis access for patients who have few sites for access placement.

The incidence rate of infection is comparable with upper extremity angioaccess. If careful consideration is given to sterile technique during cannulation, infection should not be a reason to abandon the groin as a dialysis access site. Infections are usually a result of graft cannulation and not a result of surgical creation. Though not commonly considered a first choice as a dialysis access site, the groin should be considered a safe and practical option among hemodialysis patients who have exhausted all options for a permanent vascular access in the both upper extremities.

REFERENCES

1. Brescia MJ, Cimino JE, Appel K, Hurwicz BJ. Chronic hemodialysis using venipuncture and surgically created arteriovenous fistula. *N Eng J Med.* 1966; 275: 1089-1092.
2. Tashjian DB, Lipkowitz GS, Madden RL, Kaufman JL, Rhee SW, Berman J, et al. Safety and efficacy of femoral-based hemodialysis access grafts. *J Vasc Surg.* 2002; 35: 691-693.
3. Cull JD, Cull DL, Taylor SM, Carsten CG, Snyder BA, Youkey JR, et al. Prosthetic thigh arteriovenous access: Outcome with SVS/AAVS reporting standards. *J Vasc Surg.* 2004; 39: 381-386.
4. Taylor SM, Eaves GL. Results and complication of arteriovenous access dialysis grafts in the lower extremity: A five year review. *Am Surg.* 1996; 62: 188-192.
5. Miller CD, Robbin ML, Barker J, Allon M. Comparison of arteriovenous graft in the thigh and upper extremities in hemodialysis patients *J Am Soc Nephrol.* 2003; 14: 2942-2947.
6. Huber TS, Hirneise CM, Lee WA, Flynn TC, Seeger JM. Outcome after autogenous brachial-axillary translocated superficial femoropopliteal vein hemodialysis access. *J Vasc Surg.* 2004; 40: 311-318.
7. Flarup S, Hadimeri H. Arteriovenous PTFE dialysis access in the lower extremity: a new approach. *Ann Vasc Surg.* 2003; 17: 581-584.
8. Khadra MH, Dwyer AJ, Thompson JF. Advantages of polytetrafluoroethylene arteriovenous loop in the thigh for hemodialysis access. *Am J Surg.* 1997; 173: 280-283.



Archive of SID