

OROPHARYNGEAL TUBERCULOSIS: AN UNUSUAL PRESENTATION

M. H. Dadgarnia^{1*}, M. H. Baradaranfar¹, N. Yazdani² and A. Kouhi²

1) Department of Otolaryngology, School of Medicine, Yazd Shahid Sadoughi University of Medical Sciences, Yazd, Iran

2) Department of Otolaryngology, School of Medicine, Tehran, University of Medical Sciences, Tehran, Iran

Abstract- Tuberculosis (TB) still represents a major public health problem worldwide. The primary form of disease is most often localized to the lung. In a minority of patients, progressive pulmonary disease spreads to other organ systems through self inoculation via infected sputum, blood and lymphatic system, establishing the secondary form of tuberculosis. We present a patient that was referred to us with complaint of ulcerative mouth lesions from 3 months ago. In physical examination multiple erythematous and irregularly ulcerative lesions affecting soft palate area, uvula and anterior tonsillar pillar was noted bilaterally. Punch biopsy was done from several points that revealed chronic granulomatous inflammation. Ziehl-Nielsen staining of cultured specimen demonstrated acid-fast bacilli. Chest X-ray showed apical pulmonary involvement, suggesting tuberculosis infection. Patient was treated with anti-tuberculosis 4 drugs regimen. In the one year follow-up period after complete treatment; patient didn't have any evidence of disease. Oral and oropharyngeal TB lesions are uncommon, it is estimated that only 0.05-5% of total TB cases may present with oral manifestations, but should be an important consideration in the differential diagnosis of lesions that appear in the oral cavity and oropharynx. The secondary form is more frequent and involves mainly the tongue but involvement of pharynx is quite rare condition. Although tuberculosis of oropharynx is relatively rare, with the increasing incidence of tuberculosis, it must be considered in the differential diagnosis of atypical ulcerative lesions of the mouth and oropharynx.

© 2008 Tehran University of Medical Sciences. All rights reserved.

Acta Medica Iranica 2008; 46(6): 521-524.

Key words: Tuberculosis, oropharynx, oral cavity

INTRODUCTION

Tuberculosis (TB) is an infectious granulomatous disease caused mainly by mycobacterium TB, an acid-fast bacillus that is transmitted primarily via the respiratory route (1). TB still represents a major public health problem worldwide, and Iran is an endemic country for TB.

About 95% of the individuals expose to *Mycobacterium tuberculosis* remain clinically asymptomatic, while 5% develop disease. This primary form of the disease is most often localized to the lung. In most patients the infection does not spread and, as host immunity develops, the caseous foci in the lung and hilar nodes undergo healing by fibrosis and eventually calcification. In a minority of patients, progressive pulmonary disease spreads to other organ systems through self inoculation via infected sputum, blood and lymphatic system, establishing the secondary form of tuberculosis (2).

Oral and oropharyngeal TB lesions are uncommon, it is estimated that only 0.05-5% of total

Received: 31 Dec. 2007, Revised: 21 Apr. 2008, Accepted: 19 May 2008

*** Corresponding Author:**

Mohammad Hossein Dadgarnia, Shahid Sadoughi General Hospital, Department of Otolaryngology Head & Neck Surgery, Yazd, Iran.

Fax: +98 351 8224100

Phone: +98 913 3910399

Email: drdadgarnia@yahoo.com

Oropharyngeal tuberculosis

TB cases may present with oral manifestations (3). The most common site of oral and oropharyngeal TB is the tongue; however, other oral sites may also be affected (2, 3). Involvement of the oral cavity and oropharynx by TB can represent primary or, more often, secondary to pulmonary TB. The lesions of primary oral TB generally occur in younger patients (4). On the other hand, secondary lesions are most commonly seen in older individuals. Among these lesions, oropharyngeal involvement of TB is quite rare and is thought to be secondary to coughing up the infected sputum. Madhuri *et al.* reported a 40-year-old male with TB lesions involving oropharynx, nasopharynx and laryngopharynx (5).

Here we report a case of oropharyngeal TB in a 52-year-old Iranian patient affecting the soft palate, uvula and anterior tonsillar pillar.

CASE REPORT

A 52-year-old male living in Tehran was referred to the Amir-alam, outpatient otolaryngology clinic, complaining of oral ulcerative lesions from 3 months ago. Lesions were painless but halitosis and considerable weight loss in recent months was significant. He was cigarette smoker (40 pack/years) and had history of opium addiction from 30 years ago. His medical history was not significant for any serious disease.

In physical examination, multiple erythematous and irregularly ulcerative lesions affecting soft palate area, uvula and anterior tonsillar pillar was noted bilaterally (Fig 1).

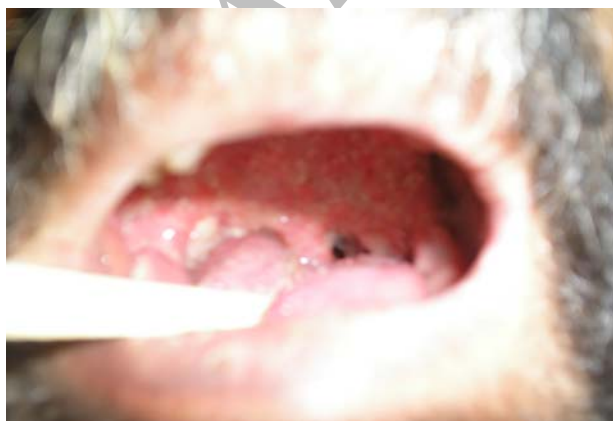

Fig 1. Oral and oropharyngeal tuberculosis.

Blood tests were within normal limits except a raised erythrocyte sedimentation rate that was 75 mm in first hour. HIV infection was ruled out with ELISA test. Sputum smear for fungi (PAS and Grocott silver) and bacteria (Gram stain) were negative. Ziehl-Nielsen staining of cultured specimen demonstrated acid-fast bacilli. Skin reaction testing for purified protein derivative (PPD) was negative, and chest X-ray showed apical pulmonary involvement, suggesting acute TB infection (Fig 2).

Punch biopsy was done from several points and was referred for pathologic evaluation that revealed chronic granulomatous inflammation consisting of numerous granuloma composed of epithelial histiocytes with scattered multinucleated Langerhans type giant cells, highly suggestive of tuberculosis (Fig 3).

Due to positive culture result and congruent histologic examination of biopsy and acute TB findings on chest X-ray, anti-tuberculosis treatment regimen was initiated. According to the protocol used, the first phase of treatment included isoniazid 300 mg, rifampin 600 mg, pyrazinamide 1500 mg and ethambutol 800 mg daily for 2 months. The second phase of treatment consisted of isoniazid 300 mg and rifampin 600 mg daily for 4 months.

One month after beginning of the first stage of treatment, the lesions showed complete resolution. In the one year follow-up period after treatment; patient didn't have any evidence of recurrence.

We obtained informed consent to publish details of the patient's history.

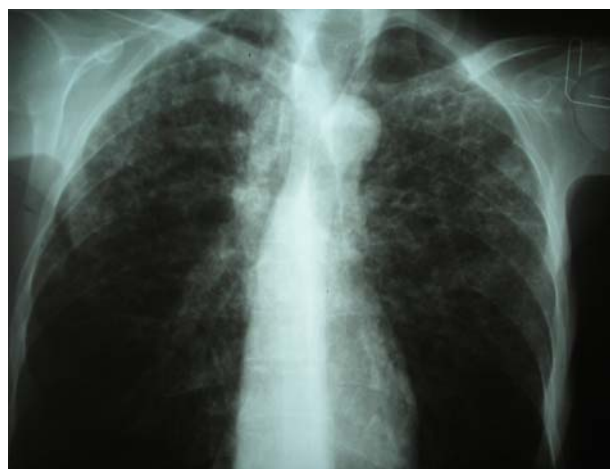

Fig. 2. Apical pulmonary involvement.

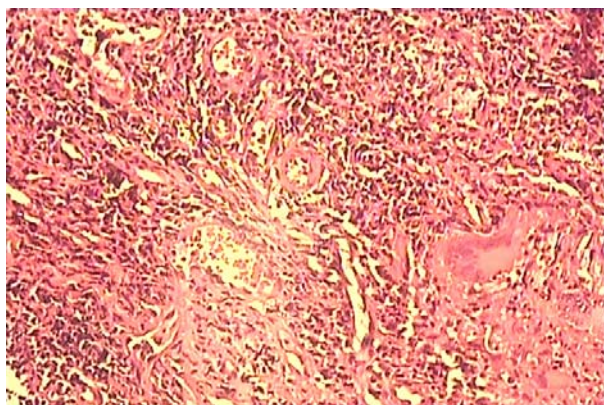


Fig. 3. Chronic granulomatous inflammation.

DISCUSSION

Oral and oropharyngeal manifestations of TB are uncommon, observed only in 0.05-5% of patients with TB, is often difficult to diagnose and it should be an important consideration in the differential diagnosis of lesions that appear in the oral cavity (3). The secondary form is more frequent in middle-aged and older persons and involves mainly the tongue (6, 7), but involvement of pharynx is quite rare condition. This may be due to inability of *M. tuberculosis* to invade the intact mucosa of oral cavity or pharynx. Cleansing action of saliva, the presence of salivary enzymes, tissue antibodies, oral saprophytes and the thickness of the protective epithelial covering have been proposed as the underlying mechanism, too. Any break or loss of these natural barriers which may be result of trauma, inflammatory conditions, tooth extraction or poor oral hygiene, may provide a route of entry for the mycobacterium (8). Oropharyngeal TB is a quite rare diagnosis and according to our knowledge in recent years there is just one case reported by Madhuri *et al.* They diagnosed and treated a 40 year old male with TB lesions involving oropharynx, nasopharynx and laryngopharynx (5).

Although the clinical picture is variable, oropharyngeal lesions typically consist of satellite ulcers with undermined edges and a granulating floor (9). The lesions may be single or multiple and painful or painless (3).

During investigation we encountered negative smear results and skin tests. For confirmation and differential diagnosis, Mantoux reaction, biopsy for histological examination, acid fast stains, and culture

should be obtained (3). Although presumptive diagnose of tuberculosis can be based on histopathological examination and identification of the bacilli in tissues using special stains because of the relative scarcity of the bacilli within tissue, mycobacteria can be demonstrated by means of special stains only in 27-60% of cases. Culture of micro organisms has shown good results, although it has technical difficulties and lack of sensitivity, may last 4-6 weeks (10). Sophisticated techniques such as PCR can be used alternatively, especially when the conventional methods of diagnose render equivocal results (11, 12).

In conclusion, although TB of oropharynx is relatively rare, with the increasing incidence of TB, it must be considered in the differential diagnosis of atypical ulcerative lesions of the month and oropharynx. This is especially important considering difficult clinical diagnosis because TB can mimic a variety of other conditions including reactive and traumatic lesions, malignant tumors, especially squamous cell carcinoma and lymphoma, deep fungal infections including paracoccidiomycosis and histoplasmosis, and oral manifestations of systemic disease such as sarcoidosis and Wegener's granulomatosis.

REFERENCES

1. Samaranayake P. Re-emergence of tuberculosis and its variants: implications for dentistry. *Int Dent J.* 2002 Oct; 52(5):330-336.
2. Neville B, Damm DD, Allen CM, Bouquot J, Neville BW. *Oral and maxillofacial pathology.* 2nd ed. Philadelphia: W. B. Saunders. P. 458-461.
3. Mignogna MD, Muzio LL, Favia G, Ruoppo E, Sammartino G, Zarrelli C, Bucci E. Oral tuberculosis: a clinical evaluation of 42 cases. *Oral Dis.* 2000 Jan; 6(1): 25-30.
4. Hashimoto Y, Tanioka H. Primary tuberculosis of the tongue: report of a case. *J Oral Maxillofac Surg.* 1989 Jul; 47(7):744-746.
5. Medhuri, Chander Mohan, Sharma ML. Posterior oropharyngeal wall tuberculosis. *Indian J of Otolaryngol and Head and Neck Surg.* 2002;54: 152-153.
6. Jawad J, El-Zuebi F. Primary lingual tuberculosis: a case report. *J Laryngol Otol.* 1996 Feb;110(2):177-178.

Oropharyngeal tuberculosis

7. Gupta A, Shinde KJ, Bhardwaj I. Primary lingual tuberculosis: a case report. *J Laryngol Otol.* 1998 Jan; 112(1):86-87.
8. Iype EM, Ramdas K, Pandey M, Jayasree K, Thomas G, Sebastian P, Nair MK. Primary tuberculosis of the tongue: report of three cases. *Br J Oral Maxillofac Surg.* 2001 Oct;39(5):402-403.
9. Von Arx DP, Husain A. Oral tuberculosis. *Br Dent J.* 2001 Apr 28;190(8):420-422.
10. Rivera H, Correa MF, Castillo-Castillo S, Nikitakis NG. Primary oral tuberculosis: a report of a case diagnosed by polymerase chain reaction. *Oral Dis.* 2003 Jan; 9(1):46-48.
11. Goel MM, Ranjan V, Dhole TN, Srivastava AN, Mehrotra A, Kushwaha MR, Jain A. Polymerase chain reaction vs. conventional diagnosis in fine needle aspirates of tuberculous lymph nodes. *Acta Cytol.* 2001 May-Jun; 45(3): 333-340.
12. Vargas PA, Villalba H, Passos AP, Saldiva PH, Mauad T, Caiaffa Filho HH, Lucena A, Almeida OP. Simultaneous occurrence of lymphoepithelial cysts, cytomegalovirus and mycobacterial infections in the intraparotid lymph nodes of a patient with AIDS. *J Oral Pathol Med.* 2001 Sep; 30(8): 507-509.

Archive of SID