

Long-Segment Aganglionosis: a 15 – year Experience

Ali Reza Mirshemirani^{1*}, Sina Sadeghian, and Jafar Kouranloo

¹ Department of Pediatric Surgery, Pediatric Surgery Research Center, Mofid Children's Hospital, School of Medicine, Shaheed Beheshti University of Medical Sciences, Tehran Iran

Received: 11 June 2007; Received in revised form: 25 Oct. 2007; Accepted: 12 Nov. 2007

Abstract- To assess the surgical progress of patients with long segment aganglionosis and long-term evaluation. During the past 15 years, we reviewed the therapy and outcome of 15 patients with Long-Segment Aganglionosis (LSA) in Mofid children's hospital. 2 with Aganglionosis to the midtransverse colon (MTA), 8 to the ascendant and cecum (A/CA), 4 with total colonic and distal ileum involvement (TCA), and one child with total intestinal Aganglionosis (TIA). The patient with TIA had only laparotomy and staged biopsies. 12 were treated by Swenson technique and 2 patients by other procedures. All patients received total parenteral nutrition up to 10 days postoperative to ensure appropriate fluid and electrolyte status. The patients with TCA needed supplementary therapies (Diet, Drugs) up to 4 months to reduce the stool frequency. 2 patients died. The patient with TIA died 6 months after Biopsies. Another one died 5 months after pull-through: small bowel ileus with total intestinal necrosis. 9 Of the 13 alive patients have normal stool pattern: 1-3 times per day. 2 patients have 3-6 stools per day with 1-2 soiling per week. An adolescent patient has occasionally nightly soiling (1- 2 per month). No actual data about one patient (A/CA). One TCA patient doing well immediately postoperative becomes obstipated 3 months later (after having Enteroocolitis). He had washout enemas for 9 months. Now stools regularly. Awareness of long-segment Aganglionosis should lead to earlier diagnosis. Appropriate surgery and improvements in supportive care led to a significantly increased rate of survival. Patients with LSA even involving ileum (but no more than 50 cm of ileum) should attain a normal stooling behavior. Long-term outcome is quite favorable.

© 2009 Tehran University of Medical Sciences. All rights reserved.

Acta Medica Iranica 2009; 47(1): 71-74.

Key words: Long-Segment Aganglionosis, total colonic aganglionosis, intestinal aganglionosis.

Introduction

The incidence of Hirschsprung's disease (HD) was found to be between 1 in 4400 (1) and 1 in 7100 (2), live births with a male/female ratio of 4.1: 1 in short segment, and 2.4:1 in long segment HD (2).

The incidence of LSD (Including total colonic Aganglionosis), in different studies, has a wide range of 5% to 20% from all HD patients (pts) (3-5). The breakthrough in the surgery of congenital megacolon occurred in 1948: Swenson and Bill identified the distal segment of the colon as a benign spastic lesion producing megacolon (6). They resected the rectum and the rectosigmoid with preservation of the sphincter and pulled through the normal colon (6). Although other procedure like Duhamel, Soave, Rehbein, (or the modification brought by boley, Martin or Kimura mostly for long-segments have been instituted to improve functional results, Swenson procedure proved to be as good as the other if the procedure is carried out correctly.

Patients and Methods

Mofid children's hospital records of 162 pts with biopsy-proven aganglionosis from 1990 to 2005 were reviewed. We found 15 pts with LSA: 2 with aganglionosis to the Midtransverse colon, 8 to the ascendant and cecum, 4 with total colonic and distal ileum (15 to 45 cm) involvement and one child with total intestinal aganglionosis (TIA) extending to the duodenum (Figure 1,2) all but the last had pull-through procedure, and the pt with TIA had only laparotomy and staged biopsies.

There were 11 boys and 4 girls. All pts with TCA and the pt with TIA were boys.

10 pts were primarily operated (all TCA included) and the other 5 were reoperated in our hospital.

From primarily operated pts, 6 were under one year of age, the other 3 pts were 2,3 and 5 years old at the time of pull-through. The PT with TIA had no pull-through operation but laparotomy and staged biopsies.

Corresponding Author: Ali Reza Mirshemirani

Department of Pediatric Surgery, Pediatric Surgery Research Center, Mofid Children's Hospital, School of Medicine, Shaheed Beheshti University of Medical Sciences, Tehran Iran

Tel: +98 21 22908181, Fax: +98 21 22908181, E-mail:almirshemirani@yahoo.com

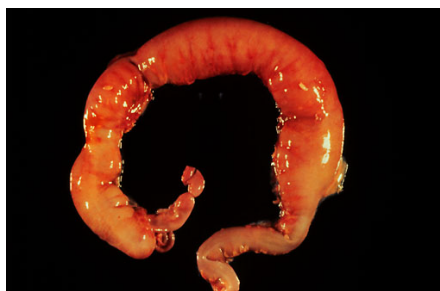

Figure 1. Patient with total colon Agangelionosis

Preoperative 5 pts had enterocolitis and 3 pts had ileus. The five reoperated pts were: one under one year, one 3, one 5 and two 7 years old. All these pts had the primary pull-through when they were younger than one year. primary procedures used in these last 5 cases were Rehbein (N=3), Duhamel (N=1) and laparoscopic Swenson (N=1). The 3 pts formerly operated by Rehbein technique presented with aganglionosis rectum 6 to 10 cm proximal to dentate line. The pt operated by Duhamel technique had a 7 cm aganglionic rectum pouch with colorectal anastomosis 3 cm proximal to dentate line. The laparoscopic pull-through (MTA- PT) was complicated by anastomosis fistula with pelvic abscess and totally stricture of the anastomosis. Also in this case was found an aganglionic distal segment 20 cm long.

Before pull-through, 5 primarily treated pts (3 with TCA) had ileostomies and the resection of aganglionic bowel as a first operation followed by pull-through 2 to 6 months later. Also 2 from 5 reoperated pts had colostomies before pull-through. The following pull-through procedures were achieved: Swenson in 12 pts, Duhamel in one and a combined approach (laparotomy and posterossagittal) in one. The last procedure was achieved in the PT with primary laparoscopic pull-through. The reason for posterossagittal approach was the cicatricial tissue in the pelvis after abscess by anastomosis fistula.

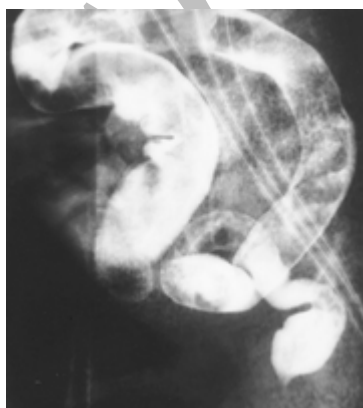


Figure 2. Barium enema of patient with total colon Agangelionosis.

Regarding only the TCA pts, 3 of them were treated by Swenson (total colectomy with ileum-rectum end-to-end anastomosis) and one by Duhamel.

The leaving rectum segment in these pts was 1 to 4 cm long.

Postoperative management consisted of total parental nutrition 5 to 10 days, followed by gradual introduction of oral feeding beginning with a low-osmolarity low-residue diet.

Three TCA pts needed loperamide, and 2 of them washouts with saline for 3 and 6 months respectively.

Results

The pts were followed-up 6 months to 15 years postoperatively. There has been no operative-related mortality in these series. Two pts died: the pt with TIA died 6 months after biopsies, and another pt died 5 months after pull-through by small-bowel ileus with total intestinal necrosis. There were two major and 8 minor complications in 15 surviving pts. The major complications occurred both after a secondary pull-through. They consisted in an anastomosis fistula 3 weeks postoperative needing a temporary ileostomy and a volvulus developed 3 years postoperative needing surgery.

As minor complications were registered subileus in one pt with spontaneous resolution, enterocolitis (one to three episodes) in 4 pts (2 TCA pts) and postoperative perineal skin irritation in 3 pts up to 1 year postoperative. Nine of 13 alive pts have normal stool pattern: 1-3 time per day. Two pts have 3-6 stools per day with 1-2 soiling per week. An adolescent pt has occasionally night soiling (1-2 per month).

There are no actual data about one pt (A/CAPT).

The pts with TCA needed supplementary therapies (diet, drugs) up to 4 months to reduce the stool frequency. One TCA pt doing well immediately postoperative becomes obstipated 3 months later, after having enterocolitis. Thereafter he needed washout enemas for 6 months. Now he stools regularly (3time/ day), and has no symptoms.

The levels of serum iron, serum ferritin, folic acid, and B12 vitamin were determine in all TCA pts. Two of them needed iron, B12 vitamin and folic acid supplementation up to 1 year postoperative. The ferritin level was normal in all pts.

Discussion

The major advance that have occurred in the management of hirschsprung's disease include the definitive

management of the newborn, our understanding of hirschsprung's-associated enterocolitis and the treatment of this entity, and the successful management of the very complex form of this disease, total colonic aganglionosis (7).

The most common surgical techniques used in hirschsprung's disease are Swenson (introduced in 1948), Duhamel (introduced in 1956), Soave (introduced in 1963), the modification of the last one (Boley 1968), and recently transanal pull-through.

In total colonic Aganglionosis these operations have been performed without or with modifications: most known are martin modification of Duhamel procedure, and Kimura procedure. Both of them preserve a part of the aganglionic colon aiming water resorbtion leading to the formed stools.

There is no agreement about the need to preserve⁸⁻¹⁰ or not¹¹⁻¹⁴ a patch of aganglionic colon in TCA pts.

In our opinion there are some arguments against preservation of the aganglionic patch: the aganglionic patch Alternate the motility with subsequent stasis and obstruction, and postoperative enterocolitis seems to be a frequent occurrence in pts having a Patch of aganglionic Bowel.

There are four mainly causes leading to failure in surgical therapy of hirschsprung's disease:

- Incomplete resection of aganglionic segment.
- Ischemia of pull-through segment.
- Associated intestinal neuronal dysplasia.
- Postoperative enterocolitis.

In four of reoperated pts we found a high made anastomosis, more tan 4 cm above the dentate live.

Ischemia may have a pathogenetic role in some cases of the acquired hirschsprung's diseases.

Vascular compromise of the distal bowel segment at the time of the initial pull-through procedure may contribute to the selective loss of ganglion cells postoperatively because neural tissues are most sensitive to hypoxia.

This finding must be considered when recurrent obstructive symptoms develop following pull-through for aganglionosis (15).

The pts developing recurrent symptoms of hirschsprung's disease, after adequate surgical correction, have to be fully studied with sequential biopsies in order to gain a better understanding of their condition (16).

The 5th reoperated pt (status post laparoscopic pull-through) had the anastomosis 1 cm above the dentate line.

The proximal end of the resected colon at first operation was normal in histological examination.by redo

operation a 20 cm aganglionic colon was found, very probably due to intraoperative ischemia. The key of success in the therapy of hirschsprung's disease is to pull-through a healthy bowel doing the anastomosis down within 1- 2 cm to the dentate line.

The TCA pts we preserved a little more from aganglionic rectum (2 to 3 cm). Even in this situation the pts developed diarrhea, needing diet and loperamide up to 4 months postoperative. One of 4 TCA pts becomes obstipated 3 months postoperatively, after having enterocolitis (17).

He had washout enemas for 6 months. However the long term results are good, showing us preservation of 2-3 cm of rectum in TCA- pts obviates the need to use an aganglionic colonic patch.

The major postoperative complications occurred both in the pts having a second pull-through operation: anastomotic fistula leading to ileostomy (1pt) and volvulus needing surgery (1pt).

Two of these 5 pts hav soiling 1-2 time per week.

All reoperated pts had aganglionic segments.

We did not find skip aganglionic area (18) in these children. In conclusion, awareness of long – segment aganglionosis should lead to earlier diagnosis. Appropriate surgery and improvements in supportive care led to a significantly increased rate of survival.

Regularly followed up, early recognition and aggressive therapy of enterocolitis lead to good outcomes.

Patients with long segment aganglionosis even involving a part of ileum, should attain a normal stooling behavior. Long-term outcome is quite favorable.

Acknowledgement

The authors thank Mrs. P.Pourang and M.Saeedi for kind help and preparation of this manuscript.

References

1. Spouge D,Baird PA. Hirschsprung disease in a large birth cohort. *Teratology*. 1985 Oct; 32(2):171-7.
2. Russell MB,Russell CA, Niebuhr E. An epidemiological study of hirschsprung's disease and additional anomalies. *Acta Paediatr*. 1994 Jan; 83(1):68-71.
3. Sherman JO, Snyder ME, Weitzman JJ, Jona JZ, Gillis DA O'Donnell B Carcassonne M, Swanson O. A40-Year multinational retrospective study of 880 swenson procedure. *J Pediatr Surg*. 1989 Aug; 24(8):833-8.
4. Foster P, Cowan G, Wrenn EL Jr Twenty Five year's experience with hirschsprung's disease. *J Pediatr Surg*. 1990 May; 25 (5); 5314.

Long-segment aganglionosis

5. Klein MD, Philippart AI. Hirschsprung's disease: three decades' experience at a single institution. *J Pediatr Surg* 1993 Oct; 28(10):1291-3 discussion 1293-4.
6. Swanson o, Bill A. Resection of rectum and rectosigmoid with preservation of sphincter for benign spastic lesion producing megacolon: experimental study. *Surgery* 1948; 24:212.
7. Coran AG, Teitelbaum DH. Recent advances in the management of Hirschsprung's disease. *AM J Surg* 2000 Nov; 180(5):382-7.
8. Shermeta DW, Meller JL. Ideal Treatment for total colonic Hirschsprung's disease. *J Pediatr Surg* 1989 Jan; 24(1):88-91.
9. Emslie, Krishnamorthy, M, Applebaum H. Long-term follow-up of patients treated with ileorectal pull through and right colon onlay patch for total colonic aganglionosis. *J Pediatr Surg* 1997 Nov; 32(11): 1542-4.
10. Nishijima E, Kimura K, Tsugawa C, Muraji T. The colon patch graft procedure for extensive aganglionosis Long-term follow-up, *J Pediatr. Surg* 1998 Feb; 33(2):215-9.
11. Bergmeijer JH, Tibboel D, Molenaar JC. Total colectomy and ileorectal anastomosis in the treatment of total colon aganglionosis: a long-term followed up study of six patients. *J. pediatr. Surg* 1989 Mar; 24(3):282-5.
12. Tsuji H, Spitz L, KLEFLY EM, Drake DP, Pierro A. Management and long term followed up of infants with total colonic aganglionosis. *J Pediatr Surg* 1999 Jan; 34(1):158-61.
13. Dodero P, Magtto P, Scarsi PL. Total colectomy and Straight ileo-anal soave endorectal pull through: personal experience with 42 cases. *Eur J Pediatr Surg* 2001 Oct; 11(5):319-23.
14. Rinatal RJ, Lindahl HG. Proctocolectomy and J – pouch ileo – anal anastomosis in children *J Pediatr Surg* 2002 Jan; 37(1):66-70
15. West KW, Grosfeld JL, Rescorla FJ, Vane DW. Acquired aganglionosis: a rare occurrence following pull-through procedures for Hirschsprung's disease. *J Pediatr Surg* 1990 Jan; 25(1):104-8.
16. Cohen MC, Moor SW, Neveling U, Kaschula RO. Acquired aganglionosis following surgery for Hirschsprung's disease: a report of 5 cases during a 33 year experience with pull through procedures *Histopathology*. 1993 Feb; 22(2):163-8.
17. Wild Hrber BE, Teitelbaum DH, Corn AG. Total Colonic Hirschsprung's disease: A 28 year experience, *J Ped Surgery* 2005; 40:203-207.
18. Berger S, Linke F, Heymanns M, Boor R, Coertdt W, Hofmann-v, Kap-herr S. Complex long-Segment intestinal dysganglionosis. *J Pediatr Surg* 2000 Jul; 35(7):1123-6.

Archive of SID