

A Case Report of Jessner's Lymphocytic Infiltrate Induced by Exposure to Computer Monitor

Omid Aminian^{1*}, Parvin Mansoori², Mohammad Reza Iraniha¹, and Ehsan Rafeemanesh¹

¹ Department of Occupational Medicine, School of Medicine, Tehran University of Medical Sciences, Tehran, Iran

² Department of Dermatology, Imam Khomeini Hospital, School of Medicine, Tehran University of Medical Sciences, Tehran, Iran

Received: 14 Mar. 2007; Received in revised form: 9 Dec. 2008 ; Accepted: 14 Jan. 2008

Abstract- Lymphocytic infiltration of Jessner-Kanof is a chronic, benign T cell infiltration disorder of exposed skin with unknown etiology. In some instances, these lesions are induced or aggravated by light exposure. In this case report, we are going to describe an interesting occupationally related skin disease, Jessner's disease, after several years working with computer. On the basis of literature review, a similar case regarding to association between Jessner's syndrome and exposure to computer monitor has not yet been describe. Interpreting our case regarding to previous reports about induction or aggravation of Jessner's disease by light exposure, we can conclude that there may be an association between exposure to radiation reflection from computer monitor and in this facial skin problem, as when patient was away from work her condition got better and when she came back, her condition got worse.

© 2009 Tehran University of Medical Sciences. All rights reserved.

Acta Medica Iranica 2009; 47(4): 339-340.

Key words: Jessner, lymphocytic infiltration, computer operator

Introduction

Lymphocytic infiltration of Jessner-Kanof is a chronic, benign T cell infiltration disorder of exposed skin with unknown etiology. In some instances, these lesions are induced or aggravated by light exposure (1, 2). Benign lymphocytic infiltration of jessner is characterized by the presence of red, tumid nodules, usually on facial skin (2). The most common location of the lesions is the face but in some instances, the neck or upper trunk is involved either alone or in addition of the face. After having persisted for several months or even several years, the lesion usually disappear without sequelae, but they may recur either at the previous site or elsewhere (3).

Case Report

A 43 years old woman from Tehran was presented with asymptomatic, nonscaling, erythematous plaques on her nose and around her eyes (Figure 1). She suffered from this problem since 1996 after six year sorking as a computer operator (8 hours per day, 40 hours per week). She did not have any history of skin or other systemic diseases. Her lesion was aggravated when she was exposed to computer monitor and was remitted when she was

away from work or when she was on vacation.

In physical examination, we could not find any other lesion on her skin. Also, she had not any similar lesions or specific skin problems in her first-degree family.

During these years, her lesion had a remission and exacerbation behavior, but continuously existed. Primary diagnosis for her lesion was DLE. During workup, lab reports were negative for LE cells, ANA, anti DNA antibody. Also direct immunofluorescence test was negative. All other lab tests such as VDRL, Latex, CRP, T3, T4, TSH, CBC, ESR, Creatinine, BUN, FBS, Cholesterol, Triglyceride, LH, FSH, Na, K, Ca, SGOT, SGPT, ALP, C3, C4 and CH50 were in normal range.

At last, skin biopsy was done and pathological report is as follows:

The sections of skin biopsy show no significant change of epidermis except that slight atrophy, flattened rete ridges and occasionally spotty vascular changes of basal cell of the epidermis. There is circumscribed aggregation of lymphocytes mostly around the vessels and appendageal structures of the papillary and reticular dermis. The lymphocytic infiltration extends between collagen fibers deep into the dermis. This report was compatible with pathological characteristic of lymphocytic infiltration of jessner.

*Corresponding Author: Omid Aminian

Department of Occupational Medicine, School of Medicine, Tehran University of Medical Sciences, Tehran, Iran
Tel: +98 21 66405588, Fax: +98 66405588, E-mail: oaminian @Sina.tums.ac.ir

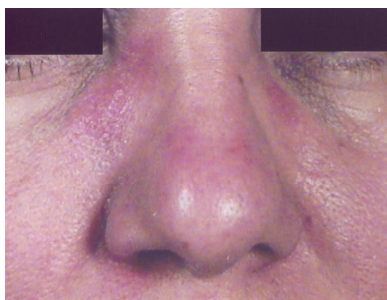


Figure 1. Lymphocytic infiltration of jessner-kanof

Discussion

In 1953, Jessner and Kanof reported on group of patients under the title "lymphocytic infiltration of the skin" which focused on the main histologic feature (1). Benign lymphocytic infiltration of jessner is characterized by the presence of red, tumid nodule, usually on the facial skin. The lesions may involve spontaneously, but more commonly are persisted and new lesions developed over times. There is variation in seasonal activity of the lesions. With winter exacerbation. The individual lesions are smooth, raised, non scaling erythematous nodules or plaques and are commonly asymptomatic, although some patients will complain of burning or pruritus. Biopsy will reveal a lymphocytic infiltrate predominantly in the lower dermis and contracted around blood vessels (2). The most common location of the lesions is the face but in some instances, the neck or upper trunk is involved either alone or in addition of the face. After having persisted for several months or even several years, the lesions usually disappear without sequels, but they may be recurring either at the previous site or elsewhere. Four other diseases with a patchy dermal infiltrate are discoid lupus erythematosus, the plaque type of polymorphous light eruption, lymphocytoma cutis and lymphocytic lymphoma (which together from the "five Ls" and these must be differentiated from Jessner's disease (3). In some instances, these lesions are induced or aggravated by light exposure leading some authors to conclude that this disorder is related to polymorphism light eruption or lupus erythematosus (4). To our knowledge, this is a first report regarding to association between lymphocytic infiltration of jessner and exposure to computer monitor. About 20% of the patients notice aggravation of their skin lesions during periods of emotional stress. In 80% of the patients, the age at the onset of the disease is between 20 and 50 years with a peak incidence in the fourth decade. The disease tends to occur in the female patients at an earlier age than in male patients. In patients younger than 20, only females have been affected. There are reports of both male and female predominance (5,6). There are some reports of familial occurrence of this disorder (7). It has been proved (or

demonstrated) that Jessner's lymphocytic infiltrate is a T-cell lymphoinfiltrative disorder, but a few B cells can be presented (8). The pathogenesis and etiology of Jessner's syndrome is still unknown. A role for plasmacytoid monocytes in this accumulation of lymphocytes in the skin have been proposed (9). Treatment is unsatisfactory and lesions tend both to persist and to increase in numbers. There are individual case reports of successful therapy with topical steroids, systemic steroids, PUVA, radiotherapy, dapsone, hydroxychloroquine and gold (10). All patients should be advised to follow sun protection measures regardless of their history of photo aggravation. In this patient, with changing the job and did not expose to computer monitor anymore, her lesions subsides and did not flare up again.

Acknowledgements

This study has been supported by Tehran University of Medical Sciences (TUMS). Authors wish to express their gratitude to members and staff of occupational medicine department for their kind collaboration.

References

1. Jessner M, Kanof NB. Lymphocytic infiltration of the skin. *Arch Dermatol* 1953; (68): 447-49.
2. Burns A, Breathnach, S, Cox N, Griffiths C, editors. *Rook's Textbook of Dermatology*. 7th ed. Oxford: Blackwell Science; 2004.
3. Elder DE, Elenitsas R, Johnson BL Jr, Murphy GF, editors. *Lever's Histopathology of the Skin*. 9th ed. Philadelphia, PA: Lippincott Williams & Wilkins; 2004.
4. Gottlieb B, Winkelmann RK. Lymphocytic infiltration of the skin. *Arch Dermatol* 1962; 86: 626-33.
5. Moschella SL, Hurley HJ, editors. *Dermatology*. 3rd ed. Philadelphia: WB Saunders; 1992.
6. Arndt KA, LeBoit PE, Robinson JK, Wintrobe BU, editors. *Cutaneous Medicine and Surgery: An Integrated Program in Dermatology*. Philadelphia: WB Saunders; 1996.
7. Toonstra I, van der Putte SC, de la Faille HB, van Vloten WA. Familial Jessner's lymphocytic infiltration of the skin, occurring in a father and daughter. *Clin Exp Dermatol* 1993; 18(2): 142-5.
8. Willemze R, Dijkstra A, Meijer CJ. Lymphocytic infiltration of the skin (Jessner): a T-cell lymphoproliferative disease. *Br J Dermatol* 1984; 110(5): 523-9.
9. Facchetti F, Boden G, De Wolf-Peeters C, Vandaele R, Degreiff H, Desmet VJ. Plasmacytoid monocytes in Jessner's lymphocytic infiltration of the skin. *Am J Dermatopathol* 1990; 12(4): 363-9.
10. Farrell AM, McGregor JM, Staughton RC, Bunker CB. Jessner's lymphocytic infiltrate treated with auranofin. *Clin Exp Dermatol* 1999; 24(6): 500.

Archive of SID

***Corresponding Author:** Omid Aminian

Department of Occupational Medicine, School of Medicine, Tehran University of Medical Sciences, Tehran, Iran
Tel: +98 21 66405588, Fax: +98 66405588, E-mail: oaminian @Sina.tums.ac.ir