

Autopsy Findings of Brainstem in Head Trauma in Comparison with CT Scan Findings in Brain Trauma Ward in Tabriz, Iran

Bahram Samadi Rad^{1*}, Ali Zeinali², Moslem Shakeri Bavi², Fereydu Ashrafi³, and Mohammad Ali Daghighi²

¹ Department of Iranian Legal Medicine Organization, Tabriz, Iran

² Department of Neurosurgery, Imam Khomeini Hospital, School of Medicine, Tabriz University of Medical Sciences, Tabriz, Iran

³ General Practitioner, East Azerbaijan Legal Medicine Center, Tabriz, Iran

Received: 14 Nov. 2007; Received in revised form: 27 Dec. 2007; Accepted: 1 Jul. 2008

Abstract- Computed tomography (CT) is now the primary diagnostic method for head trauma because of its ability to demonstrate the nature, extent, sites, and multiplicity of brain injuries. Although there have been numerous reports on the CT findings of most types of intracranial injury, the findings in brainstem injury have not been well described. This study aimed at comparing the autopsy findings of brainstem in head trauma in comparison with CT scan results. Two hundred patients with head trauma, who expired after a period of time of hospitalization, were assessed in a diagnostic value study. Brain stem involvement was determined by autopsy as well as CT scanning of the brain during their hospitalization. The results of the two methods were compared with each other, emphasizing on the type and location of probable lesions in the brain stem. Considering the autopsy as the method of the choice, sensitivity, specificity, positive predictive value (PPV) and negative predictive value (NPV) of CT scan in brain stem lesions of patients with head trauma were calculated. The effect of primary cause of head trauma, survival time and Glasgow Coma Scale (GCS) were evaluated, as well. Brain stem lesions were detected in 39 (19.5%) patients in autopsy. However, CT scan revealed brain stem lesions in 23 (11.5%) cases. The sensitivity, specificity, PPV and NPV of CT scan was 59%, 100%, 100% and 91% respectively. The most common lesions of the brain stem region were as contusion of pons (8.5%), medulla (5%) and midbrain (4.5%). There were 6 (3%) cases of ponto-medullary junction tearing and 1 (0.5%) case of cervico-medullary junction tearing. CT scan is a specific method of evaluating patients with probable brain stem injuries after head trauma, but low sensitivity limits its efficacy. Our results are in conformity with the reports in the literature.

© 2009 Tehran University of Medical Sciences. All rights reserved.

Acta Medica Iranica 2009; 47(5): 409-414.

Key words: Head trauma, brain stem injury, CT scan, autopsy

Introduction

Today, alongside with cardiac diseases and cancer, trauma is one of the leading causes of mortality in the societies, and ranks first as the cause of mortality in patients under 30 year old in our society. In head traumas especially in severe forms, brain contusion is one of the intracranial lesions which occur due to the extravasation of blood and inflammation of the involved area. Intermediary contusions are solitary or multiple lesions which can be found in the deepest structures of the brain such as corpus callosum, basal ganglions, hypothalamus and brain stem (1-7). Contusion or laceration may cause focal neurologic deficit according to the affected area. The underlying mechanism of contusion is due to translational acceleration and contact force (8,26,27). The

diagnosis of brain stem injury on computed tomography (CT) scanning is based on direct and indirect documents. CT scanning beside neurological examination is an appropriate method to define the site and the extent of brain stem injury. Regarding that CT Scan is not per se sufficient to detect the lesions of posterior fossa and when there is no satisfying reason for the death of traumatic patients, contusion of brain stem is regarded as a probable diagnosis and regarding that there is no precise statistics about the comparison of the prevalence of brain stem contusion in autopsy with CT scan finding in patients died due to head trauma in reference books (9-11).

The main goal of this study is analysis of autopsy findings of brain trauma and comparing them with CT scan findings in same cases.

*Corresponding Author: Bahram Samadi-Rad

Department of Iranian Legal Medicine Organization, Vali-Asr ave. East Azerbaijan province, Tabriz, Iran
Tel: +98 914 4110524, Fax: +984112218138, E-mail: dr_samadirad@msn.com

Suggesting better imaging techniques to detect these lesions and better understanding of the relationship between these lesions and the primary condition of the patients can be helpful in deciding how to treat these patients (1,21-25).

Patients and Methods

We studied 200 patients died with Brain trauma. The mean age of the patients was 39.1 ± 21.2 years. Regarding gender, 165 out of 200 patients were male and the rest 35 of them were female. A multi slice-Balance CT scan made by Siemens Company of Germany was used in this study. Brain CT scanning was performed without contrast with standard 10mm cuts for supra tentorium parts and 5mm cuts for infratentorial parts (posterior fossa). We also took control CT-scan regarding clinical courses and in case of clinical status change. The positive findings of CT scan included contusion and focal hemorrhage.

Autopsy method

Coronial skin cuts were made on parietal region and the doom of calvarias was separated with an axial cut. The whole brain was taken out from calvarium and the brain stem was analyzed. The brain stem was cut in eight levels according to anatomical standards: two cuts in midbrain (superior and inferior calculus), two cuts in Pons (trigeminal complex and facial calculus), and four cuts in medulla (in superior end pontomedullary Junction), in inferior end of fourth vertical and superior to pyramidal levels and inferior end (cervicomedullary junction).

In order not to miss the lesions and ruptured areas we made a sagittal cut, so that all possible lesions at brain stem were demonstrates.

Primarily all admitted patients with head trauma in the head trauma ward of Tabriz Imam Khomeini hospital underwent CT-Scan imaging and then those who died with head trauma underwent brain stem autopsy in autopsy hall of Forensic Medicine Center of Tabriz, city of Iran, during 16 month from November of 2005 to June

of 2007. To prevent biases the report of CT-Scan was reported by attending professor, and autopsies were performed under supervision of forensic medicine specialist.

The results were finally compared regarding the lesions of brain stem in autopsy and CT-Scan.

Below are our key assumptions to design this study:

1- The prevalence of brain stem injuries according to CT-Scan of patients who died with head trauma is different with its prevalence which is based on autopsy findings.

2- The prevalence of brain stem injuries in different parts of brain stem are different.

3- There is no relationship between autopsy findings of brain stem and the primary consciousness level and clinical course of patients.

Ethical issues

According to ethical committee of Tehran University of Medical Sciences protocols for all patients being dissected we took consent from first degree relatives after the explanation of the methods and the goals of the study.

Statistical analysis

Data are presented as mean \pm SD, prevalence and percentage. SPSS software program version 13 (Chicago, IL, USA) was used for data analysis.

The quantitative variables were compared using student *t*-test or one-way analysis of variances (ANOVA).

The quantitative variables were compared by contingency tables and using chi-square test or Fisher's exact test according to the conditions. For all contents of the study $P \leq 0.05$ was considered significant.

Results

Seventy-six patients were motorbike riders, 51 were automobile drivers or accompanying people, 34 were pedestrians, 28 got head trauma due to falling from high altitude, 7 were bike riders and 4 were attacked on head while struggling (Figure 1)

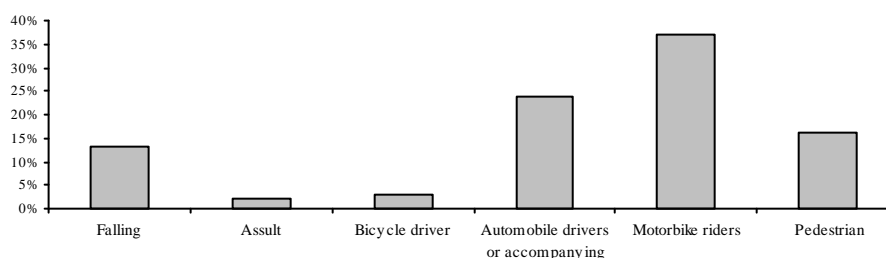


Figure 1. Prevalence of cause of head trauma in group under study

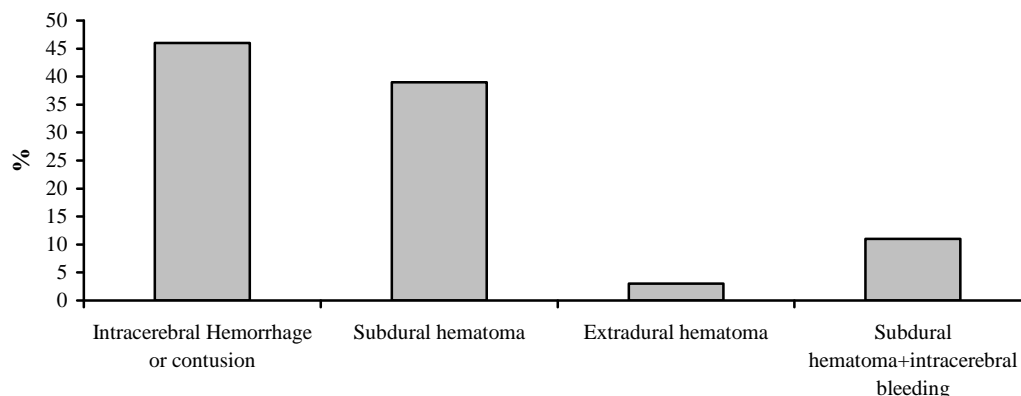


Figure 2. Prevalence of Intracranial lesions

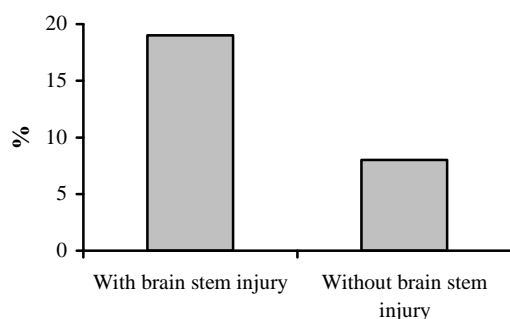


Figure 3. Percentage of Brainstem injury founded in Autopsy

Sixty-four patients had intracerebral hemorrhage or contusion, 55 had subdural hematoma, 15 had intracranial hemorrhage with subdural hemorrhage, and 5 had epidural hematoma. We couldn't make a diagnosis in 61 patients (Figure 2).

Brain stem injury was found in autopsy at 39 patients and we didn't find any injury in 161 patients (Figure 3).

Type of brain stem injuries: 17 patients had pontin contusion, 10 had medullary contusion, 9 had midbrain contusion, 6 had ponto medullary junction tearing and 1 of them had cervicomedullary junction tearing (Figure 4). In 33 (89.7%) patients we found solitary lesion of the brain stem and in 4 (10.3%) we found two lesions of brain stem.

We found positive CT reports of brain stem in 23 patients (Figure 5). Regarding the severity of primary trauma, 3 (1.5%) patients had mild head trauma, 28 (14%) had moderate and 169 (89.5%) had severe trauma.

Regarding the accordance of CT finding with autopsy findings, In 184 cases, complete accordance were found between these two methods. However, there was no accordance at the rest of the cases (16) (8%).

The results indicate that the prevalence of brain stem injuries in CT-Scan of patients who died with head trauma is different compared to that of autopsy findings. As shown in figures 3, 4 and 5, autopsy in comparing with CT-Scan has stronger diagnostic potency and comparison of two methods with chi-square test shows that there is meaningful difference among these two methods

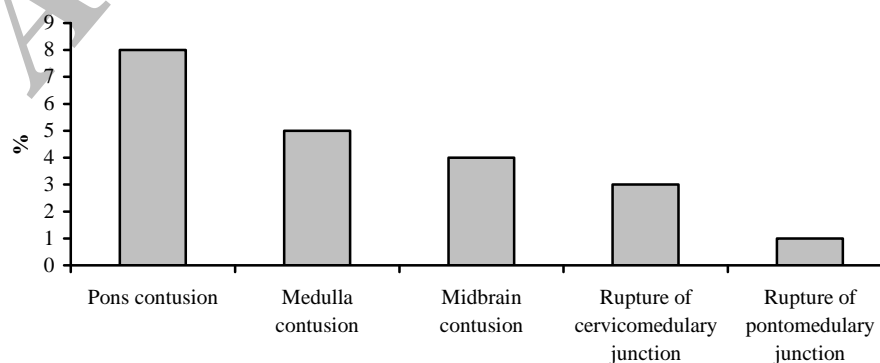


Figure 4. Prevalence of types of Brainstem injury in Autopsy

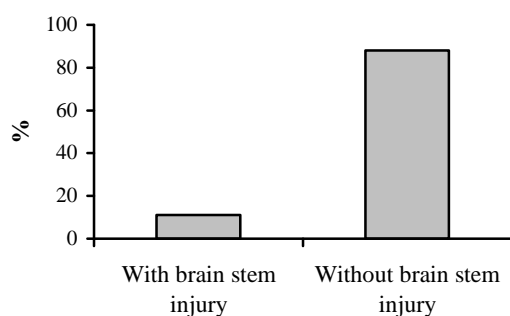


Figure 5. Percentage of CT scan finding in cases

Table 1. Count of true positive and negative and false positive and negative in CT scan

	Positive	Negative
True	161	23
False	16	0

in diagnosis of brain stem lesions and so first hypothesis of study is confirming. More details about CT-Scan true positive and negative and false positive and negative findings are shown in table 1.

According to our results, sensitivity of diagnosis of brain stem lesions was % 59 (%95 CI, 0.42- 0.74). Specificity of diagnosis of brain stem lesions was %100. Positive reporting value of diagnosis of brain stem lesions was %100 and negative reporting value of diagnosis of brain stem lesions was %91 (%95 CI, %58- %94).

Regarding the second hypothesis of this study that prevalence of brain stem injuries in different parts of Brain stem is different, our results are as follows: prevalence of brain stem lesions are obviously different in various areas of brain stem (17 pontine lesions versus 1 cases of cervicomedullary junction) which confirms the hypothesis.

The mean GCS of the patients with and without brain stem injury (Autopsy findings) was 4.1 ± 2.7 and 5.9 ± 2.5 on admission, respectively. Mean GCS of patients with brain stem injury on admission was significantly less than the other patients ($P < 0.001$).

The mean GCS of patients with solitary and multiple injuries were 4.3 ± 2.8 and 3.0 on admission, respectively. There was no significant relationship between GCS of these two groups of patients. (%95CI, 1.7 to 4.2, $p = 0.379$). The mean GCS of patients with concordant CT and autopsy finding was 5.6 ± 2.6 and for patients with difference findings on CT and autopsy the mean

GCS was 4.4 ± 2.8 . There was no meaningful statistical relationship between these two groups.

Discussion

In this study autopsy findings of the brainstem of patients died with head trauma was assessed and compared with premorbid CT findings.

In 39 out of 200 patients, autopsy findings showed brainstem injury. In premorbid CT finding there was 23 (%11.5) cases of brain stem injury. Considering these statistics the sensitivity and the specificity of CT at diagnosis of brainstem lesions compared to autopsy is %59 and %100, respectively.

To the best of our knowledge, this is the first study to compare the results of CT and autopsy findings. The results show that the sensitivity of CT at diagnosis of brainstem lesions is low.

In one study by Tsai and colleagues on 67 patients with brainstem injury, CT demonstrated brain stem injury in 12 (%17.9) of patients.

In another similar study Hashimoto and his colleagues showed that CT could demonstrate brainstem lesion in 21 (%8.7) out of 239 patient with head trauma (14). In these studies and some other studies, the results of the involvement of brainstem in head trauma patients are different in which a variety of factors can cause these differences.

In our study there was no statistically significant relationship between patients with accompanying intracerebral lesions and the patients without such lesions ($P = 0.847$).

Eder and his colleagues in a study on 21 patients with head trauma found similar results to our study. However in order to assess the effects of this factor, further studies are needed.

Because in our study there were a limited number of patients without accompany intracerebral injuries compared to the total number of patients, this may become difficult to interpret from these results.

We also found that there is no meaningful statistical relationship between the type of primary head trauma and the prevalence rate of brainstem injury ($P = 0.343$).

In other studies (17,19,24) it has been demonstrated that the type of primary accident leading to trauma is involved in brainstem injury due to the difference in severity and mechanism of the trauma. One of the reasons that there was no significant relation to abovementioned factor may be the fact that all patients in our study had severe head trauma that led to their death. We

need more controlled studies to assess the mechanism of primary trauma.

Difference in consciousness level (GCS) of patients with and without brainstem injury can cause difference at results of the studies regarding the prevalence of such lesions. In our study the primary GCS of patients with brainstem injury is significantly less than other patients ($P < 0.001$).

In our study there was a significant relationship between the clinical course of patients with brainstem injury and patients without such injuries, and the mean survival duration of the patients with brainstem injury was meaningfully less than the other patients.

In our study we did not find meaningful relationship between the number of brainstem lesions and the prognosis of the patients ($P = 0.442$) but other studies by Hashimoto and his colleagues (1993) showed the worse prognosis of patient with multiple brainstem injuries.

The type of brainstem injuries in order of prevalence were: contusion of pons, medullary contusion, contusion of midbrain, pontomedullary, rupture, cervicomedullary rupture. In a study by Gunji and colleagues the most involved site was medulla. In that study the common reported lesions respectively were pontomedullary tearing, medullary contusion, and cervicomedullary tearing (9). In the study of Ohshima (1998) the most involved site was pontomedullary junction (20). In a study by Kondo et al. (1995) similar findings were reported (28). In a study by Simpson et al (1989) the most involved site was Pontomedullary lesions (21). The causes of difference in involvement sites seem to be the difference in dominant mechanism of primary lesions: in all studies traffic accident was the main cause. In conclusion, in this study the injuries of brainstem were demonstrated in 19.5% of patients. On the other hand, 11.5% of patients had brainstem injury on CTscan.

Sensitivity, specificity, positive reporting value and negative reporting value of CT scanning at diagnosis of brainstem injuries in head trauma patients are 59%, 100%, 100%, and 91%, respectively.

GCS of patients with brainstem injury on admission was meaningfully less than the patients without brainstem injuries.

Survival duration of patients with brainstem injury was significantly less than other patients. There was no statistically significant relationship between the mechanisms of the injury in these patients.

Although our study is unique in its type, more studies with bigger population are needed to get more confident results.

The present study suggests that although the sensitivity of CT is low at diagnosis of brainstem lesions, but its high specificity, availability and cost effectiveness compared to other imaging techniques like as MRI, makes it a recommended imaging method of primary assessment.

In Iran, one of the main reasons of the lack of organ donation is that the families of dead person are not informed properly and on time. It will be more important knowing that "the best donors are young people, and the most often cases of brain death are in this group, based on statistics". In order to short survival and hospitalization period in case of brain stem damages, it seems logical to pay enough attention for keeping useful function of the organs for donation (for example, cornea, kidney, liver and etc.). And in the case of decreased level of GCS, with radiographic signs of brain stem damage, we should consult with the patient's family to take consent for organ donation in the proper time.

Because the CT scan is not so reliable in the case of brainstem damages, MRI may be more helpful (e.g. the Rapid Sequence type to reduce the time of procedure).

As an important limitation of this research it should be considered that all of the cases were the dead patients and though the finding should be carefully used in live patients (CT scan and Autopsy results).

References

1. Winn HR, editor. Youman's Neurological Surgery. 5th ed. Philadelphia: WB Saunders Co.; 2004.
2. Fraser JD, Anderson DR. Deep venous thrombosis: recent advances and optimal investigation with US. *Radiology* 1999;211(1):9-24.
3. Danish SF, Burnett MG, Stein SC. Prophylaxis for deep venous thrombosis in patients with craniotomies: a review. *Neurosurg Focus* 2004;17(4):E2.
4. Sumas ME, Narayan RK. Head injury. In: Grossman RG, Loftus CM, editors. *Principles of Neurosurgery*. 2nd ed. Philadelphia: Lippincott-Raven; 1997. p. 117-71.
5. Brain Trauma Foundation, American Association of Neurological Surgeons, Joint Section on Neurotrauma and Critical Care. Guidelines for the management of severe head injury. *J Neurotrauma* 1996;13(11):641-734.
6. Gray H, Lewis WH. *Gray's Anatomy of the Human Body*. 20th ed. Philadelphia: Lea & Febiger; 2000.
7. Crompton MR. Brainstem lesions due to closed head injury. *Lancet* 1971;1(7701):669-73.
8. Tsai FY, Quinn MF, Itabashi H, Ahmadi J, Teal JS, Segall HD. The role of computed tomography in the evaluation of head trauma. *Excerpta Medica Extract* 1999;6:2-13.

9. Klintworth GH. Paratentorial grooving of human brains with particular reference to transtentorial herniation and the pathogenesis of secondary brainstem hemorrhage. *Am J Pathol* 1968;53:391-408.
10. Lindenberg R, Freytag E. Brainstem lesions characteristic of traumatic hyperextension of the head. *Arch Pathol* 1970;90(6):509-15.
11. Tsai FY, Teal JS, Quinn MF, Itabashi HH, Huprich JE, Ahmadi J, et al. CT of brainstem injury. *AJR Am J Roentgenol* 1980;134(4):717-23.
12. Gruszkiewicz J, Doron Y, Peyser E. Recovery from severe craniocerebral injury with brain stem lesions in childhood. *Surg Neurol* 1973;1(4):197-201.
13. Jellinger K, Seitelberger F. Protracted post-traumatic encephalopathy. Pathology, pathogenesis and clinical implications. *J Neurol Sci* 1970;10(1):51-94.
14. Hashimoto T, Nakamura N, Richard KE, Frowein RA. Primary brain stem lesions caused by closed head injuries. *Neurosurg Rev* 1993;16(4):291-8.
15. George B, Thurel C, Pierron D, Ragueneau JL. Frequency of primary brain stem lesions after head injuries. A CT scan analysis from 186 cases of severe head trauma. *Acta Neurochir (Wien)* 1981;59(1-2):35-43.
16. Firsching R, Woischneck D, Diedrich M, Klein S, Rückert A, Wittig H, et al. Early magnetic resonance imaging of brainstem lesions after severe head injury. *J Neurosurg* 1998;89(5):707-12.
17. Mannion RJ, Cross J, Bradley P, Coles JP, Chatfield D, Carpenter A, et al. Mechanism-based MRI classification of traumatic brainstem injury and its relationship to outcome. *J Neurotrauma* 2007;24(1):128-35.
18. Bazarian JJ, Blyth B, Cimpello L. Bench to bedside: evidence for brain injury after concussion: looking beyond the computed tomography scan. *Acad Emerg Med* 2006;13(2):199-214.
19. Gunji H, Mizusawa I, Hiraiwa K. The mechanism underlying the occurrence of traumatic brainstem lesions in victims of traffic accidents. *Leg Med (Tokyo)* 2002;4(2):84-9.
20. Ohshima T, Kondo T. Forensic pathological observations on fatal injuries to the brain stem and/or upper cervical spinal cord in traffic accidents. *J Clin Forensic Med* 1998;5(3):129-34.
21. Simpson DA, Blumbergs PC, Cooter RD, Kilminster M, McLean AJ, Scott G. Pontomedullary tears and other gross brainstem injuries after vehicular accidents. *J Trauma* 1989;29(11):1519-25.
22. Aguas J, Begué R, Díez J. Brainstem injury diagnosed by MRI. An epidemiologic and prognostic reappraisal. *Neurocirugia (Astur)* 2005;16(1):14-20.
23. Eder HG, Legat JA, Gruber W. Traumatic brain stem lesions in children. *Childs Nerv Syst* 2000;16(1):21-4.
24. Shibata Y, Matsumura A, Meguro K, Narushima K. Differentiation of mechanism and prognosis of traumatic brain stem lesions detected by magnetic resonance imaging in the acute stage. *Clin Neurol Neurosurg* 2000;102(3):124-8.
25. Woischneck D, Klein S, Reissberg S, Peters B, Avenarius S, Günther G, et al. Prognosis of brain stem lesion in children with head injury. *Childs Nerv Syst* 2003;19(3):174-8.
26. Firsching R, Woischneck D, Klein S, Reissberg S, Döhring W, Peters B. Classification of severe head injury based on magnetic resonance imaging. *Acta Neurochir (Wien)* 2001;143(3):263-71.
27. Clifton GL, McCormick WF, Grossman RG. Neuropathology of early and late deaths after head injury. *Neurosurgery* 1981;8(3):309-14.
28. George B, Thurel C, Pierron D, Ragueneau JL. Frequency of primary brain stem lesions after head injuries. A CT scan analysis from 186 cases of severe head trauma. *Acta Neurochir (Wien)* 1981;59(1-2):35-43.