

## Pneumatosis Intestinalis: Autopsy Finding

Behnam Behnoush\*, Shabnam Bazmi, Firozeh Mohammadi, Elham Bazmi, and Gholam Ali Dorvashi

Department of Forensic Medicine, School of Medicine, Tehran University of Medical Sciences, Tehran, Iran

Received: 12 Mar. 2008; Received in revised form: 4 Apr. 2008; Accepted: 14 May 2008

**Abstract-** This is a case of a patient with bowel obstruction, imaging studies were suggestive for pneumatosis intestinalis. Clinically diagnosed as adhesion band and pneumatosis intestinalis. She underwent laparotomy, enterolysis, obstructionolysis and enterorrhaphy. The patient developed respiratory distress and expired after 2 days. At autopsy we found gray-brown discoloration in the wall of some part of small bowel and flattening of mucous membrane. Grossly multiple gas-filled cysts were seen at the serosal surface. Microscopic evaluation of small intestine wall showed multiple cysts located in submucosal and serosal layers.

© 2009 Tehran University of Medical Sciences. All rights reserved.

*Acta Medica Iranica* 2009; 47(5): 415-417.

**Key words:** Pneumatosis intestinalis autopsy cyst

### Introduction

Pneumatosis intestinalis is defined as multiple gas-filled cysts in GI tract (1) and first time described since 1946 by Lerner and Gazin (2). The cysts may be located in subserosa, submucosa and rarely, the muscularis layer. The cysts range in size from a few millimeters to several centimeters (3). It can occur anywhere in the gastrointestinal tract from the esophagus to the large intestine (4). Pneumatosis intestinalis divided in 2 groups: 1. Primary pneumatosis intestinalis (15%) 2. Secondary pneumatosis intestinalis (85%) (5).

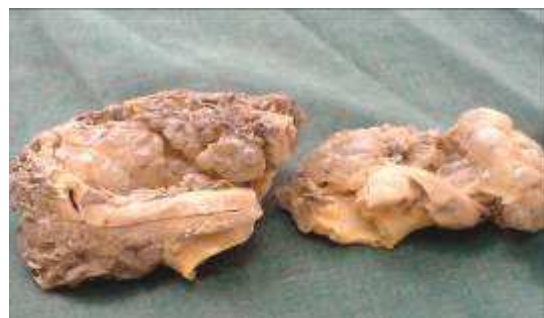### Case Report

A 59 years old woman admitted at emergency room with abdominal distension and obstipation for 3 days. Her past medical history included surgical treatment 8 months ago due to ruptured peptic ulcer. On physical examination, temperature was 38.3, pulse rate 120, respiratory rate 21 and she had generalized abdominal distension and tenderness. Her W.B.C. was 18700 with 69% P.M.N. Plain abdominal radiography and C.T Scan showed: air fluid level at descending colon and air bubble in the wall of small intestine.

Diagnosis: Adhesion band and pneumatosis intestinalis. Patient underwent laparotomy and enterolysis, obstructionolysis and enterorrhaphy. Patient developed generalized abdominal distention and respiratory distress 2 days later. Abdominal radiography showed free air under diaphragm. Patient expired at this day.

**Autopsy Finding:** Abdominal cavity was filled with dark fluid. A rupture 4 cm in length found along greater curvature of stomach, an old rupture at posterior wall of first part of duodenum and a stenotic area 3cm distal to the ruptured site had seen. One meter far from ileocecal valve, the wall of small bowel had gray-brown discoloration and the mucousal layer was flattened. Multiple gas-filled cysts protruded through the mucosa and the serosa.

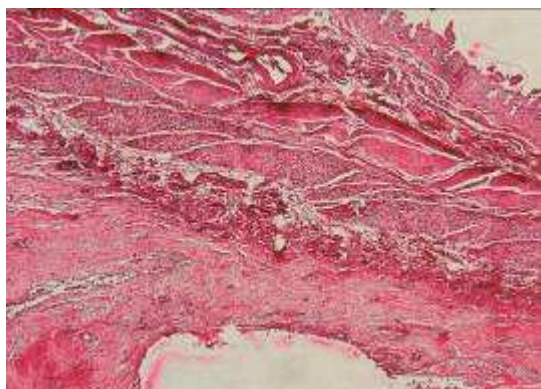
Microscopic studies of small intestine showed multiple cysts situated in submucosa and serosal layer, being partially lined by a row of flattened cells, pink amorphous material, multinucleated giant cells, histiocytes and mixed inflammatory cells. Serosal layer was thickened, due to edema, neovascularization, infiltration of mixed inflammatory cells (especially around cystic structures), proliferation of fibroblasts and in some area fibrosis. Microscopic hemorrhage was seen in some foci of serosal layer.



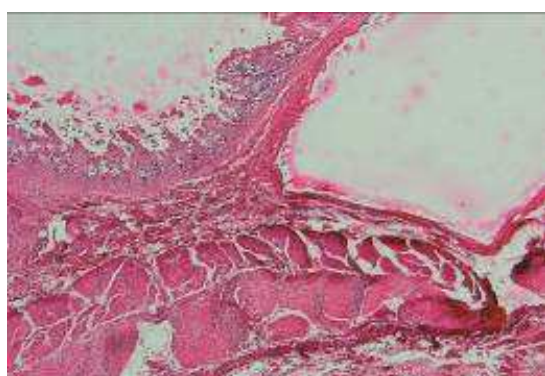
**Figure 1.** Gross pathology of pneumatosis intestinalis

\*Correspondent Author: Gholam Ali Dorvashi

Department of Forensic Medicine, School of Medicine, Tehran University of Medical Science, Tehran, Iran  
Tel: +98 21 66405588, Fax: +98 21 66405588, E-mail: gdorvashi65@yahoo.com



**Figure 2.** Microscopic pathology of pneumatosis intestinalis (serosal cyst)



**Figure 3.** Microscopic pathology of pneumatosis intestinalis (submucosa cyst)

## Discussion

Primary pneumatosis intestinalis (15%) is a benign condition in which, usually cysts form in colon. Usually this form has no associated symptoms, and the cysts may be found incidentally on radiography or endoscopy. This form is often named pneumatosis cystoid intestinalis. The secondary form is associated with obstructive pulmonary disease, as well as obstructive and necrotic gastrointestinal disease (6). Various hypotheses have been proposed to explain the pathogenesis of pneumatosis intestinalis including mechanical, bacterial and biological causes. The formation of pneumatosis intestinalis results from interaction of multiple factors, such as integrity of intestinal wall, intraluminal pressure, bacterial flora and interluminal gases (7). The most common cause is GI disease with bowel necrosis due to bowel ischemia, necrotizing enterocolitis, neutropenic colitis, volvulus and sepsis (8,9). Immunosuppression, bone marrow transplantation, Crohn's disease, ulcerative colitis, trauma and enteral feeding are other causes of

pneumatosis intestinalis (10-12). In the neonate the most common cause of this condition is necrotizing enterocolitis. It is seen in 80% of cases of this disease. Radiologic finding: pneumatosis intestinalis is usually identified on plain radiographs of abdomen. The patterns of radiolucencies are seen as linear, curvilinear, small bubbles, or collection of cysts. Abdominal CT Scan is the best imaging modality for establishing the diagnosis of pneumatosis intestinalis. CT can depict small amount of intramural gas non shown in plain radiographs. Thickened bowel wall with contrast enhancement may suggest ischemia in the setting of pneumatosis. Dilated bowel loop and fluid level suggest an obstruction of pneumatosis. MRI may be useful in identifying ischemia as a cause for pneumatosis. Ultrasonography of abdomen shows circumferential, bright, echogenic foci within wall that represent the gas bubbles (3,6).

**Intervention:** Underlying cause of pneumatosis intestinalis can help in tailoring of appropriate treatment. Most patients with primary pneumatosis intestinalis require no management. The cysts usually resolve spontaneously.

Symptomatic primary pneumatosis may be treated with oxygen therapy, which reduces the partial pressure of hydrogen gas in the capillaries and increases resorption of the cystic gas. Occasionally, recurrent pneumatosis is treated with antibiotics in an effort to decrease bacterial production of gas. Surgical intervention is recommended if bowel ischemia or perforation is present. Pneumatosis is an ominous radiographic finding in patients who are suspected of having bowel ischemia, and surgery should be performed in patients who are not responding to nonoperative treatment, especially those with signs of perforation, peritonitis, or abdominal sepsis. As many as 50% of patients may require surgery for perforation (6). **Autopsy Finding:** The cysts in pneumatosis intestinalis have a submucosal or subserosal location and contain a high concentration of hydrogen (up to 50%).

Microscopic analysis of fulminant pneumatosis intestinalis demonstrates gas cysts in the submucosa, compounding a picture of ischemic bowel infarct with secondary bacterial overgrowth. The serosal cysts usually occur near the mesenteric border. They may be partially lined by endothelial cells and are surrounded by foreign body giant cells. Histologically, there may be tears in the submucosal connective tissue in the benign form of pneumatosis intestinalis. Inflammation with neutrophils, eosinophils, plasma cell, lymphocytes and epithelioid granulomas can be appears (13,14),

## References

1. Solorzano J, Bhatt S, Dogra VS. Pneumatosis intestinalis of the sigmoid colon secondary to repetitive injury to the rectum from the insertion of foreign bodies [Online]. 2007 Aug 22. Available from:  
URL:<http://www.medscape.com/viewarticle/561568>
2. Donati F, Boraschi P, Giusti S, Spallanzani S. Pneumatosis cystoides intestinalis: imaging findings with colonoscopy correlation. *Dig Liver Dis* 2007;39(1):87-90.
3. al-Kharrat H, Soloway G, Grayer D, Roberts I. Pneumatosis intestinalis [online]. 2002 Apr. Available from:  
URL:<http://www.bridgeporthospital.org/gme/caseofmonth.html>
4. Perry CW, Phillips BJ. Pneumatosis intestinalis: A fractured hip? [Online]. 2009 Oct 16. *Internet J Gastroenterol*. Available from: URL:  
<http://www.ispub.com/ostia/index.php?xmlFilePath=journal/s/ijge/vol1n2/pneumatosis.xml>
5. Kahn CE Jr. Pneumatosis intestinalis [Online]. 2002 Apr 18. Available from:  
URL:<http://chorus.rad.mcw.edu/to-go/00846.html>
6. Goyal KS. Pneumatosis intestinalis [Online]. 2005 Jan 26. Available from:  
URL:<http://emedicine.medscape.com/article/371955-overview>
7. Goldberg E, LaMont JT. Pneumatosis intestinalis [Online]. 2009. Available from:  
URL:[http://www.uptodate.com/patients/content/topic.do?topicKey=gi\\_dis/29790](http://www.uptodate.com/patients/content/topic.do?topicKey=gi_dis/29790)
8. Torreggiani WC, Lyburn ID, Harris AC, Munk PL. Luminal gas mimicking pneumatosis intestinalis. *J Hong Kong Coll Radiol* 2002;5:114-6.
9. Pear BL. Pneumatosis intestinalis: a review. *Radiology* 1998;207(1):13-9.
10. Zülke C, Ulbrich S, Graeb C, Hahn J, Strotzer M, Holler E, et al. Acute pneumatosis cystoides intestinalis following allogeneic transplantation: the surgeon's dilemma. *Bone Marrow Transplant* 2002;29(9):795-8.
11. Gillett PM, Russell RK, Wilson DC, Thomas AE. C difficile induced pneumatosis intestinalis in a neutropenic child. *Arch Dis Child* 2002;87(1):85.
12. Smith CD, Sarr MG. Clinically significant pneumatosis intestinalis with postoperative enteral feedings by needle catheter jejunostomy: an unusual complication. *JPEN J Parenter Enteral Nutr* 1991;15(3):328-31.
13. Murphy ME, Rydzak E. Miscellaneous inflammatory and structural disorder of the colon. In: Yamada T, Alpers DH, Laine L, Owyang C, Powell DW, Silverstein FE, editors. *Textbook of Gastroenterology*. 3<sup>rd</sup> ed. Philadelphia: Lippincott Williams and Wilkins; 1999. p. 83,1878.
14. Mills SE, Carter D, Greenson JK, Oberman HA, Reuter V, Stoler MH, editors. *Sternberg's Diagnostic Surgical Pathology*. 4<sup>th</sup> ed. Philadelphia: Lippincott, Williams and Wilkins; 2004.