

Cerebral Tuberculoma in Pregnancy: Overview of the Literature and Report of A Case

Seyed Ali Ahmadi¹, Hadi Roozbeh², Ali Abbasi¹, Moslem Bahadori¹,
Katayoun Gohari Moghaddam³, and Seyed Ebrahim Ketabchi²

¹ Department of Pathology, Sina Hospital, Tehran University of Medical Sciences; Tehran, Iran

² Department of Neurosurgery, Sina Hospital, Tehran University of Medical Sciences; Tehran, Iran

³ Department of Pathology, 501 Hospital, Army University of Medical Sciences; Tehran, Iran

Received: 21 Dec. 2008; Received in revised form: 2 Sep. 2009; Accepted: 7 Nov. 2009

Abstract- Tubercle bacilli infect about one third of the world's population and over the past decade resurgence of tuberculosis has been a major health threat mainly due to increasing frequencies of immunosuppressive states and drug-resistant organisms. Although tuberculosis is essentially a lung disease, intracranial elements become involved in 5-10% of cases either as meningitis or tumour-like masses (tuberculoma). Tuberculoma is common in endemic areas but its occurrence during pregnancy is occasional and of particular interest is its intriguing clinical picture mimicking toxemia of pregnancy and brain tumor. In addition, the effects of pregnancy on tuberculosis or vice versa have been controversial. We present here a review of the recent literature and discuss a case coming to medical attention with manifestations of intracranial hypertension during 2 consecutive pregnancies; 4 years apart. On operation a dura-attached mass was detected that proved to be a tuberculoma. After 18 months of close observation and under drug therapy she obviously improved with no ensuing complication. Immunodeficiency state associated with pregnancy is likely to play a role in activation of infection. Tuberculoma should be considered in differential diagnosis of eclampsia and brain mass particularly in women coming from endemic areas for this infection even in the absence of pulmonary involvement.

© 2011 Tehran University of Medical Sciences. All rights reserved.

Acta Medica Iranica, 2011; 49(1): 64-69.

Keywords: Brain; Tuberculosis; Cerebrum; Tuberculoma; Pregnancy; Seizures

Introduction

Mycobacterium tuberculosis (MT) infects about 2 billion people worldwide and 1 in 10 people infected with MT will have active tuberculosis (TB) in their lifetime (1). There were 9.2 million new TB cases in 2006 and the total number of deaths and cases is still rising. Moreover, nearly 4 out of 10 TB cases are still not being properly detected and treated (1). TB is second only to HIV as a cause of death worldwide resulting from a single infectious agent (2) and eighty percent of all incident TB cases were found in 22 high-incidence countries (including Afghanistan) (3). Another threat of this dreadful disease is its drug resistance. Multidrug-resistant TB (MDR-TB) is a form of TB that fails to respond to standard first line drugs and WHO reported in 2008 the highest rates of MDR-TB ever recorded with

peaks up to 22% of new TB cases in some areas. Even the worst is extensively drug-resistant TB (XDR-TB) that occurs when resistance to second-line drugs develops and is virtually untreatable. There are an estimated 40,000 new XDR-TB cases annually (1). Between 1910 and 1931, 34% of intracranial masses in the USA and Europe were reported as tuberculomas but later the ratio fell to less than 4%. In developing countries tuberculomas still constitute about one-third of intracranial masses. Intracranial Tuberculomas are usually solitary lesions, but 15- 34% are multiple (4). Multiple central nervous system (CNS) tuberculomas in an immunocompetent patient may closely resemble metastatic malignancy (5). The diagnosis and management of tuberculoma is an important public health problem in both developing and industrialised nations but unlike pulmonary tuberculosis, which has

Corresponding Author: Seyed Ali Ahmadi

Department of pathology, Sina Hospital, Tehran University of Medical Sciences; Tehran, Iran
Tel: +98 21 66701041-9, Fax: +98 21 66716545, E-mail: ahmadise@tums.ac.ir

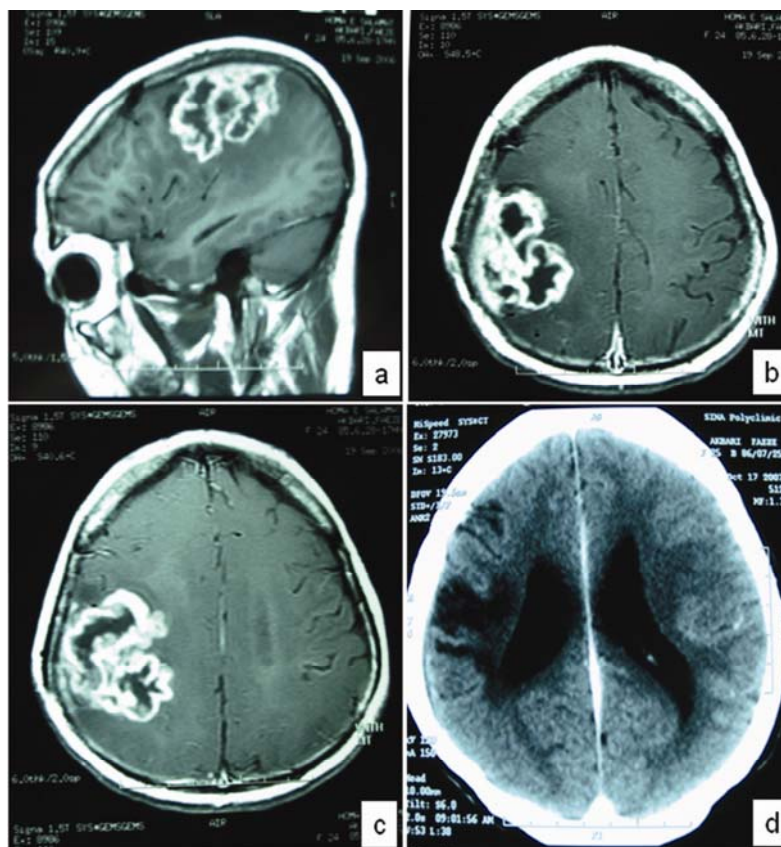


Figure 1. Axial MRI showing dura-based contrast-enhancing lesion (a-c). One year post-operative CT scan with contrast showing complete removal and post-operative pencephalic changes (d).

been under close investigations, the diagnosis and treatment of tuberculomas have received little consideration (4). The central nervous system (CNS) involvement comprises about 10-15% of infections and appears as either meningitis or meningoencephalitis (6) with tuberculomas being the most common variant of neuroparenchymal TB and being usually unaccompanied by coexistent meningeal involvement (7). Tuberculomas are tumour-like (oma=tumour) space occupying lesions and may manifest with seizures or signs of raised intracranial pressure, localized neurological deficits or even behavioral problems (2, 8). The bacteria are transmitted through inhalation. Usually an early haematogenous spread occurs. Cerebral location of TB is related to the pattern of blood flow and usually involves the corticomedullary junction and periventricular regions. Hematogenous spread of tubercle bacilli is further supported by the vascular distribution of the lesions in the region of middle cerebral artery (9). Tuberculomas usually represent reactivation of a latent tuberculous focus; sometimes after many years (10). On microscopic examination tuberculomas have central caseation necrosis, chronic granulomatous inflammation and Langhans'-type giant

cells surrounded by thick fibrous wall. Although suffering from TB during pregnancy has been widely studied (10-13), medical opinion about the interaction between pregnancy and TB has changed several times since antiquity (14) and there are only few case reports of cerebral tuberculoma during pregnancy (8, 14, 15). Our aim is to present a case and review the pathogenic, clinical and diagnostic aspects of tuberculoma in pregnancy with stressing the possible misdiagnoses that may be made in this particular situation.

Case Report

The patient is a 25 year old gravida 2, para 2, Afghan woman who was referred to our hospital because of generalized tonic-clonic seizures 7 hours following delivery. She has migrated to Iran 10 months before her second delivery. 4 years ago about 9 days following her first vaginal delivery in Afghanistan she was admitted to a regional hospital for treatment of allegedly tuberculous meningitis. Her medical records were not available but she told that she regularly used the drugs for 6 months following discharge. Later on she had no problem until her second pregnancy when she experienced mild

Cerebral tuberculoma in pregnancy

headache and weakness of her left hand and leg about 9 months earlier. During 6th month of pregnancy she had one bout of seizures but did not seek any medical attention. She has a healthy 4-year-old daughter and her full-term newborn son has no abnormality. Her parents, siblings and her husband are healthy but live in poor socioeconomic condition. She has no habits, no any other medical problem and no history of trauma or drug use. On physical examination she appeared wasted and pale but conscious and well oriented with normal blood pressure and vital signs and no sign of meningeal irritation. Neurological examination revealed mild bilateral nystagmus and moderate papillary edema associated with left hemiparesis (grade 3/5), hyperactive left knee jerk and up going plantar response on left side. Chest x-ray and electrocardiogram were normal. Laboratory tests showed mild hypochromic anaemia and raised ESR (43mm/hour). PPD skin test showed 8mm induration without blister formation. Serologic test for HIV (ELISA) was negative. Cerebrospinal fluid analysis showed mild mononuclear pleocytosis, slightly increased protein (82mg/dl) with normal glucose and no malignant cells. MRI disclosed a dura-based cortical lesion in right parietal lobe associated with edema and contrast enhancement along with midline shift and relative dilation of the left lateral ventricle (Figure 1a-c).

Findings were suggestive of a cerebral tumour probably meningioma, lymphoma or metastasis. On craniotomy a firm whitish creamy unsuctionable tumor-like lesion found in right parietal lobe attached to the dura mater. The lesion was resected with initial impression of en-plaque or superficially invasive meningioma. On microscopic examination dura and brain tissue were involved with granulomatous inflammation bearing Langhans'-type giant cells and focal areas of necrosis (Figure 2).

No acid-fast microorganism was visible by Ziehl-Neelsen and Auramine-Rodamine methods. PAS-stained slides were negative for fungi and no evidence of tumoural process was identified. Sputum smears and cultures were negative for mycobacteria in 3 occasions. Final histopathologic diagnosis was necrotizing granulomatous inflammation suggestive of tuberculoma. Drug therapy initiated using isoniazid, rifampin, pyrazinamide and ethambutol along with vitamin B6 and intravenous glucocorticoids. No more convulsions developed and the patient was discharged from hospital with no complications. After 3 months only isoniazid and rifampin continued for additional 15 months

Eighteen months after operation the general condition of the patient improved, no convulsions reported, chest x-ray was unremarkable and CT-scans showed disappearance of lesions (Figure 1d).

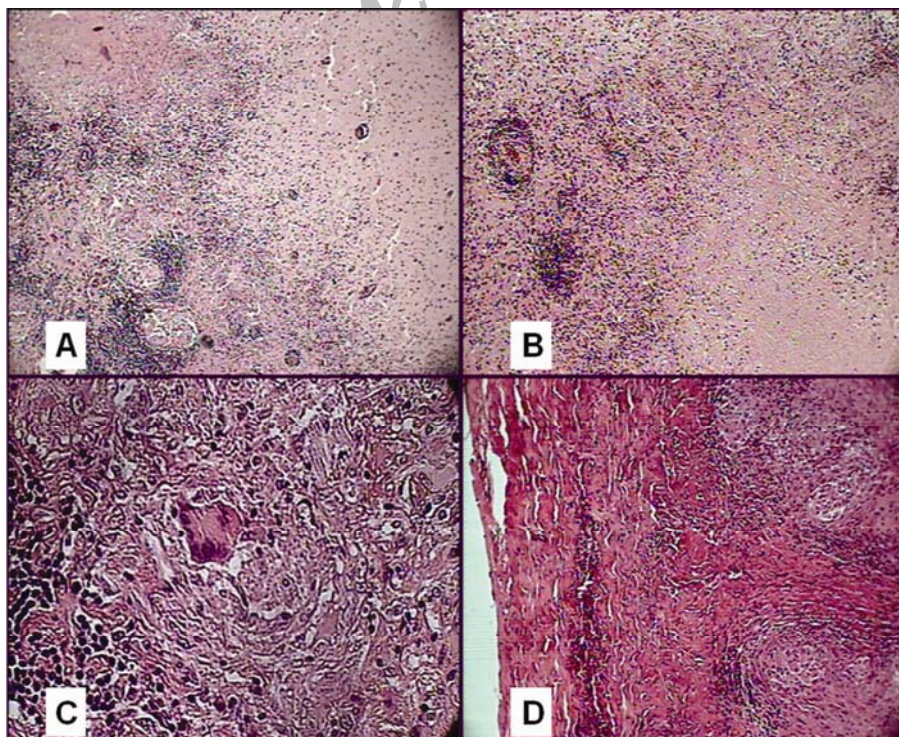


Figure 2. Granulomatous infiltration of brain tissue (A - $\times 50$) with caseation necrosis (B - $\times 100$), Langhans' giant cells (C - $\times 400$) and dural involvement (D - $\times 100$)

Discussion

This patient has emigrated recently from Afghanistan. The WHO estimated sputum smear positive pulmonary TB incidence in Afghanistan is 125 per 100,000. This incidence is 1-2 in western countries and 12 per 100,000 in Iran (16). TB is primarily a lung disease but extrapulmonary involvement is common. CNS tuberculosis accounts for about 5-10% of immunocompetent TB cases (10, 12). CNS tuberculomas are rare in the US but in developing countries they constitute 5-30% of all intracranial masses (17). TB may be the first manifestation of HIV infection (18). Our patient was HIV-negative and had no symptom or sign in favor of immunodeficiency state. She was afebrile with no pulmonary symptoms and unremarkable chest x-ray. In more than half of TB meningitis cases, evidence of old pulmonary lesions or a miliary pattern is found on chest x-ray (12). Mayers reported 7 of 12 intracranial tuberculoma patients (58%) having signs of extracranial TB at presentation (10). Our patient presented with seizures accompanied by headache, papilledema and hemiparesis. Seizures is one of the most common symptoms occurring in up to 85% of cases along with symptoms related to elevated intracranial pressure such as headache, papilledema and lethargy as well as symptoms of focal mass lesion like weakness, hemiparesis and ataxia occurring in 70% of patients (10). On craniotomy the initial impression was a tumour rather than inflammatory process. In fact tuberculomas have been unexpected findings during surgery for cerebral tumours (10). In this case the lesion appeared as a dura-based tumour. Tuberculomas are only exceptionally dura-based rather than intra-axial (19). In our case cerebral tuberculosis had its clinical presentation during or shortly after pregnancy in two occasions; 4-years apart; had been more pronounced in second pregnancy and had not been associated with any complication for mother or infant. In medical history there has been much debate about the adverse effects of pregnancy on TB or vice versa. From the time of Hippocrates until the middle of 19th century it was thought that pregnancy had a beneficial effect on tuberculosis. A diametrically opposite view was taken from 1850 until the 1940s, and therapeutic abortion was frequently recommended for these patients (14). Subsequently some authors believed that pregnancy and labor had no harmful effects on women with TB, particularly following chemotherapy. Nevertheless, other studies indicated deterioration or progression of disease during pregnancy or first postpartum year

particularly in cases with CNS involvement (14). Some authors even believe that the immunosuppression related to pregnancy can lead to infectious processes similar to that occurs in immunocompromised hosts (9, 11, 13, 20). On the other hand it has been stated that pulmonary TB is associated with excessive occurrence of pregnancy complications, miscarriage and difficult labor (14). Emerson *et al.* reported multiple cerebral tuberculomas and military lung TB developing during pregnancy in an immunocompetent previously healthy young woman and emphasized the aggressive dissemination of TB related to immunosuppression associated with pregnancy (9). In our case cerebral tuberculosis manifested during two consecutive pregnancies and this may indicate progression of disease in pregnancy; however; TB had no harmful effects on pregnancy. A closely similar case has also been reported by Liu *et al.* This intriguing case is a 29-year-old Mexican American pregnant woman with history of seizures and brain tuberculoma during her previous pregnancy 7 years ago, presenting this time with culture-confirmed tuberculous meningoencephalitis in her second pregnancy. The patient was asymptomatic and took no drugs between two pregnancies and the authors concluded that in this case TB had been reactivated during pregnancy (21). The diagnosis of tuberculoma during pregnancy is difficult because often the eclampsia becomes the presumptive diagnosis in a convulsive pregnant woman; however; patients with tuberculoma – as in our case – are usually normotensive and have no proteinuria. Although an increased attenuation, an isodense ring or a disc lesion on CT with perilesional edema which persists for few weeks and is not a post-ictal phenomenon strongly suggests tuberculoma (22) the variability in appearance of tuberculomas on MRI and CT sometimes makes them difficult to differentiate from neoplasms, pyogenic abscesses and other granulomatous diseases such as sarcoidosis (10). In this case typical caseating granulomas and Langhans'-type giant cells were present but direct tissue staining failed to disclose mycobacteria. Although histopathological diagnosis of biopsy specimens is the golden standard of diagnosis (6, 10); the etiologic agent can not be seen by direct staining in the majority of patients (6) and mycobacteria are generally difficult to grow from biopsy cultures. Meanwhile, caseating granulomas, epithelioid histiocytes and Langhans' giant cells are so characteristic for diagnosis of TB that paraffin sectioning and histopathological examination is said to have an overall diagnostic efficacy of 85% (4). Newer methods such as PCR may be much more helpful (6,

10). Standard antituberculous regimen for the pregnant woman includes isoniazid, rifampin, pyrazinamide and ethambutol for 2-3 months followed by isoniazid and rifampin for more 12-15 months (10, 17). For any drug accessing the CNS, it should be able to exit the blood vessels and overcome the blood-brain barrier. Intracranial micro-tuberculomas grow slowly and become encapsulated. In the same time, local immunological reaction may induce perilesional secondary granulomatous vasculitis associated with occlusion of the vessel lumen further hindering the penetration of the anti-tuberculous drugs into the lesion (23). Upon exposure, ethambutol kills most of the rapidly proliferating bacilli in the first 14 days of treatment. Thereafter rifampin kills low or non-replicating organisms and pyrazinamide kills those in low-penetration sites for other drugs (24). The effect of dexamethasone (glucocorticoids) on CNS tuberculoma is not clear, although some authors report improved survival (24). Our patient benefited from combination drug therapy including isoniazid, rifampin, pyrazinamide, ethambutol and glucocorticoids with no reported adverse effects from drugs or operation and no disease progression during 18 months follow-up.

In conclusion; cerebral tuberculoma should be considered in differential diagnosis of eclampsia or brain tumour in any pregnant woman particularly those coming from High-incidence areas even in the absence of pulmonary involvement.

References

1. World Health Organization. Tuberculosis Facts 2008/WHO Fact Sheets on Tuberculosis and Stop TB Partnership [Online]. 2008 Apr [cited 2011 Mar 1]; Available from: URL:http://www.who.int/tb/publications/2008/factsheet_a_pril08.pdf
2. Fitzgerald D, Haas DW. Mycobacterium tuberculosis. In: Mandell GL, Bennett JE, Dolin R, editors. Principles and Practice of Infectious Diseases. 6th ed. Philadelphia: Elsevier Churchill Livingstone; 2005. p. 2852-86.
3. Dye C, Scheele S, Dolin P, Pathania V, Raviglione MC. Consensus statement. Global burden of tuberculosis: estimated incidence, prevalence, and mortality by country. WHO Global Surveillance and Monitoring Project. JAMA 1999;282(7):677-86.
4. Abuhamed M, Bo X, Yan C. Central Nervous System Tuberculomas: A Review Article. Am J Infect Dis 2008; 4(2): 168-173
5. Zavascki AP, Dias AE, Cruz RP, de Oliveira RL, Duquia RP. Intracranial tuberculomas in an immunocompetent patient mimicking brain metastasis of unknown origin. Infection 2006;34(3):181-2.
6. Bayindir C, Mete O, Bilgic B. Retrospective study of 23 pathologically proven cases of central nervous system tuberculomas. Clin Neurol Neurosurg 2006;108(4):353-7.
7. Rosenblum MK. Central nervous system. In: Rosai J, editor. Rosai and Ackerman's Surgical Pathology. 9th ed. Philadelphia: Mosby; 2004. p. 2487-90.
8. Feenstra B, Termeer A, Verhagen WI, van Dijk Azn R, Dofferhoff AS. Intracerebral tuberculomas in a pregnant Somalian woman. Ned Tijdschr Geneesk 1999;143(49):2475-8.
9. Gasparetto EL, Tazoniero P, de Carvalho Neto A. Disseminated tuberculosis in a pregnant woman presenting with numerous brain tuberculomas: case report. Arq Neuropsiquiatr 2003;61(3B):855-8
10. Hua SE, Clatterbuck RE, Stern BJ, Sampath P, Rhines LD. Tuberculosis. In: Winn HR, Dacey RG Jr, editors. Youman's Neurological Surgery. 5th ed. Philadelphia: WB Saunders; 2004. p. 1439-43.
11. Pearson H. Reproductive immunology: Immunity's pregnant pause. Nature 2002;420(6913):265-6.
12. Raviglione MC, O'Brien RJ. Tuberculosis. In: Kasper DL, Braunwald E, Fauci AS, Hauser SL, Longo DL, Jameson JL, editors. Harrison's Principles of Internal Medicine. 16th ed. New York: McGraw-Hill; 2005. p. 953-66.
13. Rich KC, Siegel JN, Jennings C, Rydman RJ, Landay AL. CD4+ lymphocytes in perinatal human immunodeficiency virus (HIV) infection: evidence for pregnancy-induced immune depression in uninfected and HIV-infected women. J Infect Dis 1995;172(5):1221-7.
14. Weinberger SE, Weiss ST. Tuberculosis. In: Burrow GN, Duffy TP, Coppel JC, editors. Medical Complications During Pregnancy. 5th ed. Philadelphia: WB Saunders; 1999. p. 380-400.
15. Gasparetto EL, Tazoniero P, de Carvalho Neto A. Disseminated tuberculosis in a pregnant woman presenting with numerous brain tuberculomas: case report. Arq Neuropsiquiatr 2003;61(3B):855-8.
16. World Health Organization, Global Tuberculosis Control: Surveillance, Planning, Financing. WHO reports 2005, 2006 and 2007, Geneva, Switzerland [Online]. 2010 Aug 5 [cited 2011 Mar 1]; Available from: URL:http://www.who.int/tb/publications/global_report/en/ and http://www.phac-aspc.gc.ca/tbpc-latb/itir_e.html
17. Ropper AH, Brown RH. Infections of the nervous system. In: Ropper AH, Brown RH, editors. Adams and Victor's Principles of Neurology. 8th ed. New York: McGraw-Hill; 2005. p. 609-12.

18. Barnes PF, Bloch AB, Davidson PT, Snider DE Jr. Tuberculosis in patients with human immunodeficiency virus infection. *N Engl J Med* 1991;324(23):1644-50.
19. Bauer J, Johnson RF, Levy JM, Pojman DV, Ruge JR. Tuberculoma presenting as an en plaque meningioma. Case report. *J Neurosurg* 1996;85(4):685-8.
20. Covelli HD, Wilson RT. Immunologic and medical considerations in tuberculin-sensitized pregnant patients. *Am J Obstet Gynecol* 1978;132(3):256-9.
21. Liu C, Christie LJ, Neely J, Gandhi M, Jacobs RA, Bollen A, et al. Tuberculous meningoencephalitis in a pregnant woman presenting 7 years after removal of a cerebral granuloma. *Eur J Clin Microbiol Infect Dis* 2008;27(3):233-6.
22. Draouat S, Abdenabi B, Ghanem M, Bourjat P. Computed tomography of cerebral tuberculoma. *J Comput Assist Tomogr* 1987;11(4):594-7.
23. Bas NS, Güzey FK, Emel E, Alatas I, Sel B. Paradoxical intracranial tuberculoma requiring surgical treatment. *Pediatr Neurosurg* 2005;41(4):201-5.
24. Thwaites GE, Macmullen-Price J, Tran TH, Pham PM, Nguyen TD, Simmons CP, et al. Serial MRI to determine the effect of dexamethasone on the cerebral pathology of tuberculous meningitis: an observational study. *Lancet Neurol* 2007;6(3):230-6.

Archive of SID