

Case Report of a Perforated Appendix in the Sac of Inguinal Hernia (Amyand's Hernia)

Ali Ghafouri, Taha Anbara, Ali Mir, and Zhamak Khurgami

Department of Surgery, School of Medicine, Tehran University of Medical Sciences, Tehran, Iran

Received: 1 May 2011; Received in revised form: 15 Jul. 2011; Accepted: 19 Aug. 2011

Abstract- This case is a rare aspect of inguinal hernia. The patient was admitted with a 10-day pain of right groin and a past history of an inguinal hernia which was irreducible at the time of admission. In the operating room, the hernia sac was opened which included a perforated and gangrenous appendix that is called Amyand's hernia. The patient underwent appendectomy and herniorrhaphy at the same operation.

© 2011 Tehran University of Medical Sciences. All rights reserved.

Acta Medica Iranica, 2011; 49(12): 828-830.

Keywords: Appendicitis; Incarcerated inguinal hernia; Amyand's hernia

Introduction

Incarcerated inguinal hernia is one of the most common complaints of patients present in emergency surgery department. Inguinal hernia sac usually contains bowels or omentum. Sometimes bladder or the Meckel's diverticulum may be within the sac (Littre's hernia). The appendix within the sac of inguinal hernia is termed Amyand's hernia and was first described by Amyand in 1736 (1). In 1% of cases the appendix is in the hernia sac and 0.13% of cases is reported as a perforated appendicitis (2).

Case Report

An 80 years old man presented to emergency department of Dr Shariati hospital with bulging of right groin and pain of this area for 10 days. Constipation and obstipation was added to his complaints since 3 days before admission. The pain was constant and localized on the bulging area with no radiation. Nausea and vomiting was developed in the last day. Patient had no history of specific disease such as diabetes, hypertension or ischemic heart disease and was not under any medication. Patient's temperature was 36.8°C and he did not have tachycardia. The abdomen was soft on palpation but in the right groin there was a 4 x 4 cm firm and tender bulging which was extended into the scrotum and scrotum was erythematous.

The laboratory data showed a leukocytosis of 10,200 white blood cells per dl, LDH: 403 U/dl, Amylase: 58 U/dl and the arterial blood gas showed pH: 7.5, PO₂: 54

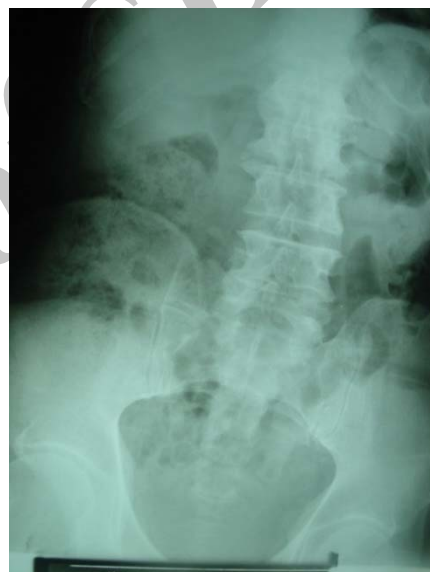

Figure 1. Upright plain abdominal image

mmHg, PCO₂: 40.9 mmHg, bicarbonate: 24.6 mEq/l, Base Excess: 2 mEq/l. Abdominal X ray was unremarkable (Figures 1,2).

Patient was taken to the operating room with the diagnosis of incarcerated inguinal hernia and underwent a spinal anesthesia. The classic incision of inguinal hernia was created. The erythematous and edematous spermatic cord and hernial sac appeared. About 10 ml of pus accumulated inside the sac. Also an inflamed and perforated appendix was seen at the distal end of the sac. Appendectomy was carried out followed by abdominal irrigation with normal saline. Herniorrhaphy was done and a vacuum drain was made in that area.

Corresponding Author: Ali Ghafouri

Department of Surgery, Thoracic and General Surgeon, Tehran University of Medical Sciences, Tehran, Iran
Tel: +98 21 84902450, 912 3465439, Fax: +98 21 88633039, E-mail: alighafouri3@gmail.com

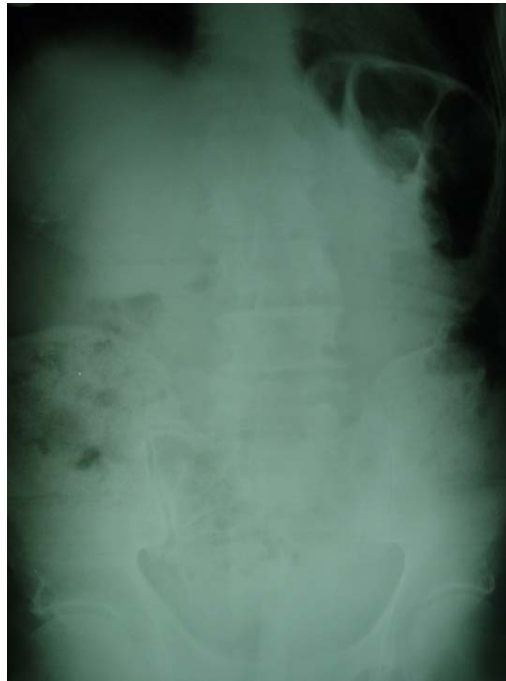

Figure 2. Supine plain abdominal image

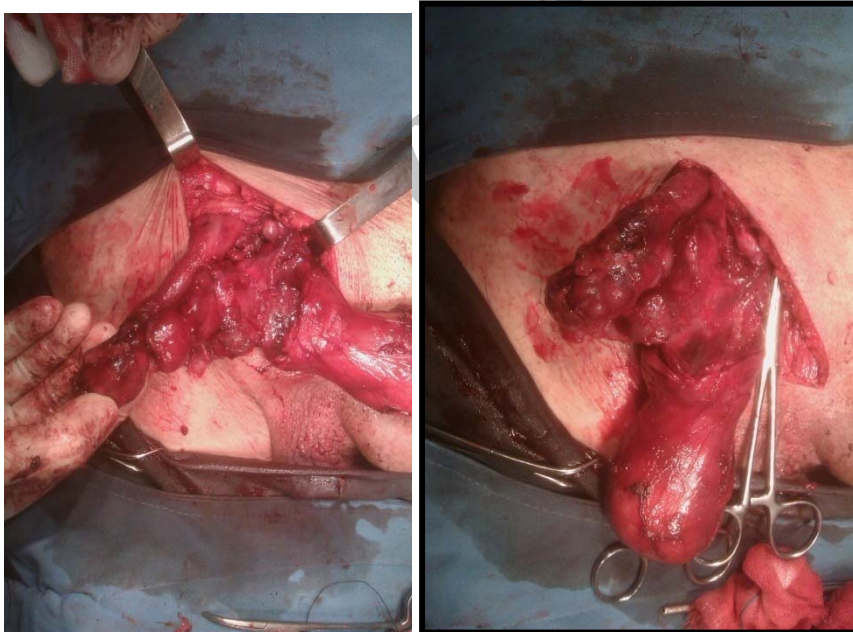


Figure 3. Inflamed appendix and hernial sac are illustrated.

Discussion

Amyand's hernia is defined as the presence of appendix in an inguinal hernia sac. The herniated appendix can be normal, acutely inflamed, or perforated (3). The relationship between inflammation and incarceration of appendix is not recognized yet (4). The first appendectomy was performed in 1736 by Claudius

Amyand on an 11 year old boy with an inguinal hernia (1). Appendix within an inguinal hernia sac is not uncommon but perforated appendicitis in the sac is a rare condition. The age of the patients ranges between 6 to 88 years old and most commonly present as an increasing tenderness on previous inguinal hernia mimicking strangulation (2).

In present case, the presentation was an incarcerated hernia plus constipation and obstipation with pain, nausea and vomiting. In previous reports there has been abscess formation. The differential diagnosis in last reports was strangulated hernia, testicular torsion and acute epididymitis (2).

The usual procedure for herniated appendicitis is appendectomy through herniotomy. It is associated with a mortality rate of 14% to 30% (2).

In our case we did the appendectomy through the hernial incision and placed a drain inside the infected site. We also did the classic herniorrhaphy as well.

References

1. Mohamed A, Bhatti T, Mahmoud AR, Abukhater M. Amyand: A Forgotten Surgeon And Hernia. Case Presentation And Literature Review. Internet J Urology 2010;7(1).
2. House MG, Goldin SB, Chen H. Perforated Amyand's hernia. South Med J 2001;94(5):496-8.
3. Milanchi S, Allins AD. Amyand's hernia: history, imaging, and management. Hernia 2008;12(3):321-2.
4. Bhide SS. Amyand's hernia. [RSS] RSS Save search Limits Advanced Help Display Settings: Abstract Send to: Indian J Pediatr 2009;76(8):854-5.

Archive of SID