

Crataegus monogyna Aqueous Extract Ameliorates Cyclophosphamide-Induced Toxicity in Rat Testis: Stereological Evidences

Ali Shalizar Jalali, Shapour Hasanzadeh, and Hassan Malekinejad

Department of Basic Sciences, Faculty of Veterinary Medicine, Urmia University, Urmia, Iran

Received: 24 May 2011; Received in revised form: 12 Aug. 2011; Accepted: 5 Sep. 2011

Abstract- Cyclophosphamide (CP) is extensively used as an antineoplastic agent for the treatment of various cancers, as well as an immunosuppressive agent. However, despite its wide spectrum of clinical uses, CP is known to cause several adverse effects including reproductive toxicity. *Crataegus monogyna* is one of the oldest pharmaceutical plants that have been shown to be cytoprotective by scavenging free radicals. The present study was conducted to assess whether *Crataegus monogyna* fruits aqueous extract with anti-oxidant properties, could serve as a protective agent against reproductive toxicity during CP treatment in a rat model. Male Wistar rats were categorized into four groups. Two groups of rats were administered CP at a dose of 5 mg in 5 ml saline/kg/day for 28 days by oral gavages. One of these groups received *Crataegus monogyna* aqueous extract at a dose of 20 mg/kg/day orally four hours after cyclophosphamide administration. A vehicle treated control group and a *Crataegus monogyna* control group were also included. The CP-treated group showed significant decreases in the body, testes and epididymides weights as well as many histological alterations. Stereological parameters and spermatogenic activities (Sertoli cell, repopulation and mitotic indices) were also significantly decreased by CP treatment. Notably, *Crataegus* coadministration caused a partial recovery in above-mentioned parameters. These findings indicate that *Crataegus monogyna* may be partially protective against CP-induced testicular toxicity.

© 2012 Tehran University of Medical Sciences. All rights reserved.

Acta Medica Iranica, 2012; 50(1): 1-8.

Keywords: *Crataegus monogyna*; Cyclophosphamide; Toxicity; Testis

Introduction

Cyclophosphamide (CP), is a widely used cytotoxic alkylating agent with antitumor and immunosuppressant properties. It is used for the treatment of chronic and acute leukemia, multiple myeloma, lymphomas, rheumatic arthritis and systemic lupus erythematosus and in preparation for bone marrow transplantation (1). Cyclophosphamide undergoes bioactivation by the hepatic microsomal cytochrome P450 mixed function oxidase system to active metabolites that enter the circulatory system. Phosphoramidate mustard and acrolein are the two active metabolites of cyclophosphamide (2). The antineoplastic effects of cyclophosphamide are associated with phosphoramidate mustard, whereas acrolein is linked to toxic side effects like cell death, apoptosis, oncosis and necrosis (3). In spite of its therapeutic importance, a wide range of adverse effects including reproductive toxicity has been demonstrated following cyclophosphamide treatment in humans and

experimental animals (4). Adult male patients treated with CP have demonstrated diminished sperm counts and an lack of spermatogenic cycles in their testicular tissue (5). Previous studies on male rats have confirmed the potential of CP to cause oligospermia, azoospermia and histological alterations in the testis and epididymis (6,7). Decrease in weight of reproductive organ, impaired fertility, growth and development of next generation was also observed in cyclophosphamide treated male rats (8). Although, the precise mechanism by which CP causes testicular toxicity is poorly understood, numerous studies have shown that CP exposure can disrupt the redox balance of tissues leading to oxidative stress (9-11). It has been reported that oxidative DNA damage is caused by hydroperoxide derivative of CP through generation of H₂O₂ (12). Also, acrolein has been found to interfere with the tissue antioxidant defense system and produces highly reactive oxygen free-radicals that are mutagenic to mammalian cells (13). Consequently, from these aforementioned

Corresponding Author: Ali Shalizar Jalali

Department of Basic Sciences, Faculty of Veterinary Medicine, University of Urmia, Urmia, Iran

Tel: +98 441 2770508, 911 1166004, Fax: +98 441 2771926, E-mail: ali_shalizar@yahoo.com; a.shalizar@mail.urmia.ac.ir

studies, combination of the drug delivery together with potent and safe antioxidant may be the appropriate approach to reduce CP-induced reproductive toxicity.

Hawthorn (*Crataegus*), found in northern temperate regions such as East Asia, Europe, and Eastern North America, is a genus of the Rosaceae family. The two most common species used are *Crataegus laevigata* (syn *Crataegus oxyacantha*) and *Crataegus monogyna*. Hawthorn was first mentioned as a drug in the Tang-Ben-Cao (659A.D.), which is the world's earliest officially published pharmacopoeia (14). Independent studies have showed that extracts of *Crataegus* (from several parts of the plant including fruits) are rich in proanthocyanidins and flavonoids (15,16). Many of these phenolic compounds have been shown to be cytoprotective by scavenging superoxide anion, hydroxyl radical, hydrogen peroxides and reducing lipid peroxidation (17-19). Based on above findings, the present study was undertaken to assess whether *Crataegus monogyna* fruits aqueous extract with antioxidant properties could serve as a protective agent against reproductive toxicity during CP treatment in a rat model.

Materials and Methods

Plant material

The ripe fruits of *Crataegus monogyna* were collected from its natural habitat around the city of Urmia in West Azerbaijan province, northwestern Iran. The identification of collected plants was confirmed scientifically at the research laboratories of the Department of Agriculture of West Azerbaijan province.

Preparation of the aqueous extract

After collection, the fruits were dried for 7–10 days in the shade at room temperature. The dried fruit were then ground, and the powder was stored in cloth bags at 5°C until transfer to the laboratory for extraction. The method for preparing dry water-soluble plant powders has been previously described (16). Briefly, dried plant material (25 g) was stirred in 250mL of distilled water for 15 min at 100°C, followed by rapid filtration through a crude cellulose filter and then Whatman#1 filter paper. The resulting filtrate was freeze-dried and the powder was stored at -18°C in a desiccant until required. The average (w/w) yield was 12.4%.

Animal model

Adult sexually mature male (4 months of age, weighing 177.75±7.68 g) albino rats of Wistar strain

were obtained from animal Resources Center of Veterinary Faculty of Urmia University. They were housed in a specific pathogen-free environment under standard conditions of temperature (25±2°C), relative humidity (50±10%) and light (12 h light/12 h dark). They were fed with a standard pellet diet and had free access to water. Animals were checked daily for occurrence of any toxic signs. All ethical themes of studies on animals were considered carefully, and the experimental protocol was approved by Institute Review Board.

Experimental protocol

After 7 days of acclimation to the environment, the rats were randomly divided into four groups consisting of six animals each ($n=6$) as described below according to the treatment they received; control group (Cont), *Crataegus* group (Cr), Cyclophosphamide group (CP) and Cyclophosphamide-*Crataegus* group (CPCr). The two experimental groups (CP and CPCr) were gavaged cyclophosphamide (Endoxan®, Baxter Oncology GmbH, Germany) at a dose of 5 mg in 5 ml saline/kg/day, which is in correspondence to the therapeutic dose. The controls were given a equivalent amount of distilled water. The (Cr) group was gavaged *Crataegus monogyna* aqueous extract at a dose of 20 mg/kg/day. The (CPCr) group also received the same dose of this extract four hours after cyclophosphamide administration. The treatment period was 28 days. The protocol for this study, including doses and duration of treatment for CP and *Crataegus*, were all designed according to previous studies (9,20).

Sampling

Animals were euthanized by CO₂ exposure in a specific device following anesthesia with Ketamine 24 hours after the last *Crataegus* treatment. Testes and epididymides were quickly dissected out, cleared of adhered connective tissue and weighed on a Mattler Basbal scale (Delta Range, Tokyo). Testes were fixed in Bouin's fixative (0.2% picric acid/2% (v/v) formaldehyde in PBS) for histological evaluation.

Histological analysis

After fixation of testes, they were directly dehydrated in a graded series of ethanol, cleared in xylol and embedded in paraffin wax. Thin sections (6 µm) perpendicular to the longest axis of the testis were cut using a microtome, stained with hematoxylin and eosin and examined using a light microscope.

Determination of histological parameters

For each testis, five vertical sections from the polar and the equatorial regions were sampled (21) and an unbiased numerical estimation of the following histological parameters was determined using a systematic random scheme.

Seminiferous tubules diameter (STsD) and germinal epithelium height (GEH)

For measuring of seminiferous tubule diameter and germinal epithelium height, 200 round or nearly round cross-sections of seminiferous tubules were randomly analyzed in each rat (one hundred per testis). Then, two perpendicular diameters of each cross-section of seminiferous tubules were measured using an ocular micrometer of light microscopy (Olympus Co., Germany) and their means were calculated. Also, germinal epithelium height was measured in 4 equidistance of each cross-section of seminiferous tubules and their means were calculated (22).

Cross-sectional area of the seminiferous tubules (A_c)

The cross-sectional area of the seminiferous tubules (A_c) was recorded using the equation $A_c = \pi D^2/4$, where π is equivalent to 3.142 and D the mean diameter of the seminiferous tubules (23).

Number of profiles of seminiferous tubules in a unit area of testis (N_A)

The number of profiles of seminiferous tubules per unit area (N_A) was estimated based on the principle of Gundersen (1977) (24) by using the unbiased counting frame (23).

Numerical density of seminiferous tubules (N_V)

The number of seminiferous tubules profiles per unit volume (N_V) was derived with the modified Floderus equation: $N_V = N_A / (D+T)$ (25) Where; N_A is the number of profiles per unit area, D is the diameter and T the average thickness of the section (23).

Sertoli cell index (SCI), repopulation index (RI) and miotic index (MI)

Sixty seminiferous tubules per group were randomly examined for the calculation of Sertoli cell index (SCI), repopulation index (RI) and miotic index (MI). SCI is the ratio of the number of germ cells to the number of Sertoli cells identified by a characteristic nucleus and nucleolus in all seminiferous tubules (26). RI is the percentage of

tubules populated with germ cells that had clearly reached the intermediate spermatogonial stage or later (27). MI, the number of round spermatids for each pachytene primary spermatocytes, was calculated for determination of cell loss percentage during cell division (28).

Leydig cell nuclear diameter (LCND) and Sertoli cell nuclear diameter (SCND)

These parameters were also determined using calibrated ocular micrometer as described by Elias and Hyde (29).

Statistical analysis

Results are expressed as mean \pm standard deviation (S.D). Differences between groups were assessed by the analysis of variance (ANOVA) using the SPSS software package for Windows. Statistical significance between groups was determined by Tukey multiple comparison posthoc test and the P -values less than 0.05 were considered to be statistically significant.

Results

Clinical signs and body and organ weight changes

All animals survived the experimental period. CP-treated animals showed general signs of deterioration such as piloerection, hair loss, lethargy, hunched posture, shivers and low activity. Body, testes, and epididymides weights were significantly decreased by cyclophosphamide treatment, while it was less decreased from controls with *Crataegus* coadministration. The absolute and relative weights of testes and epididymides were significantly lower than controls after cyclophosphamide treatment. Daily administration of *Crataegus* caused a significant increase in the absolute and relative weights of testes and absolute weight of epididymides of cyclophosphamide-*Crataegus* group in comparison with cyclophosphamide group, but relative weight of epididymides was not protected by *Crataegus* coadministration. Body, testes and epididymides weights, absolute and relative weights of testes and absolute weight of epididymides increased significantly in *Crataegus* group as compared to control (Table 1).

Histopathologic findings

CP induced drastic morphologic changes in the testis (Figure 1B).

Table 1. Effect of cyclophosphamide and *Crataegus monogyna* fruits aqueous extract on body weight and weights of testis and epididymis.

	Control	CP	<i>Crataegus</i>	CP + <i>Crataegus</i>
Final Body Weight (BW, g)	226.33±5.35	182.00±6.06 ^a	229.66±4.92 ^b	211.33±5.00 ^{a,b}
Absolute weight (g)				
Testes	2.01±0.065	1.49±0.040 ^a	2.14±0.017 ^{a,b}	1.81±0.043 ^{a,b}
Epididymides	1.15±0.044	0.85±0.010 ^a	1.21±0.023 ^{a,b}	1.01±0.037 ^{a,b}
Relative weight (per BW, %)				
Testes	0.88±0.011	0.82±0.004 ^a	0.93±0.014 ^{a,b}	0.85±0.008 ^{a,b}
Epididymides	0.50±0.019	0.46±0.023 ^a	0.52±0.010 ^b	0.47±0.017 ^a

The values are expressed as mean ± S.D. (n = 6). ^a Significant differences as compared with the control group at *P* < 0.05.

^b Significant differences as compared with the cyclophosphamide group at *P* < 0.05.

Atrophied seminiferous tubules showed severe hypocellularity (reduction in number of germ cells) and intraepithelial vacuolization. Rupture, vacuolization, vascular congestion, inflammatory cells infiltration, oedematous fluid accumulation and interstitial space widening were also observed in intertubular connective

tissue. In these specimens, Leydig cells were degenerated and appeared with pyknotic nuclei. Moreover, Sertoli cells lost their junction with germ cells and looked amorphous with irregular and smaller nuclei. Administration of *Crataegus* along with CP restored these changes towards normalcy (Figure 1D).

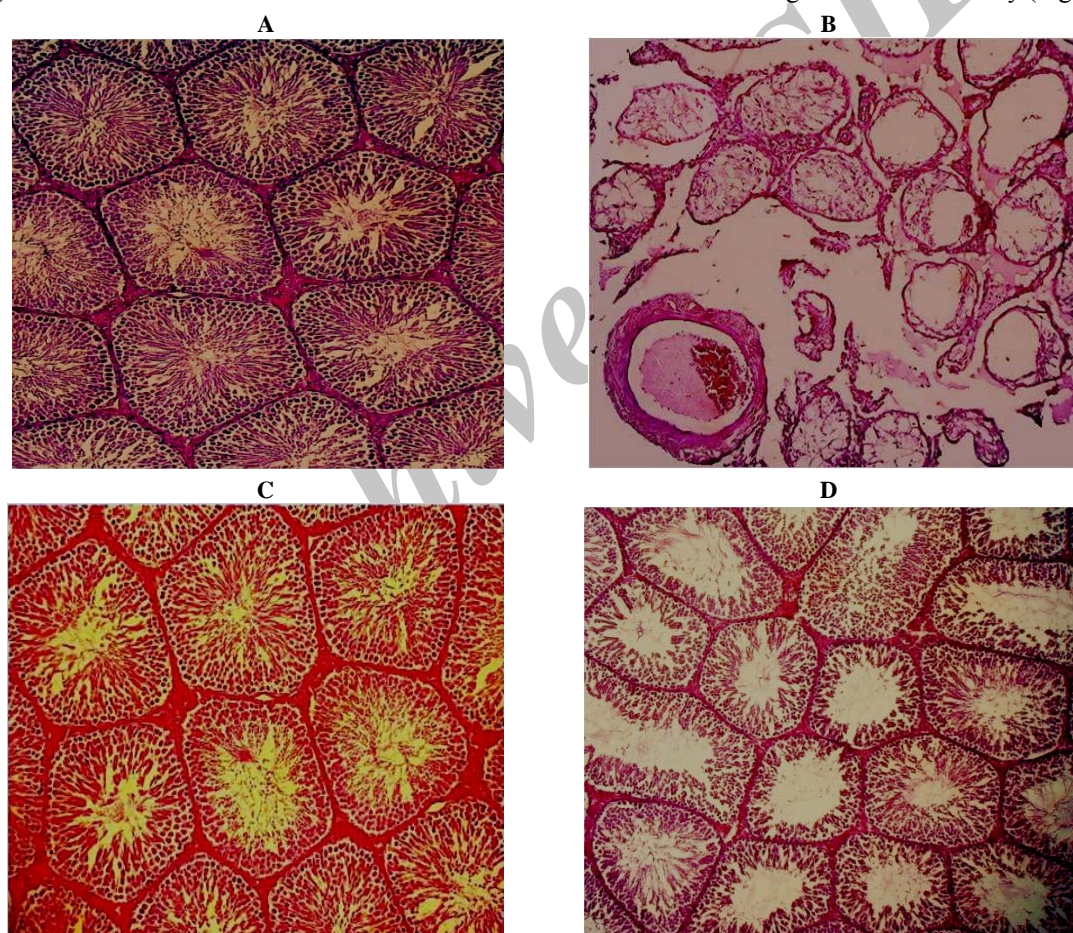


Figure 1. Photomicrographs of testicular sections of control (A), Cyclophosphamide (B), *Crataegus* (C) and Cyclophosphamide+*Crataegus* (D) treated rats. Testes from control (A) and *Crataegus*-treated (C) rats exhibit a normal feature of seminiferous epithelium and interstitial tissue with active spermatogenesis. However, a testis from a Cyclophosphamide treated rats (B) reveals markedly atrophied seminiferous tubules with severe hypocellularity and impaired spermatogenesis. Note Rupture, vacuolization, vascular congestion, oedematous fluid accumulation and interstitial space widening in intertubular connective tissue. *Crataegus* cotreated animals (D) display nearly normal histoarchitecture. Hematoxylin and eosin (×200).

Table 2. Effect of cyclophosphamide and *Crataegus monogyna* fruits aqueous extract on Sertoli cell index, repopulation index and mitotic index.

	Control	CP	<i>Crataegus</i>	CP + <i>Crataegus</i>
Sertoli cell index	25.22±0.85	4.50±0.17 ^a	25.17±1.36 ^b	18.53±0.89 ^{a,b}
Repopulation index	95.41±2.03	19.58±2.08 ^a	96.16±2.48 ^b	79.83±2.63 ^{a,b}
Mitotic index	2.11±0.027	0.98±0.013 ^a	2.05±0.014 ^{a,b}	1.64±0.008 ^{a,b}

The values are expressed as mean±S.D (n=6).

^a Significant differences as compared with the control group at $P<0.05$.

^b Significant differences as compared with the cyclophosphamide group at $P<0.05$.

Table 3. Effect of cyclophosphamide and *Crataegus monogyna* fruits aqueous extract on histological parameters of testis.

	Control	CP	<i>Crataegus</i>	CP + <i>Crataegus</i>
STsD (μm)	256.79±4.94	97.23±4.99 ^a	247.61±9.23 ^b	194.89±7.12 ^{a,b}
GEH (μm)	97.90±3.99	37.75±3.14 ^a	95.39±6.19 ^b	72.51±1.86 ^{a,b}
A_C ($\times 10^3 \mu\text{m}^3$)	51.81±2.00	7.44±0.76 ^a	48.21±3.60 ^b	29.86±2.18 ^{a,b}
N_A ($\times 10^{-8} \mu\text{m}^{-2}$)	33.93±2.96	9.73±0.54 ^a	34.00±2.50 ^b	22.06±1.17 ^{a,b}
N_V ($\times 10^{-10} \mu\text{m}^{-2}$)	12.91±1.16	9.43±0.55 ^a	13.41±1.05 ^b	11.00±0.92 ^{a,b}
LCND (μm)	6.32±0.48	3.48±0.27 ^a	6.49±0.54 ^b	5.02±0.42 ^{a,b}
SCND (μm)	9.22±0.75	6.44±0.53 ^a	9.45±0.37 ^b	8.98±0.45 ^b

STsD, seminiferous tubules diameter; GEH, germinal epithelium height; A_C , Cross-sectional area of the seminiferous tubules; N_A , Number of profiles of seminiferous tubules in a unit area of testis; N_V , Numerical Density of seminiferous tubules; LCND, Leydig cell nuclear diameter; SCND, Sertoli cell nuclear diameter. The values are expressed as mean±S.D (n=6).

^a Significant differences as compared with the control group at $P<0.05$.

^b Significant differences as compared with the cyclophosphamide group at $P<0.05$.

Histological parameters

As seen in Table 2, Cyclophosphamide treatment induced deletion of germ cells during spermatogenesis, which resulted in a dramatic decrease in SCI. Due to the germ cells deletion, the number of repopulated seminiferous tubules was greatly decreased in the CP-treated animals. CP treatment also caused considerable decrease in mitotic index. However, *Crataegus* coadministration significantly attenuated the CP-induced germ cell loss from seminiferous tubules.

The seminiferous tubules diameters (STsD) and their epithelial heights (GEH), Cross-sectional area of the seminiferous tubules (A_C), Number of profiles of seminiferous tubules in a unit area of testis (N_A) and Numerical Density of seminiferous tubules (N_V) as well as Leydig cell nuclear diameter (LCND) and Sertoli cell nuclear diameter (SCND) were reduced by CP treatment. CP-induced testicular damages were mitigated by *Crataegus* coadministration (Table 3).

Discussion

Many drugs used for cancer chemotherapy are known to produce toxic side-effects in multiple organ systems

including the testes. In a clinical context, testicular stem cell damage in patients exposed to chemotherapeutic drugs for a limited duration could result in long-term infertility or genetic alterations (30). A strategy to diminish the side-effects of anticancer drugs with preservation of their chemotherapeutic efficacy is necessary. Effective anticancer and immunosuppressive therapy with CP is severely limited by testicular toxicity as documented in a variety of species (4). An oxidant mechanism may be involved in the reproductive toxicity, wherein CP and its metabolite acrolein cause inactivation of microsomal enzymes and result in increased reactive oxygen species generation and lipid peroxidation (31). In the present study, reduction in body weight, weight of the testis and epididymis and histological changes in testis were indicative of drug toxicity. Because the weight of the testis largely depends on the mass of the differentiated spermatogenic cells (32), the marked reduction in organ weight by CP can be explained by diminished number of germ cells, atrophy of Leydig cells and a significant lower rate of spermatogenesis as confirmed by our findings. Chemotherapy can result in long-term or permanent azoospermia, the mechanism of which is most likely the

death of germ cells (33) and stereological parameters such as seminiferous tubules diameters and their epithelial heights, cross-sectional area of the seminiferous tubules, number of profiles of seminiferous tubules in a unit area of testis and numerical density of seminiferous tubules can also give information about the testicular damage degree as a consequence of germ cell death. In general, massive germ cell loss caused by anticancer drugs is followed by a sharp decline in testicular stereological parameters (34). As shown in present study, depletion of seminiferous epithelium and the consequent decrease of morphometric and stereological measurements caused by cytotoxic agents were confirmed in our report.

Increased generation of free radicals is one of the possible mechanisms involved in CP-induced Leydig cell degeneration resulted in reduced availability of androgens (35). Structural development and maturation of germ cells and spermiation are important functions of Sertoli cells (36). Therefore, a potential explanation for the failure of spermatogenesis in the CP-treated males is disruption of androgen-dependent junction of Sertoli cells with germ cells leading to their disorganization and separation. There are several reports on the benefit of antioxidants in protecting male reproductive system from deleterious effects of reactive oxygen species and other free radicals generated during CP exposure. It was found that ascorbic acid reduces cyclophosphamide-induced reproductive toxicity (9) as well as alpha-tocopherol-succinate (37). There is also evidence that Yukmijihwang-tang as a multi-herbal medicinal formula can improve reproductive toxicity of CP through reduction of oxidative stress (38). Two studies from the same researchers indicated that supplementation with lipoic acid as an antioxidant reduces CP-induced reproductive toxicity by the same mechanism (39,40). In the present study, it has been shown that *Crataegus monogyna* fruits aqueous extract coadministration was effective in protection or attenuation of testicular damage following CP exposure. Increasing evidence support the fact that *Crataegus* is beneficial where free radicals are known to play a predominant role in toxicity. Previous studies have shown hawthorn extract reduced the stress conditions and genotoxicity induced by cyclophosphamide in mouse bone marrow cells due to its strong antioxidant activity (41). Furthermore, it has been revealed that hawthorn extract reduces infarct volume and improves neurological score by reducing oxidative stress in rat brain (42). In conclusion, the finding of our study indicate that cyclophosphamide can adversely damage the testicular tissue through imposing

oxidative stress, while *Crataegus monogyna* fruits aqueous extract co-administration could effectively prevent these adverse effects by effective inhibiting of oxidative processes and efficient scavenging of free radicals.

References

1. Dollery C, editor. Therapeutic Drugs. 2nd ed. Edinburgh: Churchill Livingstone; 1999. p. 349-54.
2. Ludeman SM. The chemistry of the metabolites of cyclophosphamide. *Curr Pharm Des* 1999;5(8):627-43.
3. Kern JC, Kehrer JP. Acrolein-induced cell death: a caspase-influenced decision between apoptosis and oncosis/necrosis. *Chem Biol Interact* 2002;139(1):79-95.
4. Anderson D, Bishop JB, Garner RC, Ostrosky-Wegman P, Selby PB. Cyclophosphamide: review of its mutagenicity for an assessment of potential germ cell risks. *Mutat Res* 1995;330(1-2):115-81.
5. Howell S, Shalet S. Gonadal damage from chemotherapy and radiotherapy. *Endocrinol Metab Clin North Am* 1998;27(4):927-43.
6. Meistrich ML, Parchuri N, Wilson G, Kurdoglu B, Kangasniemi M. Hormonal protection from cyclophosphamide-induced inactivation of rat stem spermatogonia. *J Androl* 1995;16(4):334-41.
7. Kaur F, Sangha GK, Bilaspuri GS. Cyclophosphamide-induced structural and biochemical changes in testis and epididymidis of rats. *Indian J Exp Biol* 1997;35(7):771-5.
8. Trasler JM, Hales BF, Robaire B. Chronic low dose cyclophosphamide treatment of adult male rats: effect on fertility, pregnancy outcome and progeny. *Biol Reprod* 1986;34(2):275-83.
9. Das UB, Mallick M, Debnath JM, Ghosh D. Protective effect of ascorbic acid on cyclophosphamide- induced testicular gametogenic and androgenic disorders in male rats. *Asian J Androl* 2002;4(3):201-7.
10. Ghosh D, Das UB, Ghosh S, Mallick M, Debnath J. Testicular gametogenic and steroidogenic activities in cyclophosphamide treated rat: a correlative study with testicular oxidative stress. *Drug Chem Toxicol* 2002;25(3):281-92.
11. Manda K, Bhatia AL. Prophylactic action of melatonin against cyclophosphamide-induced oxidative stress in mice. *Cell Biol Toxicol* 2003;19(6):367-72.
12. Murata M, Suzuki T, Midorikawa K, Oikawa S, Kawanishi S. Oxidative DNA damage induced by a hydroperoxide derivative of cyclophosphamide. *Free Radic Biol Med* 2004;37(6):793-802.
13. Arumugam N, Sivakumar V, Thanislass J, Devaraj H. Effects of acrolein on rat liver antioxidant defense system. *Indian J Exp Biol* 1997;35(12):1373-4.

14. Yao M, Ritchie HE, Brown-Woodman PD. A reproductive screening test of hawthorn. *J Ethnopharmacol* 2008;118(1):127-32.
15. Bahorun T, Gressier B, Troitin F, Brunet C, Dine T, Luyckx M, Vasseur J, Cazin M, Cazin JC, Pinkas M. Oxygen species scavenging activity of phenolic extracts from hawthorn fresh plant organs and pharmaceutical preparations. *Arzneimittelforschung* 1996;46(11):1086-9.
16. Ljubuncic P, Azaizeh H, Portnaya I, Cogan U, Said O, Saleh KA, Bomzon A. Antioxidant activity and cytotoxicity of eight plants used in traditional Arab medicine in Israel. *J Ethnopharmacol* 2005;99(1):43-7.
17. Bahorun T, Troitin F, Pommery J, Vasseur J, Pinkas M. Antioxidant activities of *Crataegus monogyna* extracts. *Planta Med* 1994;60(4):323-8.
18. Zhang Z, Chang Q, Zhu M, Huang Y, Ho WK, Chen Z. Characterization of antioxidants present in hawthorn fruits. *J Nutr Biochem* 2001;12(3):144-152.
19. Rice-Evans C. Flavonoids and isoflavones: absorption, metabolism, and bioactivity. *Free Radic Biol Med* 2004;36(7):827-8.
20. Khalil R, Abuharfeil N, Shabsoug B. The effect of *Crataegus aronica* aqueous extract in rabbits fed with high cholesterol diet. *European J Sci Res* 2008;22(3):352-60.
21. Qin DN, Lung MA. Morphometric study on leydig cells in capsulotomized testis of rats. *Asian J Androl* 2002;4(1):49-53.
22. Vendramini V, Sasso-Cerri E, Miraglia SM. Amifostine reduces the seminiferous epithelium damage in doxorubicin-treated prepubertal rats without improving the fertility status. *Reprod Biol Endocrinol* 2010;8:3.
23. Gundersen HJ, Jensen EB. The efficiency of systematic sampling in stereology and its prediction. *J Microsc* 1987;147(Pt 3):229-63.
24. Gundersen HJG. Notes on the estimation of the numerical density of arbitrary profiles: the edge effect. *J Microsc* 1977;111:219-23.
25. Gilliland KO, Freel CD, Lane CW, Fowler WC, Costello MJ. Multilamellar bodies as potential scattering particles in human age-related nuclear cataracts. *Mol Vis* 2001;7:120-30.
26. Russell LD, Ettlin R, Sinha Hikim AP, Clegg ED, editors. *Histological and Histopathological Evaluation of the Testis*. Clearwater, FL: Cache River Press; 1990.
27. Meistrich ML, van Beek MEAB. Spermatogonial stem cells: assessing their survival and ability to produce differentiated cells. *Methods Toxicol* 1993;3A:106-23.
28. Kheradmand A, Dezfoulian O, Tarrahi MJ. Ghrelin attenuates heat-induced degenerative effects in the rat testis. *Regul Pept* 2011;167(1):97-104.
29. Elias H, Hyde DM. An elementary introduction to stereology (quantitative microscopy). *Am J Anat* 1980;159(4):412-46.
30. Sawada T, Tamada H, Mori J. Secretion of testosterone and epidermal growth factor in mice with oligozoospermia caused by doxorubicin hydrochloride. *Andrologia* 1994;26(3):151-3.
31. Lear L, Nation RL, Stupans I. Effects of cyclophosphamide and adriamycin on rat hepatic microsomal glucuronidation and lipid peroxidation. *Biochem Pharmacol* 1992;44(4):747-53.
32. Katoh C, Kitajima S, Saga Y, Kanno J, Horii I, Inoue T. Assessment of quantitative dual-parameter flow cytometric analysis for the evaluation of testicular toxicity using cyclophosphamide- and ethinylestradiol-treated rats. *J Toxicol Sci* 2002;27(2):87-96.
33. Meistrich ML. Relationship between spermatogonial stem cell survival and testis function after cytotoxic therapy. *Br J Cancer Suppl* 1986;7:89-101.
34. Franca LR, Russell LD. The testis of domestic animals. In: Regadera J, Martinez-Garcia F, editors. *Male Reproduction: A Multidisciplinary Overview*. Madrid, Spain: Churchill Livingstone; 1998. p. 198-219.
35. Debnath D, Mandal TK. Study of quinalphos (an environmental oestrogenic insecticide) formulation (Ekalux 25 E.C.)-induced damage of the testicular tissues and antioxidant defence systems in Sprague-Dawley albino rats. *J Appl Toxicol* 2000;20(3):197-204.
36. Mruk DD, Cheng CY. Sertoli-Sertoli and Sertoli-germ cell interactions and their significance in germ cell movement in the seminiferous epithelium during spermatogenesis. *Endocr Rev* 2004;25(5):747-806.
37. Ghosh D, Das UB, Misro M. Protective role of alpha-tocopherol-succinate (provitamin-E) in cyclophosphamide induced testicular gametogenic and steroidogenic disorders: a correlative approach to oxidative stress. *Free Radic Res* 2002;36(11):1209-18.
38. Oh MS, Chang MS, Park W, Kim do R, Bae H, Huh Y, Park SK. Yukmijihwang-tang protects against cyclophosphamide-induced reproductive toxicity. *Reprod Toxicol* 2007;24(3-4):365-70.
39. Selvakumar E, Prahalthan C, Sudharsan PT, Varalakshmi P. Chemoprotective effect of lipoic acid against cyclophosphamide-induced changes in the rat sperm. *Toxicology* 2006;217(1):71-8.
40. Selvakumar E, Prahalthan C, Sudharsan PT, Varalakshmi P. Protective effect of lipoic acid on cyclophosphamide-induced testicular toxicity. *Clin Chim Acta* 2006;367(1-2):114-9.

Crataegus monogyna aqueous extract

41. Hosseinimehr SJ, Azadbakht M, Abadi AJ. Protective effect of hawthorn extract against genotoxicity induced by cyclophosphamide in mouse bone marrow cells. *Environ Toxicol Pharmacol* 2008;25(1):51-6.
42. Elango C, Jayachandaran KS, Niranjali Devaraj S. Hawthorn extract reduces infarct volume and improves neurological score by reducing oxidative stress in rat brain following middle cerebral artery occlusion. *Int J Dev Neurosci* 2009;27(8):799-803.

Archive of SID