

# Single-Segment and Double-Segment INTACS for Post-LASIK Ectasia

Hassan Hashemi<sup>1</sup>, Ali Gholaminejad<sup>1</sup>, Kazem Amanzadeh<sup>1</sup>,

Maryam Hashemi<sup>2</sup>, and Mehdi Khabazkhoob<sup>3</sup>

<sup>1</sup> Noor Ophthalmology Research Center, Noor Eye Hospital, Tehran, Iran

<sup>2</sup> Department of Medicine, Tehran University of Medical Sciences, Tehran, Iran

<sup>3</sup> Department of Epidemiology, Faculty of Public Health, Shahid Beheshti University of Medical Sciences, Tehran, Iran

Received: 8 Mar. 2013; Accepted: 8 Oct. 2013

**Abstract-** The objective of the present study was to compare single segment and double segment INTACS rings in the treatment of post-LASIK ectasia. In this interventional study, 26 eyes with post-LASIK ectasia were assessed. Ectasia was defined as progressive myopia regardless of astigmatism, along with topographic evidence of inferior steepening of the cornea after LASIK. We excluded those with a history of intraocular surgery, certain eye conditions, and immune disorders, as well as monocular, pregnant and lactating patients. A total of 11 eyes had double ring and 15 eyes had single ring implantation. Visual and refractive outcomes were compared with preoperative values based on the number of implanted INTACS rings. Pre and postoperative spherical equivalent were  $-3.92$  and  $-2.29$  diopter ( $P=0.007$ ). The spherical equivalent decreased by  $1 \pm 3.2$  diopter in the single-segment group and  $2.56 \pm 1.58$  diopter in the double-segment group ( $P=0.165$ ). Mean preoperative astigmatism was  $2.38 \pm 1.93$  diopter which decreased to  $2.14 \pm 1.1$  diopter after surgery ( $P=0.508$ );  $0.87 \pm 1.98$  diopter decrease in the single-segment group and  $0.67 \pm 1.2$  diopter increase in the double-segment group ( $P=0.025$ ). Nineteen patients (75%) gained one or two lines, and only three, who were all in the double-segment group, lost one or two lines of best corrected visual acuity. The spherical equivalent and vision significantly decreased in all patients. In these post-LASIK ectasia patients, the spherical equivalent was corrected better with two segments compared to single segment implantation; nonetheless, the level of astigmatism in the single-segment group was significantly better than that in the double-segment group.

© 2014 Tehran University of Medical Sciences. All rights reserved.

*Acta Medica Iranica*, 2014;52(9):681-686.

**Keywords:** INTACS ring; LASIK; Ectasia; Myopia

## Introduction

Keratoconus, pellucid marginal degeneration, and post-LASIK ectasia are structural abnormalities of the cornea and are first identified with changes in the corneal topography (1-2). Keratoconus is of special importance as the head of these anomalies; however, since refractive surgery is increasing globally, post-refractive surgery ectasia is especially important too. Among different refractive procedures, the most common ectasia is seen after LASIK, especially in cases of high myopia (3-5).

The complication is reported from 0.01% to 1%. The first complaint of these patients who refer for refractive correction is the need for glasses or contact lenses. Although the exact cause of post-LASIK ectasia is still unknown, a number of studies consider it multifactorial,

and it is mainly attributed to thin cornea and a residual corneal bed thickness less than  $250\mu\text{m}$  (5-7). Since post-LASIK ectasia is progressive in most patients, glasses and contact lenses may not be able to correct vision of these patients very well, and in some cases, corneal transplantation is the final resort. Other options suggested to patients before corneal grafting include collagen cross-linking and intracorneal ring segment implantation.

The use of intrastromal corneal ring for the treatment of keratoconus has been reported in many studies (8-11), but reports on application of intrastromal corneal ring in the treatment of post-LASIK ectasia are limited (12-15). Considering the importance of ring implantation, we designed this study to compare results of single vs. double ring implantation. Here we present the visual and refractive outcomes of patients after single and double ring implantation.

**Corresponding Author:** M. Khabazkhoob

Department of Epidemiology, Faculty of Public Health, Shahid Beheshti University of Medical Sciences, Tehran, Iran  
Tel: +98 21 82401615, Fax: +98 21 82401609, E-mail address: khabazkhoob@yahoo.com

## Materials and Methods

In this interventional study, we enrolled 26 eyes of patients with ectasia as a result of LASIK. A total of 13 eyes belonged to male patients. The mean age of the patients was  $35.9 \pm 11.9$  (range, 26- 68 years).

### Inclusion and exclusion criteria

Authors enrolled patients with progressive myopia with or without increasing astigmatism and progressive corneal steepening, with or without corneal thinning in the central or paracentral cornea and topographic evidence of progressive inferior corneal steepening as the definition of ectasia in participants who had LASIK. Exclusion criteria were a history of intraocular or corneal surgery, vernal eye dryness, herpetic keratitis, collagen vascular disease or immune disorders, pregnancy, being lactating, and monocular.

### Surgical technique

We used topical anesthesia in these patients. First, the geometric center was defined using an 11 mm zone marker, and the incision site was determined according to the location of cone and perpendicular to the steep meridian. The incision was made using a 1.5mm diamond knife, cutting the cornea down to a depth of 65% of the thickness.

After creating the stromal canal, the segments were inserted in the canal, and the incision site was closed with 10 nylon stitch. INTACS were placed in the 7mm zone.

The incision was made where the middle part of the ring bisected the site after ring implantation. Therefore, the incision was made in the flat axis in most cases in our study and our reference in this study was not the steep axis.

The number of INTACS segments was based on the patients' topography. Also, authors used a single ring in patients with astigmatism more than three. In participants with a central cone, symmetric rings were used. A single stitch was made at the incision site which was removed four to six weeks later.

### Examinations

Measurement of UCVA, BCVA, manifest refraction, and keratometry was performed for patients before and after surgery. In addition to these examinations, authors assessed complications occurring during or after surgery.

Minimum keratometry (min-K), maximum keratometry (max-K) and central corneal thickness were

measured using Pentacam HR (oculus, wetzeler, Germany).

In addition to these examinations, we assessed complications occurring during or after surgery. Postoperative examinations were scheduled for the 1st postoperative week, and then at 1, 3, 6, and 12 months. The mean follow-up time was  $11.2 \pm 2.3$  months (8-15 months).

### Statistical analysis

In this study, the authors used the SPSS software version 11.5 for data analyses. Qualitative variables were summarized as their mean, standard deviation, and range before and after surgery. Comparison of pre and postoperative values was performed using the paired t-tests, and surgical outcomes in two groups were compared using the analysis of covariance. In this analysis, the postoperative variable was considered as the dependant variable, and the preoperative variable as the covariate. Safety was defined as the ratio of postoperative to preoperative corrected vision and showed in terms of lost or gained lines of BCVA after surgery compared to before surgery. Efficacy, based on UCVA was defined as the ratio of postoperative UCVA to the preoperative BCVA.

## Results

### Manifest refraction spherical equivalent

Table 1 presents results of patients' spherical equivalent before and after surgery in the two groups. Overall, the mean preoperative spherical equivalent of -3.92 diopter changed to -2.29 diopter after surgery ( $P=0.007$ ). Figure 1 Shows distribution of patients' spherical equivalent before and after surgery. According to postoperative refraction results, the mean decrease in spherical equivalent was  $1 \pm 3.2$  diopter in the single-segment group and  $2.56 \pm 1.58$  diopter in the double-segment group ( $P=0.165$ ).

### Manifest refraction cylinder

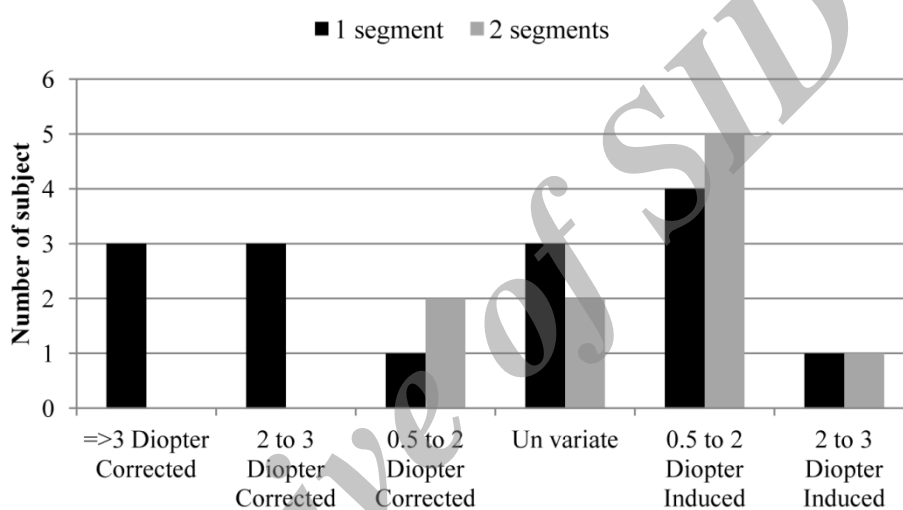
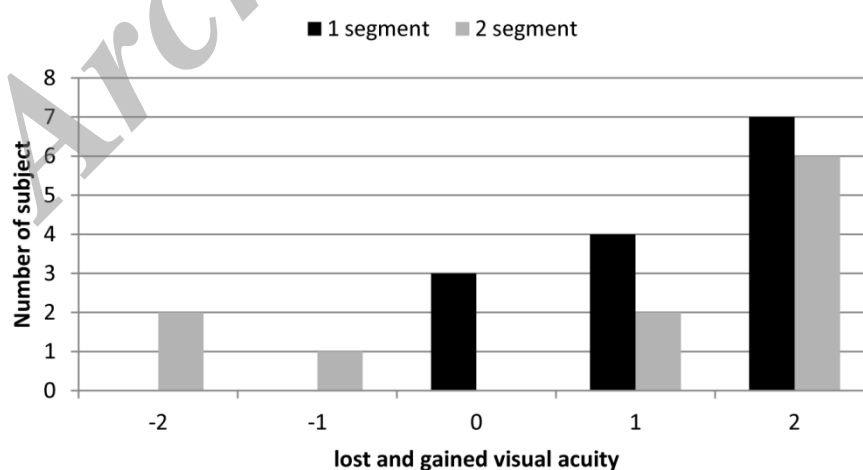
Mean astigmatism refraction was  $2.38 \pm 1.93$  diopter before surgery and reduced to  $2.14 \pm 1.1$  diopter after surgery ( $P=0.508$ ). Based on the number of implanted rings, astigmatism results were significantly better in those implanted with a single ring. Mean astigmatism decreased by  $0.87 \pm 1.98$  diopter with single ring implantation while those with double segment implantation showed an increase of  $0.67 \pm 1.2$  diopter compared to preoperative values ( $P=0.025$ ). Two people in the single segment group had induced astigmatism of 1.5 diopter.

**Table 1. Patient data before and after surgery in the single-segment and double-segment groups**

	1 segment		2 segments	
	Preop Mean $\pm$ SD	Postop Mean $\pm$ SD	Preop Mean $\pm$ SD	postop Mean $\pm$ SD
<b>Sphere</b>	-2.30 $\pm$ 2.21	-1.73 $\pm$ 2.84	-3.30 $\pm$ 1.07	-0.52 $\pm$ 1.28
<b>Cylinder</b>	-3.00 $\pm$ 2.07	-2.13 $\pm$ 1.16	-1.45 $\pm$ 1.30	-2.16 $\pm$ 1.09
<b>Spherical equivalent</b>	-3.80 $\pm$ 2.73	-2.80 $\pm$ 3.16	-4.10 $\pm$ 1.45	-1.60 $\pm$ 1.53
<b>UCVA*</b>	0.93 $\pm$ 0.64	0.34 $\pm$ 0.27	1.14 $\pm$ 0.95	0.35 $\pm$ 0.28
<b>BCVA†</b>	0.42 $\pm$ 0.35	0.17 $\pm$ 0.15	0.29 $\pm$ 0.17	0.19 $\pm$ 0.10

\*Uncorrected visual acuity

† Best corrected visual acuity

**Figure 1.** Amount of corrected or induced astigmatism in the single-segment and double-segment groups**Figure 2.** Postoperative lost and gained Snellen lines of best corrected visual acuity in the single-segment and double-segment groups

The mean corneal astigmatism was 3.19 and 2.57 D before and after implanting the single-segment INTACS

and 1.95 and 0.92 D before and after implanting the double-segment INTACS, respectively. There was no

significant difference in corneal astigmatism changes between the two groups ( $P=0.991$ ).

### Visual acuity

Current results indicated a mean pre and postoperative UCVA of 1.02 and 0.35, respectively, which indicated a 0.67 LogMAR improvement after surgery ( $P<0.001$ ). Preoperatively, 25 patients (96.1%) had UCVA worse than 20/40, and this was seen in only 8 patients (30%) after surgery. Mean BCVA was 0.37 LogMAR before surgery and improved to 0.18 LogMAR after surgery ( $P=0.003$ ).

Figure 2 shows gain and loss of BCVA in the two groups; overall 19 patients (75%) gained 1 or 2 lines, and 3 patients lost at least one line of corrected vision compared to their preoperative vision. Three patients who lost BCVA had two segments implanted. According to UCVA and BCVA data on the final visit, the efficacy index was  $1.60 \pm 1.76$ , and the safety index was  $0.84 \pm 1.25$ . The inter-group difference in terms of the decrease in UCVA and BCVA was not significant; mean UCVA increase was 0.42 and 0.79 LogMAR in the single-segment and double-segment groups, respectively ( $P=0.237$ ). For BCVA, these values were 0.25 and 0.1 LogMAR ( $P=0.201$ ).

## Discussion

Literature contains several studies on the results of implanting INTACS in keratoconus patients (8-10, 16-19). Nonetheless, reports concerning INTACS implantation in patients with post-LASIK ectasia are found less. Here we studied visual and refractive outcomes and compared results of single vs. double segment implantation of INTACS. Results of single and double segment INTACS implantation in post-LASIK ectasia have been studied by Alio *et al.*, (20) and Sharma and Boxer (1). The study by Alio *et al.*, (20) is not a comparative one, but Sharma (1) compares results of single vs. double segment implantation of INTACS in post-LASIK ectasia. As showed in results, the spherical equivalent and vision were the two main variables that changed in the present study, and improved after INTACS implantation.

### Spherical equivalent

In this study, the spherical equivalent decreased by 1.63 diopter compared to the preoperative value. The decrease in the single-segment group and double-segment group was 1 and 2.56 diopter, respectively. Comparing single-segment and double-segment

INTACS implantation in terms of decreasing myopia, Shrama reported a change in the spherical equivalent of 1.45 diopter and 2.26 diopter in these two groups, respectively (1). Kymionis *et al.*, (21) used single-segment INTACS implantation for the treatment of post-LASIK ectasia and reported a change in the spherical from a preoperative -4.81 diopter to a postoperative -0.96 diopter. Alio *et al.*, (22) observed a decrease in the spherical equivalent from -5 to -1.73 diopter in the single-segment group, and improvement from -5.5 to -3.25 diopter in their double-segment patients. Pokroy *et al.* (23) reported a decrease in the spherical equivalent from -1.6 diopter preoperatively to -0.8 diopter after implanting one segment INTACS. The authors found no significant difference between single and double segment implantation in terms of spherical equivalent results, and nor did Sharma (23); however, results of these two studies indicate more spherical equivalent improvement in the double segment group. In general, the overall flattening effect appears to be greater with two ring segments, and thus more improvement in the spherical equivalent is expected with double segment compared to single segment implantation.

### Astigmatism

In terms of astigmatic correction, the present study found no significant change between the preoperative and postoperative astigmatism. However, based on the number of implanted segments, results were significantly better in those with a single segment. In a study by Pokroy *et al.*, (23) who implanted a single segment, a change from -3.9 to -2.46 was observed. Comparing single-segment and double-segment INTACS implantation, Sharma *et al.*, (1) reported a 1.62 diopter decrease in the single-segment group while the astigmatic reduction in the double-segment group was 0.51 diopter. In a study by Alio *et al.*, (22) the amount of astigmatism in the single-segment group change from 5.36 to 2.89 diopter during the first year, and in the double segment group, the preoperative value was 4.65 which changed to 2.26 after surgery. Similarly, in most studies (23-24) with keratoconus patients, results in terms of astigmatism are more favorable with single-segment implantation.

The reason could be that in patients with keratoconus and post-LASIK ectasia, cone appears in the area, and implanting a single segment in this steep area causes it to become flatter. Therefore, astigmatic changes in this group can be because of more flattening of the corneal surface. Rabinowitz believes implanting a single segment in the inferior or superior cornea (depending on

the cone location) corrects the asymmetry (25).

### Safety

Current findings showed a significant overall improvement in the UCVA and BCVA in all patients except three who lost at least one line of corrected vision. The inter-group difference in this regard was not significant. However, the authors had no participant with decreased BCVA in the single-segment group, while three patients in the double-segment group lost one to three lines of BCVA. Similarly, Sharma and Boxer (1) observed a significantly better BCVA and UCVA in their single-segment group, and Pokroy *et al.*, (23) reported no loss of BCVA in five patients who had a single segment implanted. Considering better astigmatic changes in the single-segment group and that we even observed induced astigmatism in the double-segment group, the reduction in BCVA in the double-segment group can mainly be attributed to the induced astigmatism in this group.

The spherical equivalent and vision significantly improved in participants of this study. In these post-LASIK ectasia patients, the spherical equivalent was corrected better with two segments compared to single segment implantation; nonetheless, astigmatic correction in the single-segment group was significantly better than that in the double-segment group.

### References

- Sharma M, Boxer Wachler BS. Comparison of single-segment and double-segment Intacs for keratoconus and post-LASIK ectasia. *Am J Ophthalmol* 2006;141(5):891-5.
- Binder PS, Lindstrom RL, Stulting RD, et al. Keratoconus and corneal ectasia after LASIK. *J Cataract Refract Surg* 2005;31(11):2035-2038.
- Geggel HS, Talley AR. Delayed onset keratectasia following laser in situ keratomileusis. *J Cataract Refract Surg* 1999;25(4):582-6.
- Amoils SP, Deist MB, Gous P, et al. Iatrogenic keratectasia after laser in situ keratomileusis for less than -4.0 to -7.0 diopters of myopia. *J Cataract Refract Surg* 2000;26(7):967-77.
- Randleman JB, Russell B, Ward MA, et al. Risk factors and prognosis for corneal ectasia after LASIK. *Ophthalmology* 2003;110(2):267-275.
- Ertan A, Karacal H. Factors influencing flap and INTACS decentration after femtosecond laser application in normal and keratoconic eyes. *J Refract Surg* 2008;24(8):797-801.
- Twa MD, Nichols JJ, Joslin CE, et al. Characteristics of corneal ectasia after LASIK for myopia. *Cornea* 2004;23(5):447-57.
- Khan MI, Injarie A, Muhtaseb M. Intrastromal corneal ring segments for advanced keratoconus and cases with high keratometric asymmetry. *J Cataract Refract Surg* 2012;38(1):129-36.
- Kubaloglu A, Sari ES, Cinar Y, et al. Intrastromal corneal ring segment implantation for the treatment of keratoconus. *Cornea* 2011;30(1):11-7.
- Sansanayudh W, Bahar I, Kumar NL, et al. Intrastromal corneal ring segment SK implantation for moderate to severe keratoconus. *J Cataract Refract Surg* 2010;36(1):110-3.
- Daxer A, Mahmoud H, Venkateswaran RS. Intracorneal continuous ring implantation for keratoconus: One-year follow-up. *J Cataract Refract Surg* 2010;36(8):1296-302.
- Tunc Z, Helvacioğlu F, Sencan S. Evaluation of intrastromal corneal ring segments for treatment of post-LASIK ectasia patients with a mechanical implantation technique. *Indian J Ophthalmol* 2011;59(6):437-43.
- Tomita M, Inoue N, Tsuru T. Treatment of keratoectasia after LASIK by intrastromal corneal ring segments in two patients who had no preoperative risk factors. *Clin Ophthalmol* 2010;4(7):785-791.
- Pinero DP, Alio JL, Uceda-Montanes A, et al. Intracorneal ring segment implantation in corneas with post-laser in situ keratomileusis keratectasia. *Ophthalmology* 2009;116(9):1665-74.
- Uceda-Montanes A, Tomas JD, Alio JL. Correction of severe ectasia after LASIK with intracorneal ring segments. *J Refract Surg* 2008;24(4):408-11.
- Ramirez-Miranda A, Gomez-Bastar A, Navas A. Keratoconus correction using intrastromal corneal ring segments and posterior chamber phakic intraocular lens implantation. *J Cataract Refract Surg* 2011;37(7):1373-4.
- Khan MI, Muhtaseb M. Intrastromal corneal ring segments for bilateral keratoconus in an 11-year-old boy. *J Cataract Refract Surg* 2011;37(1):201-5.
- Kaya V, Utine CA, Karakus SH, et al. Refractive and visual outcomes after Intacs vs ferrara intrastromal corneal ring segment implantation for keratoconus: a comparative study. *J Refract Surg* 2011;27(12):907-12.
- Alfonso JF, Lisa C, Fernandez-Vega L, Madrid-Costa D, et al. Intrastromal corneal ring segments and posterior chamber phakic intraocular lens implantation for keratoconus correction. *J Cataract Refract Surg* 2011;37(4):706-13.
- Alio J, Salem T, Artola A, et al. Intracorneal rings to correct corneal ectasia after laser in situ keratomileusis. *J Cataract Refract Surg* 2002;28(9):1568-74.
- Kymionis GD, Siganos CS, Kounis G, et al. Management of post-LASIK corneal ectasia with Intacs inserts: one-year

## Single-segment and double-segment INTACS

- results. Arch Ophthalmol 2003;121(3):322-6.
22. Alio JL, Artola A, Hassanein A, et al. One or 2 Intacs segments for the correction of keratoconus. J Cataract Refract Surg 2005;31(5):943-53.
23. Pokroy R, Levinger S, Hirsh A. Single Intacs segment for post-laser in situ keratomileusis keratectasia. J Cataract Refract Surg 2004;30(8):1685-95.
24. Abad JC, Arango J, Tobon C. Comparison of astigmatism correction using shorter arc length 90 degrees /120 degrees asymmetric intacs severe keratoconus versus 150 degrees single-segment intacs severe keratoconus in asymmetric keratoconus. Cornea 2011;30(11):1201-6.
25. Rabinowitz YS. Intacs for keratoconus. Curr Opin Ophthalmol 2007;18(4):279-83.

Archive of SID