

# Thyroid Hemiagenesis Associated with Retrosternal Nodular Goiter: a Case Report

Turkay Kirdak, Baris Gulcu, and Nusret Korun

Department of Surgery, Faculty of Medicine, Uludag University, Bursa, Turkey

Received: 27 Jun. 2013; Accepted: 19 Nov. 2013

**Abstract-** Thyroid hemiagenesis can be associated with various thyroid pathologies such as papillary thyroid cancer or nodular goiter. However, we did not encounter any publication in the literature in which hemiagenesis could be observed together with retrosternal goiter. In this report, a thyroid hemiagenesis associated with a benign nodular goiter extending retrosternally is reported. A 59-year-old male patient presented to the surgery clinic because of swelling in the neck. A mass was observed in the right thyroid lobe extending to the retrosternal region. On ultrasonography, a nodule in the right thyroid lobe measuring 63 mm was determined, which was extended retrosternally. However, the left lobe of the thyroid could not be visualized. Scintigraphy and Computerized Tomography confirmed hemiagenesis. Total thyroidectomy was performed without sternotomy. In conclusion, thyroid hemiagenesis can be associated with a retrosternally located nodular goiter.

© 2014 Tehran University of Medical Sciences. All rights reserved.

*Acta Medica Iranica*, 2014;52(9):725-727.

**Keywords:** Thyroid hemiagenesis; Retrosternal goiter; thyroidectomy; Case report

## Introduction

Thyroid hemiagenesis is a rare congenital abnormality in which one of the thyroid lobes is not developed. Since the thyroid functions in thyroid hemiagenesis are generally normal, its exact frequency is not known, and it is generally detected incidentally. On ultrasonographic screenings of normal children, its prevalence has been determined as 0.05%. Agenesis is generally found on the left side, and the isthmus is absent in 44% of cases. The female / male ratio is 1 / 1.4 (1,2).

In recent years, about 300 cases related with thyroid hemiagenesis have been reported in the literature (3). Hemiagenesis can be seen together with various thyroid dysfunctions such as papillary cancer, nodular goiter, and thyroiditis (2,4,5). To our knowledge there were not any publications in the literature about the association of hemiagenesis with retrosternal goiter. In this report, we report a thyroid hemiagenesis associated with a retrosternally located benign nodular goiter.

## Case Report

A 59-year-old male patient presented to the surgery

clinic because of swelling in the neck that had been presented for 5 - 6 years. The patient expressed that the swelling had been gradually growing in the last 3 - 4 months. He did not have any complaints including feeling pressure in the neck or symptoms of hyperthyroidism, but he had difficulty in swallowing from time to time.

The patient had a transient ischemic attack five years ago and was on acetylsalicylic acid 100 mg/day for treatment. He did not have any concomitant disease. He had not undergone any previous neck surgery.

On physical examination, there was a non-tender mass, which was mobile during swallowing, almost completely filling the thyroid right lobe and extending to the retrosternal region. The left lobe was not palpable. There were no prominent lymph nodes in the neck. The examinations of other systems were normal.

In the laboratory tests, a complete blood count and the biochemical tests were normal. A subclinical hyperthyroidism was determined by the thyroid function tests, and the patient was not on any anti-thyroid medications; Thyroid Stimulating Hormone (TSH) was determined as 0.005  $\mu$ IU/mL (Normal: 0,350 -4.940), free T3: 3.63 pg/mL (Normal: 1.71 – 3.71) and free T4 was 1.50 ng/dL (Normal: 0.7 - 1.48). Parathormone

**Corresponding Author:** T. Kirdak

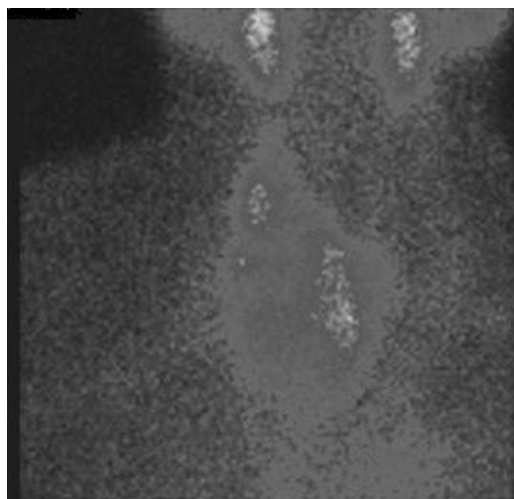
Department of Surgery, Faculty of Medicine, Uludag University, Bursa, Turkey  
Tel: +90 224 2952022, Fax: +90 224 4428398, E-mail address: tkirdak@uludag.edu.tr

## Thyroid hemiagenesis and retrosternal nodular goiter

concentration was 44.9 pg/dL (Normal:15 – 68.3) and the Total Calcium level was 9.4 mg/dL (Normal: 8.4 – 10.2 ). Thyroid auto-antibodies were negative.

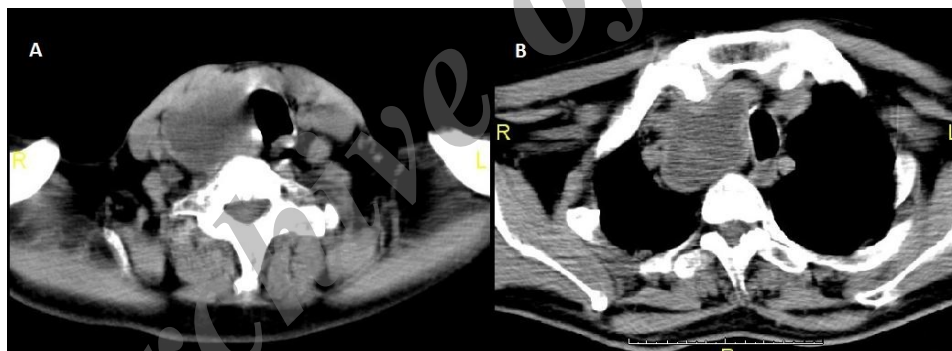
On direct Chest X-ray, the trachea was shifted to the left. On thyroid ultrasonography using the Linear 7.5 MHz probe, the thickness of the right lobe of the thyroid gland was measured as 43 mm, and a 63 mm-sized iso-hypoechoic semi-solid nodule with cystic degeneration areas was determined. The right lobe of the thyroid was extending to the retrosternal region. The left lobe of the thyroid could not be visualized. With these findings, the possibility of hemiagenesis in the left thyroid lobe was considered. Fine Needle Aspiration biopsy was performed on the nodule in the right lobe of the thyroid, the result of which was benign.

Thyroid scintigraphy was performed with Tc - 99m pertechnetate on this patient who had subclinical hyperthyroidism; the right lobe of the thyroid was larger than normal. A hyperactive nodule almost covering the entire lobe with partially hypoactive areas inside consistent with cystic degeneration was determined. There was no uptake observed in the left lobe of the thyroid (Figure 1).



**Figure 1.** Tc - 99m pertechnetate scintigraphy showing the right retrosternal thyroid lobe. The left lobe was not seen

On Computed tomography of the chest, the size of the right lobe of the thyroid was observed to be increased and extended to the retrosternal region. There were areas in the right lobe with no uptake of contrast agent. The left lobe of the thyroid could not be visualized (Figure 2).



**Figure 2.** Computed tomography.

**A.** Cervical section: the left lobe was not seen. **B.** Thoracic section showing right retrosternal extension of the thyroid

The patient, who also had left hemiagenesis, underwent an operation with the preliminary diagnosis of nodular goiter. A Kocher-collar incision was performed. Peri-operatively, the size of the right lobe was 10 × 6 × 4 cm, and there was a 6 cm-sized nodule filling the middle-inferior part of the lobe. It was extended 3 - 4 cm into the retrosternal region. The isthmus was present, and the thyroid tissue was seen to end on the trachea just to the left of the midline. The right lobe of the thyroid was totally removed without sternotomy. The right parathyroid glands and the inferior laryngeal nerve were in their normal place. Since the thyroid tissue was not extended to the left, the left side was not explored. Thus,

the left parathyroid glands and the inferior laryngeal nerve were not evaluated.

The patient was discharged on the first postoperative day. No complications developed due to surgery. The pathology result was reported as benign colloidal goiter. L-thyroxin started for the patient, and the postoperative third-week blood calcium, and PTH levels were 9.5 mg/dL and 68 pg/dL, respectively. Blood thyroglobulin concentration in the second month after surgery was 0.3 ng/mL.

## Discussion

In recent years, about 300 patients with thyroid

hemigenesis have been reported in the literature (3). Most of these patients were detected incidentally during the evaluation of other pathologies of the thyroid gland. In a literature review, hyperthyroidism was found in 16%, papillary thyroid cancer was found in 7%, and simple goiter was determined in 7% of the patients with hemigenesis. The rate of detection of nodular goiter in these patients was about 8% (6). However, some of these patients did not undergo surgery. We did not encounter any patient with hemigenesis and retrosternal goiter in literature accompanied. In this paper, we presented a thyroid hemigenesis patient with retrosternal nodular goiter that was diagnosed in an endemic nodular goiter region.

Its observation in monozygotic twins and the same family members provides clues that genetic factors may play a role in its development (7,8). There were no known thyroid abnormalities in the close relatives of our patient. Hemigenesis was not detected on the ultrasonographies of the patient's close relatives.

Agenesis is generally detected incidentally while evaluating pathology in the thyroid by imaging methods. The most important imaging method in the diagnosis is ultrasonography (2). In a patient with no history of neck surgery, no visualization of one of the thyroid lobes on ultrasonography should suggest hemigenesis. In the current patient, while evaluating the swelling in the neck, the non-visualization of the left lobe was determinative in the diagnosis of agenesis. Consistent with ultrasonography, Tc-99m pertechnetate scintigraphy, showed no radionuclide uptake on the agenetic side. However, in patients without agenesis, in the presence of toxic adenoma, the opposite lobe may not be visualized since the thyroid lobe is suppressed. This state can lead to an incorrect assessment of hemigenesis (9). Thus, diagnosing hemigenesis by relying only on scintigraphic findings can be misleading. Computed Tomography is another imaging method that can be used when necessary. In our patients, computerized tomography detected the agenesis and also provided information about the retrosternal extension of the thyroid lobe.

Since the thyroid was not extended to the opposite side in a patient, there was no need to explore the hemigenesis side perioperatively. For this reason, we do not know whether our patient had parathyroid abnormality in the hemigenesis side or not. However, postoperative hypocalcaemia or hypoparathyroidism did not develop. Furthermore, in a patient that was operated because of thyroid papillary thyroid adenoma, it was reported that the parathyroid glands were in their normal

locations on the agenetic side (4). Again, in a patient with thyroid, agenesis which had undergone subtotal parathyroidectomy for parathyroid hyperplasia, it was reported that the parathyroids and the inferior laryngeal nerve were in their normal locations at the hemigenesis side (10). These data suggest that there is no failure in the development of the parathyroid glands on the side where hemigenesis is present. If these patients are evaluated adequately in the preoperative period, consequent potential morbidities because of unnecessary explorations that would be performed on the agenetic side can be avoided. Consequently, thyroid hemigenesis can be present together with a retrosternally located benign nodular goiter.

## References

1. Maiorana R, Carta A, Floriddia G, et al. Thyroid hemigenesis: prevalence in normal children and effect on thyroid function. *J Clin Endocrinol Metab* 2003;88(4):1534-6.
2. Mikosch P, Gallowitsch HJ, Kresnik E, et al. Thyroid hemigenesis in an endemic goiter area diagnosed by ultrasonography: report of sixteen patients. *Thyroid* 1999;9(11):1075-84.
3. Hsieh K, Patel M, Palacios E, et al. Thyroid hemigenesis. *Ear Nose Throat J* 2012;91(5):190-4.
4. Shaha AR, Gujarati R. Thyroid hemigenesis. *J Surg Oncol* 1997;65(2):137-40.
5. Gursoy A, Anil C, Unal AD, et al. Clinical and epidemiological characteristics of thyroid hemigenesis: ultrasound screening in patients with thyroid disease and normal population. *Endocrine* 2008;33(3):338-41.
6. Emmy Wu Y, Wein RO, Carter B. Thyroid hemigenesis with multinodular goiter: a case presentation and review of literature. *Laryngoscope* 2010;120(Suppl 4):S191.
7. McLean R, Howard N, Murray IP. Thyroid dysgenesis in monozygotic twins: variants identified by scintigraphy. *Eur J Nucl Med* 1985;10(7-8):346-8.
8. Rosenberg T, Gilboa Y. Familial thyroid ectopy and hemigenesis. *Arch Dis Child* 1980;55(8):639-41.
9. Prakash R, Narayanan RV, Chakravarty SK. Differentiation between suppressed thyroid tissue and thyroid hemigenesis with Tc-99m pertechnetate radionuclide angiography. *Clin Nucl Med* 1990;15(9):605-9.
10. Duh QY, Ciulla TA, Clark OH. Primary parathyroid hyperplasia associated with thyroid hemigenesis and agenesis of the isthmus. *Surgery* 1994;115(2):257-63.