

Eosinophilic Granuloma of the Skull Base: Patient with Unique Clinical Moreover, Radiographic Presentation

Hosein Dalili¹ and Zahra Dalili Kajan²

¹ Department of Pediatrics, Breast Feeding Research Center, Tehran University of Medical Sciences, Tehran, Iran

² Department of Maxillofacial Radiology, School of Dentistry, Guilan University of Medical Sciences, Guilan, Iran

Received: 21 Sep. 2013; Accepted: 5 Jan. 2014

Abstract- This case report presents an eight-year-old girl having periauricular swelling and severe pain during mouth opening on the right-side temporomandibular joint (TMJ). CBCT showed extensive destruction of the base of the skull and the roof of the glenoid fossa on the right side. The findings based on CT and MRI images with and without contrast are discussed herein. This report highlights a skull base eosinophilic granuloma that mimics TMJ disorder and the importance of proper evaluation of CBCT images to make an early diagnosis.

© 2015 Tehran University of Medical Sciences. All rights reserved.

Acta Medica Iranica, 2015;53(1):69-73.

Keywords: Skull base neoplasm; Cone beam computed tomography; Temporomandibular joint disorder

Introduction

Langerhans cell histiocytosis (LCH) is a proliferative neoplastic lesion which originates from Langerhans cells. The solitary form of the lesion is referred to as an eosinophilic granuloma. LCH typically occurs in children under 15 years of age with its peak of incidence at ages 2-4 (1) showing a predilection for males (2). However, the trigger factor for this monoclonal proliferation of Langerhans cells is unknown. This immune dysregulation might be the result of persistent or transient systemic immunodeficiency diseases such as leukemia, lymphoma and viral infection (3) and is evidenced by the presence of active immunological cells and increased cytokines (4).

The tendency of the lesion occurs most frequently in bone than in soft tissue, and its incidence is seen more often in the skull than in other places (1,5). In the 2008 D'Ambrosio *et al.*, study, the involvement of the skull base was reported in 52% of patients with skull involvement; moreover, the temporal bone was most commonly involved, accounting for 48% of patients with skull base involvement (1).

The most common form of involvement is unifocal, about 60% (6). The unifocal type is more aggressive prompting extensive bone destruction and it quickly expands. However, patient prognosis is excellent due to

the self-limiting growth pattern of the tumor (3). Here we report a patient with skull base eosinophilic granuloma that mimics TMJ disorder and the importance of CBCT findings in early diagnosis.

Case Report

The patient was an 8-year-old girl who presented with painful swelling on the right side of the face in the preauricular area and around the TMJ. The chief complaint of the patient was severe pain on the right side of the mandible and a severe limitation in the range of jaw opening. Panoramic view initially revealed no significant radiographic findings in the TMJ area or the glenoid fossa. CBCT images, taken using Newtom VG devices (QR Srl Company, Verona, Italy), showed a destructive lesion of the glenoid fossa which was extended to the middle cranial fossa, the zygomatic arch and the anterior portion of the middle ear (Figure 1a-c). Central giant cell, rhabdomyosarcoma, chondrosarcoma, Ewing's sarcoma and chondromixoid tumors were considered in forming our differential diagnosis. High-resolution computed tomography (HRCT) scans using contrast agents, and MRI were performed to evaluate lesion extension and to explore the possibility of brain involvement. The patient was referred to a neurosurgeon for an additional workup.

Corresponding Author: Z. Dalili Kajan

Department of Maxillofacial Radiology, School of Dentistry, Guilan University of Medical Sciences, Guilan, Iran
Tel: +98 911 134-3432, Fax: +98 133486421, E-mail address: zahradalili@yahoo.com

Eosinophilic granuloma of the skull base

We re-evaluated the panoramic view and found that the cortical boundary of the right glenoid fossa was not as clearly defined as that on the left side (Figure 2). Multi-slice HRCT images of the temporal bone and the brain revealed a heterogeneous enhanced mass which involved the right submasseteric space and the inferior portion of the temporalis muscles.

The lesion had destroyed the glenoid fossa, the squamous portion of the temporal bone, the petrous part of the sphenoid bone toward the middle ear without involving the ossicles or the zygomatic process of the arch (Figure 3a-e). In MRI with and without

enhancement, no evidence of brain involvement was observed. In T2-weighted images, a homogenous hypersignal mass extending to the infratemporal fossa, periauricular area and intracranial portion were found. T1-weighted images with and without contrast agents revealed contrast enhancement (Figure 4a-d). Incisional biopsy showed LCH, specifically eosinophilic granuloma. A whole body scan revealed no additional destructive lesions. The patient was recommended to undergo chemotherapy using vinblastine, as well as steroid therapy with prednisolone.

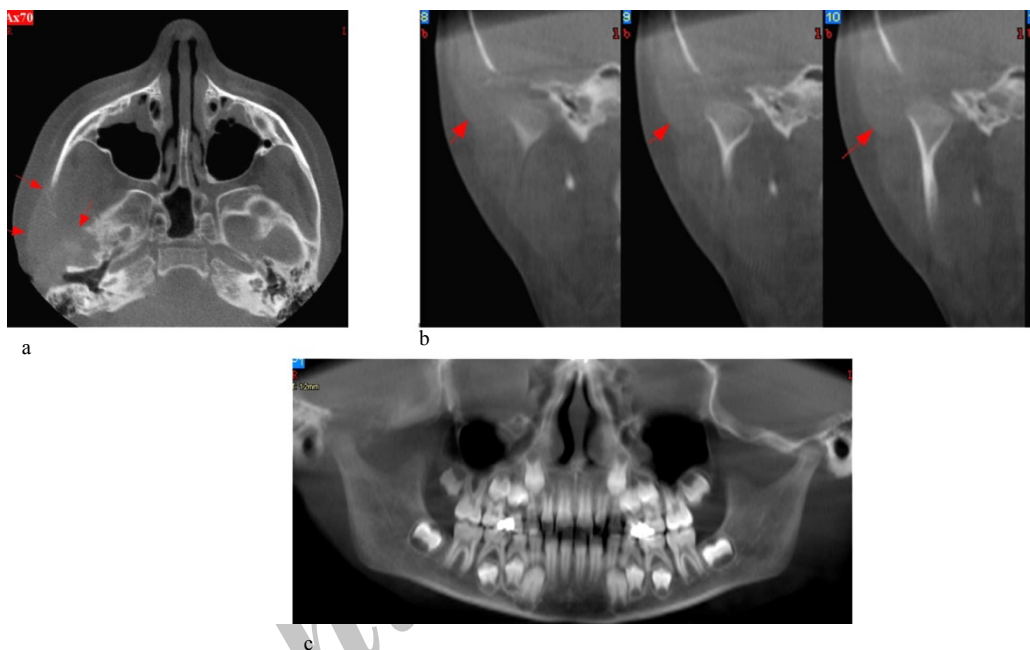


Figure 1. (a) Axial, (b) Cross-sectional, and (c) Reconstructed panoramic views of CBCT images reveal destruction of the roof of the glenoid fossa, the zygomatic process of the right zygomatic arch, and the squamous portion of the temporal bone. Soft tissue bulging in the right-sided periauricular area is observed.

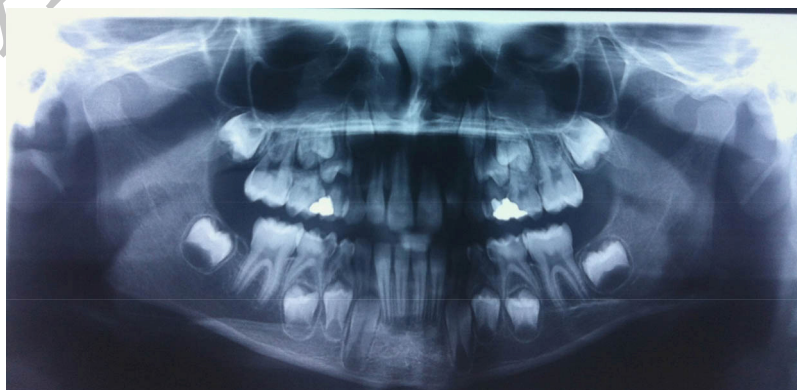


Figure 2. Re-evaluated panoramic view shows the loss of the cortical boundary of the right glenoid fossa

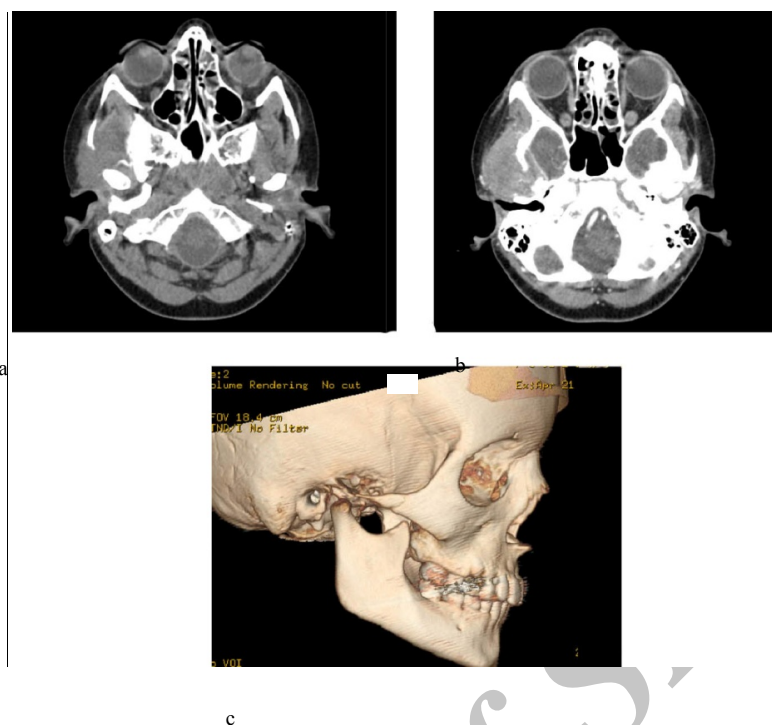


Figure 3. (a) Axial CT without and (b) with contrast enhancement reveals a heterogeneous enhanced mass showing a peripheral enhanced border on the right side; (c) three-dimensional (3D) CT indicates destruction of the right zygomatic arch and the temporal bone

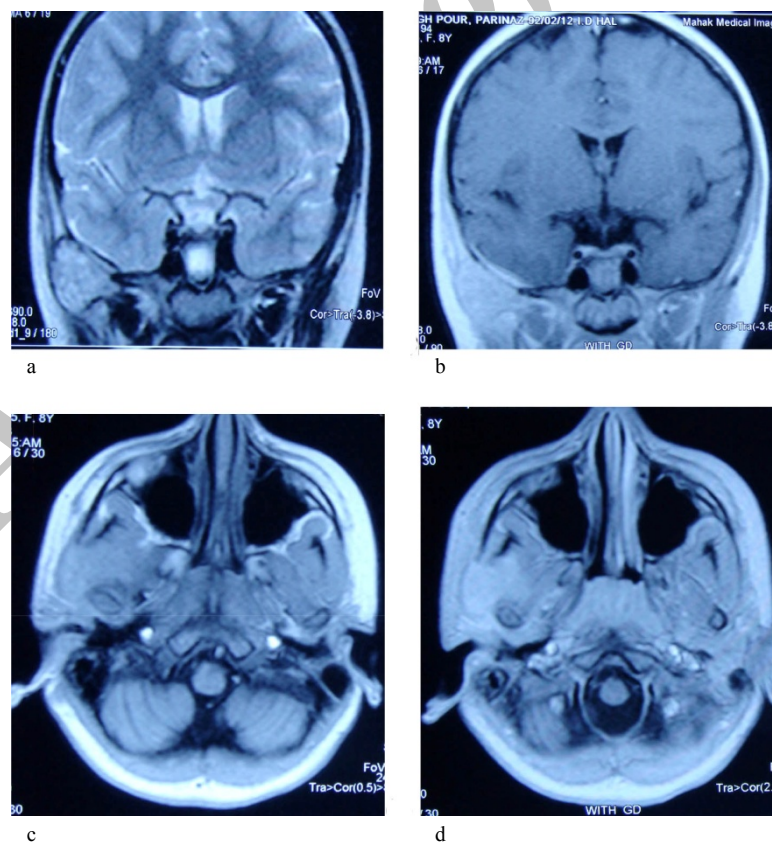


Figure 4. MRI images reveal (a) a hypersignal mass in a T_2 -weighted image, (b) a destructive mass with an isointense signal to gray matter in pre-contrast T_1 and, (c, d) contrast enhancement in post-contrast T_1 -weighted axial and coronal images

Discussion

Various patients with eosinophilic granuloma have been reported in the base of the skull (5-8); although, current patient presented with a TMJ complaint having the symptoms resembling TMJ disorder. According to our review, the chief complaints of current patient showing involvement of the skull were variable ranging from otitis media (5), eye swelling (6), persistent frontal skull pain (6), concomitant ear and eye pain (7), periorbital pain and headache (8).

Radiographic findings were confined to “punched out” radiolucencies or identifying centrally destructive lesions with non-sclerotic margins (8, 9). CT is reported to be helpful in demonstrating the extent and progression of the lesion (6). LCH lesions of the skull in MRI were isointense to gray matter on T1-weighted images and hyperintense on T2-weighted ones and could be enhanced via CT and MRI after administering contrast agents (1,6). Bone scintigraphy using a polyostotic form has been more frequently recommended for follow-up examination (6). In current patient, a hypersignal mass in T2 and an isointense signal intensity in T1 and enhancement, particularly in the periphery of the lesion were found.

Various sarcoma types such as rhabdomyosarcoma, Ewing’s sarcoma and osteosarcoma, LCH, and metastatic neuroblastoma are reported as the lesions that typically manifest with rapidly progressive facial pain and swelling (10).

Langerhans cells with grooved, folded or “coffee bean”-shaped nuclei having fine nuclear chromatin and inconspicuous nuclei characterize the lesion. LCH is usually associated with the presence of inflammatory cells, especially when large numbers of eosinophils are present. Numerous eosinophils have been reported to form microabscesses possibly and, at times, necrosis (5). Detection of Birbeck granules has been defined as the gold standard for diagnosing LCH (6). The presence of protein S-100 and the CD1a antigen helps to confirm LCH immunohistologically (5).

The protocol of treatment can be different. Four distinct approaches may first include administering no treatment at all because the lesion is considered as a self-limiting one (3,11). The second available option is to perform a partial resection, or a complete excisional biopsy (6) while the third choice is first to perform a biopsy and subsequently administer low-dose radiation to the lesion (12). Prescribing intralesional corticosteroids is the fourth option used for treating

unifocal eosinophilic granuloma (3,8). Systemic chemotherapy may be prescribed for systematically progressive lesions or recurrent ones (13). Overall, surgery or radiotherapy is often suggested for the treatment of the local form (7). Radiotherapy is very effective in relieving symptoms, particularly pain, and for preventing bone fracture (7,14). A total dose of 9-12 Gy is used to achieve effective local control in approximately 90% of cases (14,15). Administering a dose greater than 20 Gy was not recommended due to prompting a no dose-effect relationship (7). The long-term prognosis is dependent on patient’s response to treatment and the extent of the disease (9,16). The recurrent rate of a multifocal eosinophilic granuloma occurring higher than that of a unifocal tumor (1). The recurrence of the lesion usually occurs within two years. Thus, long-term follow-up of the patients using sequential imaging is recommended (17).

In conclusion, pain and swelling in the TMJ area of children must be considered seriously, because some common viral diseases could have similar signs and symptoms. It is critical for the radiologist to be sensitive to identify any dissimilarity between normal right and left landmarks in conventional radiographs. Upon considering the potential causes of TMJ disorders, identifying a temporal bone mass should be part of making a differential diagnosis. Similar reports (1, 6) have given us additional information about confirming the appearance of a rare lesion using MRI scanning technology.

References

1. D’Ambrosio N, Soohoo S, Warshall C, et al. Craniofacial and intracranial manifestations of Langerhans cell histiocytosis: report of findings in 100 patients. *AJR Am J Roentgenol* 2008;191(2):589-97.
2. Nicholson CM, Egeker RM, Nesbit ME. The epidemiology of Langerhans cell histiocytosis. *Hematol Oncol Clin North Am* 1998;12(2):379-84.
3. Harris GJ, Woo KI. Eosinophilic granuloma of the orbit: a paradox of aggressive destruction responsive to minimal intervention. *Trans Am Ophthalmol Soc* 2003;101:93-103.
4. Egeler RM, Annels NE, Hogendoorn PC. Langerhans cell histiocytosis: a pathologic combination of oncogenesis and immune dysregulation. *Pediatr Blood Cancer* 2004;42(5):401-3.
5. Nelson BL. Langerhans cell histiocytosis of the temporal bone. *Head and Neck Pathol* 2008;2(2):97-8.
6. Kasper EM, Aguirre-Padilla DH, Alter RY, et al.

- characteristics, behavior, and treatments as illustrated in a case series. *Surg Neurol Int* 2011;2(1):57.
7. Meyer A, Stark M, Karstens JH, et al. Langerhans cell histiocytosis of the cranial base: is low-dose radiotherapy effective? *Case Rep Oncol Med* 2012;2012:789640.
 8. Binning MJ, Brockmeyer DL. Novel multidisciplinary approach for the treatment of Langerhans cell histiocytosis of the skull base. *Skull Base* 2008;18(1):53-8.
 9. Boston M, Derkay CS. Langerhans' cell histiocytosis of the temporal bone and skull base. *Am J Otolaryngol* 2002;23(4):246-8.
 10. Khanna G, Sato Y, Smith RJ, et al. Causes of facial swelling in pediatric patients: correlation of clinical and radiologic findings. *Radiographics* 2006;26(1):157-71.
 11. Gunny R, Clifton A, Al-Memar A. Spontaneous regression of supratentorial intracerebral Langerhans' cell histiocytosis. *Br J Radiol* 2004;77(920):685-7.
 12. Greenberger JS, Cassady JR, Jaffe N. Radiation therapy in patients with histiocytosis: management of diabetes insipidus and bone lesions. *Int J Radiat Oncol Biol Phys* 1979;5(10):1749-55.
 13. Imamura T, Sato T, Shiota Y, et al. Outcome of pediatric patients with Langerhans cell histiocytosis treated with 2 chlorodeoxyadenosine: A nationwide survey in Japan. *Int J Hematol* 2010;91(4):646-51.
 14. Olschewski T, Seegenschmiedt MH. Radiotherapy for bony manifestations of langerhans cell histiocytosis: review and proposal for an international registry. *Strahlenther Onkol* 2006;182(2):72-9.
 15. Heyd R, Strassmann G, Donnerstag F, et al. Radiotherapy in Langerhans-cell histiocytosis. 2case reports and review of the literature. *Rontgenpraxis* 2000;53(2):51-61.
 16. Surico G, Muggeo P, Muggeo V, et al. Ear involvement in childhood Langerhans' cell histiocytosis. *Head Neck* 2000;22(1):42-7.
 17. Escardo-Paton JA, Neal J, Lane CM. Late recurrence of Langerhans cell histiocytosis in the orbit. *Br J Ophthalmol* 2004;88(6):838-9.

Archive of SID