

Neoadjuvant Chemotherapy for Locally Advanced Squamous Carcinoma of Oral Cavity: a Pilot Study

Sanambar Sadighi¹, Amanolah Keyhani², Iraj Harirchi², Ata Garajei², Mahdi Aghili³, Ali Kazemian³, Maziar Motiee Langroudi⁴, Kazem Zendehtdel¹, and Nariman Nikparto¹

¹ Cancer Research Center, Cancer Institute of Iran, Tehran University of Medical Sciences, Tehran, Iran

² Department of Head and Neck Surgical Oncology and Reconstructive Surgery, Cancer Institute of Iran, Tehran University of Medical Sciences, Tehran, Iran

³ Radiotherapy Oncology Research Center, Cancer Institute of Iran, Tehran University of Medical Sciences, Tehran, Iran

⁴ Department of Ear, Nose and Throat, Valiasr Hospital, Cancer Research Center, Tehran University of Medical Sciences, Tehran, Iran

Received: 10 Aug. 2014; Accepted: 26 Nov. 2014

Abstract- To evaluate the effect of adding neoadjuvant chemotherapy to surgery and radiation therapy for locally advanced resectable oral cavity squamous cell carcinoma, 24 patients with T3 or T4a oral cavity squamous cell carcinoma were randomly assigned to surgery alone or Docetaxel, Cisplatin, and 5-FU (TPF) induction chemotherapy followed by surgery. All patients were planned to receive chemoradiotherapy after surgery. The primary end-points were organ preservation and progression-free-survival. SPSS version 17 was used for data analysis. Median follow-up was 16 months. The median age of the patients was 62 years old (23-75 years). Man/woman ratio was 1.13. The primary site of the tumor was the tongue in most patients (48%). No significant difference was observed between pathologic characteristics of the two groups. Chemotherapy group showed 16% complete pathologic response to TPF. No significant difference in organ preservation surgery or overall survival was detected. However, the patients in the chemotherapy group had longer progression-free-survival ($P=0.014$). Surgery followed by chemoradiotherapy with or without TPF induction results in similar survival time. However, progression-free-survival improves with the TPF induction chemotherapy. Studies with more patients and new strategies are recommended to evaluate organ preservation improvement and long-term outcomes.

© 2015 Tehran University of Medical Sciences. All rights reserved.

Acta Med Iran 2015;53(6):380-386.

Keywords: Oral cavity; Squamous cell carcinoma; Randomized clinical trial; Induction chemotherapy; Organ preservation

Introduction

Head and neck cancer is the fifth most prevalent cancer worldwide (1). In spite of developments in diagnosis and treatment of this cancer, the long-term survival of patients has not been improved over the past four decades. Statistics of surgical departments indicate that only half of the patients with oral cavity squamous cell carcinoma gain full recovery, while most of them recur regionally or distantly in the first two years in spite of initial surgery and radiotherapy (2).

Although surgery is the mainstream therapy in oral cavity squamous cell carcinoma, most of the patients in

stage IV with involvement of cortical bone, deep muscles of the tongue, etc, experience severe complications and are more likely to have positive margins. Adjuvant chemoradiotherapy is also associated with acute mucositis, dysphagia, nausea, vomiting, hoarseness, dermatitis and long-term complications such as esophageal stenosis, hypothyroidism, osteoradionecrosis, xerostomia and subcutaneous fibrosis (3). Induction chemotherapy reduces the distant recurrence rate from 38% to 14% in stages III and IV of oral cavity squamous cell carcinoma (4), while chemoradiotherapy only decreases local relapse rate and does not seem to have any impact on distant metastasis (5).

Corresponding Author: S. Sadighi

Cancer Research Center, Cancer Institute of Iran, Tehran University of Medical Sciences, Tehran, Iran
Tel: +98 21 61192763, Fax: +98 21 88788163, E-mail address: ssadighi@tums.ac.ir

Hence, a joint pilot study was designed by Cancer Surgery, Radiology, Radiotherapy, Pathology, Medical Oncology, Oral and Maxillofacial Surgery, and Ear, Nose, and Throat Departments to evaluate the efficiency, tolerability and compliance to an induction chemotherapy regimen called TPF (triple combination of Docetaxel, Cisplatin and 5-fluoro-uracil (5-FU)) in improving the clinical outcomes of stages III and IV in treatment of oral cavity cancer.

The purpose of this study was to compare the results of up-front radical surgery with TPF chemotherapy before surgery for stages III and IV of resectable oral cavity squamous cell carcinoma considering organ preservation, progression-free interval, overall survival, local relapse, and distance metastasis in patients.

Materials and Methods

A total of 24 patients with T3 or T4a oral cavity squamous cell carcinoma who had referred to the Cancer Institute of Iran were included in the study if they were capable of receiving initial surgery and chemotherapy. Written informed consent was obtained from each patient, and then they were randomly enrolled into two groups: A (induction chemotherapy) and B (initial surgery).

The inclusion criteria were: (1) Having 18- 75 years old; (2) Having definite pathologic or cytologic diagnosis of squamous cell carcinoma; (3) Pan-endoscopy of ear, nose and throat area; (4) Measurable lesion in one or two directions (at least in head and neck, and chest); (5) Untreated stages III or IVa of locally advanced oral cavity squamous cell carcinoma; (6) Appropriate health condition (being able to perform their personal tasks); (7) Proper function of the cardiovascular system, liver, kidney and bone marrow for receiving chemotherapy and surgery; (8) Tumor placed in the oral cavity: the lips, tongue, floor of the gingival and oral mucosa, or retromolar trigone.

The exclusion criteria were: (1) Having a history of chemotherapy or radiotherapy; (2) Having the primary tumor in the nasopharynx, larynx or paranasal sinuses, or more than 50% of tumors in the oropharynx; (3) Having an extended tumor into the skull base or paravertebral muscles; (4) Having a distant metastasis.

In group A, patients received chemotherapy based on a daily schedule of one hour infusion of 70-80 mg per square meter of body surface Docetaxel (Sanofi, France), then an hour infusion of 60 mg per square

meter of body surface Cisplatin (Sandoz, Switzerland) and 24-hour infusion of 750 mg per square meter of body surface 5-FU (Sandoz, Switzerland) for five days. After each cycle of chemotherapy, patients were checked for response and toxicity by a complete physical examination and laboratory tests of renal, liver function, platelet and white blood cell count. A questionnaire was filled for checking the toxicity of the treatment.

After two cycles of chemotherapy, computed tomography (CT) scans were repeated, and the stage of the disease was determined once again. Patients with at least 50% response to chemotherapy received the third course of chemotherapy followed by radical surgery and postoperative radiotherapy. Otherwise, the patients were immediately sent for surgery.

In such patients, the extent of surgery was determined by the surgeon, and if it was not possible, they were assigned to chemo-radiotherapy. When distant metastasis had occurred the patient was excluded from the study and further treatment was decided based on his/her health status. All patients were followed up until progress or death.

The progression-free-survival (PFS) was measured from the date a patient was included in the study until the first documentation of disease progress or death from any cause, whichever occurred first. Overall survival time was measured from the date of inclusion to the date of death from any cause. All data were analyzed using statistical package for the social sciences (SPSS) version 17.

Results

This study was performed between 2009 and 2011 during which 24 patients were included and randomly enrolled into two groups. The reasons behind slow randomization of this study were the low patient inclusion rate, limited numbers of resectable tumors which were in advanced stages, unwillingness of surgeons for starting chemotherapy in resectable tumors, and increasing tendency for doing chemo-radiotherapy as a conclusive treatment in potentially resectable tumors.

Finally, 11 patients were enrolled in the surgery group and 13 patients in the neoadjuvant chemotherapy group. The mean age was 59 ± 14.4 years old with the median of 62. Among the participants, there were 14 men. The tongue, gingiva and mouth floor were the most common affected areas. Approximately 37% of tumors were well-differentiated, 37% intermediately

Neoadjuvant chemotherapy for locally

differentiated and 25% were poorly differentiated; 12% of tumors were 3-4cm in size (T2), 63% more than 4cm in size (T3) and 25% had invaded into surrounding tissues (T4). Only 7(29%) patients had no lymph node involvement. However, 12 patients had unilateral lymph node involvement, and 5 patients had bilateral cervical lymph node involvement. Blood vessel involvement was seen in the pathology of five patients (18%) and nerve fiber involvement in 10 patients

(41%).

All patients received surgical treatment: 17 patients had organ-preserving surgeries with free margins, and seven patients had radical bone (osseous) resection and reconstructive surgeries. Distribution of clinicopathologic characteristics was balanced between the two groups, but there were more men in the surgery group (Table 1).

Table 1. Clinicopathologic characteristics of patients in two groups

Variable		Surgery G(1)	Chemotherapy G(2)	Significance
AGE	Mean	63 (SD 12.6)	57 (SD= 15.4)	0.508
	Median	66	62	0.021*
GENDER	Male	9	7	
	Female	2	12	
Tongue		5	11	0.152
Gum		4	1	0.135
Alveolar ridge		0	1	0.690
Oral Cavity		2	6	
Diff	Well	4	9	0.745
	Mod	5	6	0.746
	Poorly	2	4	0.781
Tumor	T2	1	2	0.963
	T3	6	11	0.963
	T4	4	6	0.793
LN Involvement	N1	5	9	0.922
	N2	3	6	0.707
Vascular invasion		2	2	0.328
Peri-neural invasion		3	9	0.550
Bone involvement		4	6	0.316

In chemotherapy group, patients received 2-4 chemotherapy cycles. Three (16%) patients showed complete pathological response to the treatment and only one patient showed progress with the extension of the tumor (more than 20% increase in size) during the chemotherapy courses. A total of 15 patients experienced relapse and 18 died until the October 2014. Most relapses were because of loco-regional tumor progress. However, 3(10%) patients experienced distant metastases. Two patients after surgery and one after chemotherapy died because of the possible complications of the treatment. The overall survival curves were similar (Figure 1). Progression-free-survival in the chemotherapy group was marginally better than the other first group (Figure 2). Because of relapse, six patients received re-radiation with or without chemotherapy.

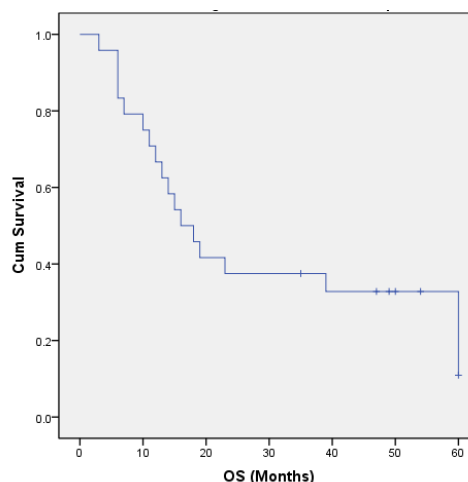


Figure 1. Overall survival of patients

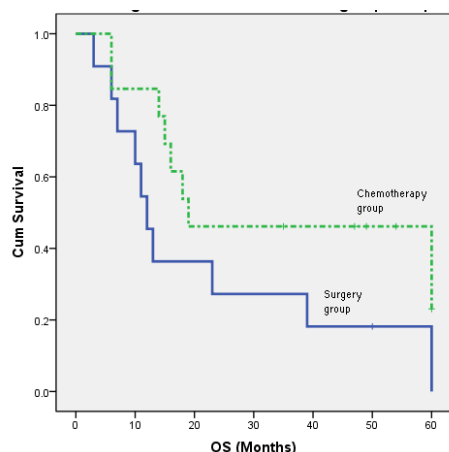


Figure 2. Overall survival of 2 groups of patients

Discussion

The primary end-point in the treatment of loco-regional aggressive oral cavity squamous cell carcinoma is organ preservation. This minimizes the acute and chronic complications of treatment, leading to a better quality of life as well as prolonging overall and progression-free survival (7). Thus, present participant selection and the decision for treatment were made by the head and neck tumor board, consisting of an oral and maxillofacial surgeon, two cancer surgeon, an ear, nose, throat surgeon, a medical oncologist, two radiotherapist, a radiologist, a pathologist, a facial reconstructive surgeon, and a palliative medicine specialist.

Current results suggest a possibility for more conservative surgery with induction chemotherapy in oral cavity squamous cell carcinoma (OSCC), without loss of life or increased relapse. Reviewing the literature shows that using induction chemotherapy protocol for treatment of non-metastatic oral cavity squamous cell carcinoma is limited to specific situations. The role of induction chemotherapy in an effort to preserve organ in tumors of the larynx, oropharynx and hypopharynx is well-known (8,9). Similarly, induction chemotherapy is recommended in the treatment of OSSC in which demolition surgery such as complete resection of tongue or pharyngectomy is required (10). Theoretically, chemotherapy before operation and radiotherapy might be recommended because of the intact tumor vasculature which allows the drugs to be released into the tumor more efficiently (11).

This study indicated improved surgical results. The percentages of organ preservation surgery were 54% in the surgical group and 80% in the chemotherapy group. Radical surgery percentages in the two groups were 46% and 20%, respectively. Fortunately, no case of

macroscopic residual tumor was observed in the two groups. Microscopic examination of the margins of surgical specimens showed the better outcome in the chemotherapy group, but the association was not statistically significant.

A randomized clinical trial by Licitra and colleagues indicated that in patients with advanced resectable untreated tumors of the oral cavity, compared with up-front surgery, reduction in the number of patients needed to undergo mandibulectomy and/or postoperative radiation therapy was seen following induction chemotherapy (12). In the current study, no significant difference was found between the two groups in the need for surgery of mandible or maxilla. In the surgery group, the microscopic positive margins were more probable, although this result was not statistically significant. These results are not conclusive. It is better to state that advanced OSSC with mandible invasion is an ominous disease, and there is no proof of the clear advantage of any specific sequence of multimodality therapy (13).

A recent study indicates that in the tumors of gingivae which are close to mandible or maxillary bone, osteoclasts have the main role in bone desorption, so the tumor cells are not involved directly. Osteoclasts are stimulated by receptor activator of nuclear- κ B ligand (RANKL)/RANK signaling system and thus administration of osteoprotegerin or soluble RANK seems to be effective in the prevention of bone metastases (14).

Based on the literature, the systemic induction (or preoperative neoadjuvant) chemotherapy aims to reduce the tumor size, surgical risk, the possibility of local relapse and distant metastases and improve respectability of tumor. Indeed, this kind of treatment increases the possibility of organ preservation. But based on general principles, the extent of the surgery is determined by the primary size of the tumor; therefore, markings around the tumor before treatment are recommended. In current patients, the extent of surgery was determined based on the initial CT scan and magnetic resonance imaging (MRI) images. However, three patients in the chemotherapy group had a complete pathological response (i.e. no evidence of tumor in the surgical specimen). Thus, we suggest putting markings before induction chemotherapy as a guide for further therapies.

It seems that a complete response to systemic therapy depends on the biology of tumors. In fact, all those three patients were young non-smoker women. We did not investigate the human papillomavirus (HPV) in

Neoadjuvant chemotherapy for locally

our patients. However studies have shown that the presence of certain oncotypes of this virus is associated with stimulation and increase in the number of malignant epithelial cells. Thus, using immunohistochemistry or cytogenetic techniques may be useful in targeting therapy (15).

In a recent meta-analysis of 14 randomized clinical trials, the authors state that chemotherapy before local therapy (surgery or radiotherapy) was associated with an 8% reduction in distant recurrence. However, progression-free interval or overall survival was not increased (10). Drug toxicity was acceptable and did not interfere with the subsequent surgical treatment or chemo-radiotherapy or radiotherapy. The authors conclude that the induction chemotherapy treatment method is most effective in a group of tumors with metastatic potential. With prolonged follow-up, three of our patients developed distant metastases, without local relapse. It was impossible to differentiate second primary tumor from metastasis in these patients.

Several studies have compared the old chemotherapy protocol of Cisplatin and 5-FU (PF) with TPF regimen containing Taxane (Docetaxel). Based on their results therapeutic response and overall survival was higher in taxane-based regimen (16-18).

In this study Docetaxel, Cisplatin and 5-FU (TPF) was used. A favorable response was seen with no unexpected toxicity or adverse effect on subsequent local treatment. Induction chemotherapy did not increase perioperative morbidity. However, one month after the end of chemotherapy an old patient developed heart problems and received heart surgery for which the possibility of the drugs' side-effects cannot be denied. There are reports about toxicity (19) and quality of life issues of TPF protocol (20,21). Modified schedules of TPF have been suggested to decrease adverse events as well (22).

Another debate regarding induction chemotherapy is responses aimed to help choosing the next proper treatment, typically choosing between radiotherapy and surgery. For instance, in tumors of the oropharynx and larynx, 50-80% of clinical response rate to induction chemotherapy is acceptable cut-off point for choosing radiotherapy as the next local treatment (23,24). Otherwise, surgery would be preferred (25).

Limitations of this study were inadequate number of participants, failure to assess tumor's biological factors such as epidermal growth factor gene mutations, the activity of P53, RANKL/RANK signaling system and human papilloma virus in tumor specimen (26). These limitations are the major obstacles for generalizing its

findings.

Overall, it seems that the effect of preoperative chemotherapy on oral cavity tumors is less than that of the oropharynx and hypopharynx tumors. The cause somehow is related to more response to chemotherapy in the pharynx (80-100% overall response and 30-40% complete pathological response rate). In present study overall and complete pathological responses were 60% and 16%, respectively. Among the factors contributing to these differences in response, biological characteristics of tumors in different parts of head and neck such as the higher prevalence of the human papilloma virus in oropharynx may be involved (27-29).

The standard treatment of oral cavity tumors in stage III and IV is still surgery. However, in the case of advanced tumors that require complete resection of the tongue or pharynx, organ preservation treatments such as initial chemotherapy and/or chemo-radiation therapy can be considered primarily. On the other hand, 30-40% of patients with lymph node involvements in stages II or III will develop distant metastases sooner or later. So the way to prevent the growth of micro-metastases is actually chemotherapy. The third reason for initial chemotherapy is that the new TPF chemotherapy regimen is now available with minimal side effects and quick elimination of local symptoms and eating problems.

This clinical trial has shown the possibility of more limited surgery after induction chemotherapy. But considering the limitations of the study such as little number of patients and the impossibility of continuing random allocation after the first group of patients, the results are not generalizable to all patients with advanced oral cavity squamous cell carcinoma. Multicenter studies with new strategies examining the biological characteristics and genetics of tumors are recommended to improve organ preservation and long-term clinical outcomes of individual patients.

Acknowledgment

This research has been supported by Tehran University of Medical Sciences (Grant No. 87-02-51-7415). The authors would like to thank Seyed Muhammed Hussein Mousavinasab for his sincere cooperation in editing this text.

References

1. Siegel R, Naishadham D, Jemal A. Cancer Statistics, 2013.

- Cancer J Clin 2013;63(1):11-30.
2. Oliver RJ, Clakson JE, Conway DI, et al. Interventions for the treatment of oral and oropharyngeal cancers: surgical treatment. *Cochrane Database System Rev* 2007;(4):CD006205.
 3. Cmelac A, Arneson K, Chau NG, et al. Locally advanced head and neck cancer. *Am Soc Oncol Educ Book* 2013:237-44.
 4. Furness S, Glenny AM, Worthington HV, et al. Interventions for the treatment of oral cavity and oropharyngeal cancer: chemotherapy. *Cochrane Database Syst Rev* 2011;13(4): CD006386.
 5. Ma J, Liu Y, Zhang ZY, et al. Induction chemotherapy decreases the rate of distant metastasis in patients with head and neck squamous carcinoma: a meta-analysis. *Oral Oncol* 2012;48(11):1076-84.
 6. Forastiere AA, Zhang Q, Weber RS, et al. Long-term results of RTOG 91-11: a comparison of non-surgical treatment strategies to preserve larynx with locally advanced larynx cancer. *J Clin Oncol* 2013;31(7):845-52.
 7. Forastiere A, Goepfert H, Maor M, et al. Concurrent chemotherapy and radiotherapy for organ preservation in advanced laryngeal cancer. *N Engl J Med* 2003;349(22):2091-98.
 8. Vokes EE. Competing roads to larynx preservation. *J Clin Oncol* 2013;31(7):833-5.
 9. Pignon JP, Bourhis J, Domenge C, et al. Chemotherapy added to locoregional treatment for head and neck SCC: three meta-analysis of updated individual data. MACH-NC collaborative group. *Lancet* 2000;355(9208):949-55.
 10. Ma J, Liu Y, Yang Xi, et al. Induction chemotherapy in patients with resectable head and neck SCC: a meta-analysis. *World J Surg Oncol* 2013;11(1):67.
 11. Karagöglü KH, Buter J, Leemans CR, et al. Subset of patients with verrucous carcinoma of oral cavity who benefit from treatment with methotrexate. *Br J Oral Maxillofac Surg* 2012;50(6):513-8.
 12. Licitra L, Grandi C, Guzzo M. Primary chemotherapy in resectable oral cavity SCC. *J Clin Oncol* 2003;21(2):327-33.
 13. Myers LL, Sumer BD, Truelson JM, et al. Impact of treatment sequence of multimodal therapy for advanced oral cavity cancer with mandible invasion. *Otolaryngol Head Neck Surg* 2011;145(6):961-6.
 14. Jimi E, Shin M, Furuta H, et al. The RANKL/RANK system as a therapeutic target for bone invasion by oral SCC (Review). *Int J Oncol* 2013;42(3):803-9.
 15. Lefebvre JL, Pointreau Y, Rolland F, et al. Induction Chemotherapy followed by either chemoradiotherapy or bioradiotherapy for larynx preservation: TREMPIN randomized phase II study. *J Clin Oncol* 2013;31(7):853-9.
 16. Posner MR, Herschock DM, Blajman CR, et al. Cisplatin and Fluorouracil Alone or with Docetaxel in Head and Neck Cancer. *N Engl J Med* 2007;357(17):1705-15
 17. Remenar E, Van Harpen C, Germa L, et al. A randomized phase II multicenter trial of neoadjuvant docetaxel plus cisplatin and 5-FU vs. PF in patients with locally advanced unresectable SCC of the head and neck. *Am Soc Clin Oncol* 2006;241:85;
 18. Forastiere AA, Zhang Q, Weber RS, et al. Long-term results of RTOG 91-11: a comparison of three nonsurgical treatment strategies to preserve the larynx in patients with locally advanced larynx cancer. *J Clin Oncol* 2013;31(7):845-52.
 19. Billan S, Kaidar-Person O, Atrash F, et al. Toxicity of induction chemotherapy with docetaxel, cisplatin, and 5-FU for advanced head and neck cancer. *Isr Med Assoc J* 2013;15(5):231-5.
 20. Crombie AK, Farah CS, Batstone MD. Health-related quality of life of patients treated with primary chemoradiation for oral cavity SCC: a comparison with surgery. *Br J Oral Maxillofac Surg* 2014;52(2):111-7.
 21. Himmel M, Hartmann M, Guntinas-Lichius O. Cost effectiveness of neoadjuvant chemotherapy in locally advanced operable head and neck cancer followed by surgery and postoperative radiotherapy: a markov model-based decision analysis. *Oncology* 2013;84(6):336-41.
 22. Oretal K, Spiegel K, Schmalenberg H, et al. Phase I trial of split-dose induction docetaxel, cisplatin, and 5-fluorouracil (TPF) chemotherapy followed by curative surgery combined with postoperative radiotherapy in patients with locally advanced oral and oropharyngeal squamous cell cancer (TISOC-1). *BMC Cancer* 2012;12:483-92.
 23. Brockstein B, Haraf DJ, Rademaker AW, et al. Patterns of failure, prognostic factors and survival in locoregionally advanced head and neck cancer treated with concomitant chemoradiotherapy: a 9-year, 337-patient, multi-institutional experience. *Ann Oncol* 2004;15(8):1179-86.
 24. Haddad R, O'Neill A, Rabinowits G, et al. Induction chemotherapy followed by concurrent chemoradiotherapy (sequential therapy) vs. concurrent chemoradiotherapy alone in locally advanced head and neck cancer (PARADIGM): a randomized phase 3 trial. *Lancet Oncol* 2013;14(3):257-64.
 25. Posner MR, Norris CM, Wirth LJ, et al. Sequential therapy for the locally advanced larynx and hypopharynx cancer subgroups in TAX324: survival, surgery, and organ preservation. *Ann Oncol* 2009;20(5):921-7.
 26. Psyrri A, Seiwert TY, Jimeno A. Molecular pathways in head and neck cancer: EGFR, PI3K, and more. *Am Soc Clin Oncol Educational Book* 2013:246-55.

Neoadjuvant chemotherapy for locally

27. Stransky N, Egloff AM, Tward AD, et al. The mutational landscape of Head and Neck squamous cell carcinoma. *Science* 2011;333(6046):1157-60.
28. Psyrri A, Licitra L, De Blas B, et al. Safety and efficacy of cisplatin plus 5-FU and cetuximab in HPV-positive and HPV-negative recurrent and/or metastatic SCC of head and neck: analysis of the phase III EXTREME trial. *Ann Oncol* 2012;23(Suppl 9):ix334-47.
29. Holsinger FC, Piha-Paul SA, Janku F, et al. Biomarker-Directed Therapy of Squamous Carcinomas of the Head and Neck: Targeting PI3K/PTEN/mTOR Pathway. *J Clin Oncol* 2013;31(9):e137-40.

Archive of SID