

Unstimulated Salivary p53 in Patients with Oral Lichen Planus and Squamous Cell Carcinoma

Farzaneh Agha-Hosseini^{1,2,3}, Iraj Mirzaei-Dizgah⁴,
and Najmeh-Sadaat Miri-Zarandi¹

¹ Department of Oral and Maxillofacial Medicine, Dental Research Center, Tehran University of Medical Sciences, Tehran, Iran

² Department of Oral Maxillofacial Medicine, School of Dentistry, Tehran University of Medical Sciences, Tehran, Iran

³ Department of Oral Maxillofacial Medicine, The Academy of Medical Sciences, Tehran, Iran

⁴ Department of Physiology, School of Medicine, Aja University of Medical Sciences, Tehran, Iran

Received: 24 Feb. 2014; Accepted: 23 Dec. 2014

Abstract- Unstimulated whole salivary p53 was evaluated in non-involved subjects, in patients suffering from oral lichen planus (OLP) and squamous cell carcinoma (SCC). A total of 34 patients with OLP, 24 patients suffering from oral SCC and 41 non-involved participants were enrolled. The unstimulated whole saliva p53 level was assayed by ELISA. Data was analyzed by ANOVA followed by the Tukey post hoc test. Saliva p53 concentration in patients with SCC (5.36 ± 1.08) was significantly higher than in healthy participants (0.41 ± 0.04) and in patients suffering from OLP (0.94 ± 0.31). This study could not confirm the precancerous nature of OLP based on the relatively low p53 expressions in comparison to SCC.

© 2015 Tehran University of Medical Sciences. All rights reserved.

Acta Med Iran 2015;53(7):439-443.

Keywords: Oral lichen planus; Saliva; SCC; p53

Introduction

Oral lichen planus (OLP) is a relatively common chronic inflammatory disease that probably represents a cell-mediated immunological response (autoimmune disease) to an induced antigenic change in the skin or mucosa in predisposed subjects (1-4). In contrast to lichen of the skin, OLP seems to have a chronic cause with low tendency to spontaneous regression and high resistance to topical treatment (5). Despite the controversy surrounding the malignant potential of OLP, the transformation of this lesion to squamous cell carcinoma (SCC) is considered an important issue for the patient (4).

It has been suggested that OLP may be a premalignant lesion since in a few cases oral SCC, with or without previous epithelial dysplastic changes that are observed in patients affected by OLP (6). World Health Organization (WHO) has classified OLP as a pre-malignant condition; however, the underlying mechanism initiating development of cancer in OLP lesions is not understood (5,7,8).

SCC is an aggressive and common oral neoplasm that is highly locally invasive and frequently ulcerative,

and may cause a lytic change in underlying bony structures. Common presenting symptoms include ptyalism, halitosis, and mechanical interference with food prehension (9). The incidence rates for oral cancers show marked geographic differences and are particularly high in certain parts of the world (7).

Oncogenesis currently has been related to further risk factors that also must be taken into account - not only smoking and alcohol but also infections with candida, human papillomavirus and Epstein-Barr virus; the probable influence of nutritional, genetic and hereditary factors, and a number of other factors are known to increase the risk of oral carcinoma. These include pre-existing chronic oral lesions such as leukoplakia, erythroplakia; more controversially, lichen planus has been associated with oral SCC (7,10).

Approximately two decades ago the p53 tumor suppressor was discovered (5). The p53 protein (TP53 product) is a master switch that coordinates and concentrates a plethora of stress signals and transforms them into a series of responses, such as arrest of cell growth, apoptosis or DNA repair (8). Activation of p53 after DNA damage or oncogenic signaling is an important protective mechanism, which facilitates DNA

Corresponding Author: F. Agha-Hosseini

Department of Oral Medicine, Dental Research Center, Tehran University of Medical Sciences, Tehran, Iran
Tel: +98 21 66402095, Fax: +98 21 66401132, E-mail address: aghahose@sina.tums.ac.ir

repair and stimulates apoptosis of the condemned cells (11). Functional loss and altered expression of p53 are the most frequent genetic changes in human cancers (11).

Potentially malignant lesions are those occurring in a morphologically altered tissue. To analyze the malignant potential, it is important to consider that oncogene activation and inactivation of tumor suppressor genes occurs precociously in carcinogenesis. Thus, even when the neoplasm cannot be detected either clinically or morphologically, a lesion may be already undergoing this initial phase of carcinogenesis (1).

Research on saliva is a dynamic field. Saliva has proven its value for diagnostic purposes. It can be collected in a safe and patient-friendly way requiring no special training. Improved technology also makes it possible to diagnose virtually everything using blood tests (12). A high prevalence of TP53 mutations has been seen in patients with OLP; almost all were detected in tissues by different methods (5).

The purpose of this study was to evaluate and compare unstimulated whole salivary p53 in patients suffering from OLP, SCC, and non-involved participants.

Materials and Methods

Participants

A total of 34 patients with OLP (17 erosive and 17 reticular forms) were selected from those referred to the Department of Oral Medicine, Faculty of Dentistry, Tehran University of Medical Sciences (TUMS). Inclusion criteria consisted of being clinically diagnosed with lichen planus (presence of bilateral lesions, and presence of reticular lesions elsewhere in the oral), and in histopathological examination (presence of well-defined band like zones of inflammatory infiltration confined to the superficial part of the connective tissue, consisting mainly of mature lymphocytes – vacuolar alteration of the basal layer of the epithelium), comprised lichen group (15 men, 19 women; aged 28–74 years).

Twenty-four patients with confirmed clinical and histopathological oral SCC, referred to the Cancer Department of TUMS (14 men, 10 women, aged 31-81), comprised SCC group. Forty-one non-involved volunteers (19 men, 22 women; aged 23–67 years), who did not have clinical signs of gingival inflammation comprised the control group.

In all groups, participants with systemic and periodontal diseases (periodontal pocket more than

three mm.), or who were taking any medications at the time of the study were excluded. The protocol was approved by the Review Board of TUMS, and written informed consent was obtained from all patients and control subjects.

Saliva collection

Five milliliters of unstimulated whole salivary samples was obtained by expectoration, in the absence of chewing movements, in dry plastic vials with the test subject sitting in a relaxed position. The collected saliva samples were centrifuged (2000g for 10 minutes). The supernatants were stored at -20°C until further analysis. Samples were collected at the same time of day (10 a.m.–12 p.m.) and at least 2 hours after the last intake of food or drink.

Analysis of saliva

Enzyme-linked immunosorbent assay (ELISA) was applied to measure the unstimulated whole salivary concentration of p53. The wild type of human p53 ELISA kit was provided from Bender Medsystems (Vienna, Austria). Determination of p53 level was carried out according to the manufacturers' instructions. Briefly, after preparing all needed buffers and reagents, saliva samples were added to microwells coated with first antibody, and then biotin-conjugated antihuman p53 antibody was added and allowed to bind to human p53 captured by the first antibody for 2 hours of incubation. Then, the wells were washed three times with wash buffer using a plate washer to remove unreacted proteins. Next, streptavidin-HRP was added to the wells and allowed to bind to the biotin-conjugated antibody for one hour of incubation, followed by washing the plates. After that, TMB substrate solution was added to the wells and color development proceeded for 10 minutes, when the reaction was ended by adding stop solution.

Subsequently, absorbance was read at a wavelength of 450 nm on an ELISA reader, and p53 concentration was determined, with the limit of detection being 0.33 U/ml.

Statistical analysis

Data were analyzed by χ^2 and ANOVA followed by the Tukey posthoc test. Receiver operating characteristic (ROC) analysis was used to determine the cut-off point for salivary P53 between patients with SCC or OLP and healthy individuals. Differences among means were considered statistically significant if $P < 0.05$.

Results

The buccal mucosa was the most common site for OLP (48%), followed by the gingiva (32%) and tongue (20%). The tongue was the most common site for SCC (45%), followed by the lip (30%), buccal (15%), the floor of the mouth (5%) and the palate (5%). The stages of oral cancer in this study were II and III.

A one-way ANOVA indicated a significant

difference in saliva p53 concentration among control, OLP and SCC patients [$F(2,96) = 28.1$, $P < 0.05$] (Figure 1). Post-hoc analysis showed that the saliva p53 concentration was significantly higher in SCC patients (mean \pm SD: 5.36 ± 5.29 ; range: 0.56-15.64 U/ml) than both OLP patients (mean \pm SD: 0.94 ± 1.81 ; range: 0.34-7.08 U/ml) and control groups (mean \pm SD: 0.41 ± 0.25 ; range: 0.22-0.56 U/ml). But no significant difference was observed between OLP and control groups.

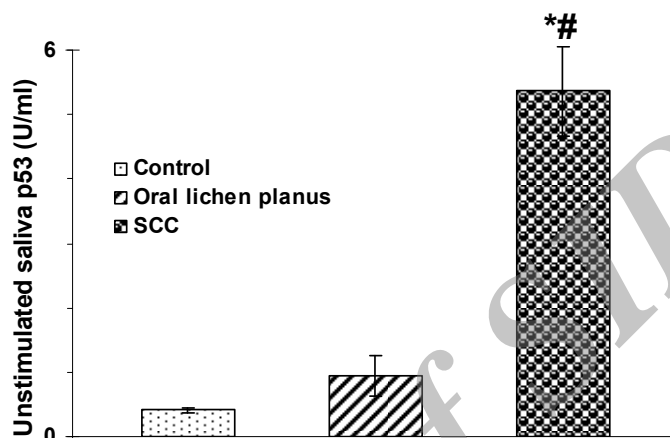


Figure 1. Unstimulated whole saliva concentration of p53 in patients with squamous cell carcinoma (SCC), Oral Lichen Planus (OLP) and control individuals. Data are expressed as mean \pm S.E.M. *Different from control; #different from patients with OLP, $P < 0.05$

There were no significant differences in saliva p53 levels between the males and the females in the control and OLP groups. However, it was non-significantly higher in the females than in the males who suffered from SCC (Table 1).

Table 1. Saliva p53 in the males and females

	Male	Female
Control	0.41 \pm 0.02	0.41 \pm 0.13
OLP	0.94 \pm 0.44	0.94 \pm 0.44
SCC	4.46 \pm 1.09	6.62 \pm 2.02

Data are expressed as mean \pm S.E.M

An optimal cut-off point of 0.54 U/ml for salivary p53 between SCC and control groups was determined using ROC analysis. The AUC was 0.99 (asymptotic significance $P = 0.0001$). In particular, the cut-off value was associated with an excellent prognostic sensitivity (0.95%) and negative predictive value (specificity = 100%). P53 positive participants were 35% in OLP group and 100% in patients with SCC. This was significantly higher in both the OLP and SCC patients

than control individuals.

Discussion

As a diagnostic medium, saliva has several advantages. Its collection is safe, non-invasive, inexpensive, and simple, and it may be collected repeatedly without discomfort to the patient (13,14). Several tumor markers present in saliva. Finding biomarkers in saliva for the detection of serious systemic illnesses, such as cancer, is of great interest for most salivary researchers (15,16). Relevant biomarkers hold more promise as early prognostic markers. Among these, the p53 gene product deserves particular attention (17).

Nonmutated p53 protein plays an important role in the prevention of malignancies in humans, differentiation and apoptosis of tumor cells. It has been suggested that p53 controls a cell cycle checkpoint (18) Detection degradation of p53 protein in pre-malignant lesions may help in identifying patients who are at high risk of developing cancer (19). The central point of

clinical significance of any molecular event involved in oncogenesis is its prognostic value as an indicator of disease outcome (20). The current study indicates that the salivary p53 biomarker in patients with squamous cell carcinoma is significantly higher than non-involved participants, which is consistent with reports on the p53 level in patients with SCC (21,22). Having non-involved participants as a control group, use of saliva as a medium, and applying ELISA technique differentiates the present study from others.

p53 is a famous tumor suppression gene, and the action of its wild-type is inhibition of oncogene-mediated proliferation and transformation. Cells with wild-type of p53 can delay the cell cycle to repair damaged DNA, or deflect the cell into apoptosis.

In case of mutation of the P53 gene, or its absence, cells continue to replicate the damaged DNA, leading to more mutations and chromosomal abnormality. The most common molecular defects in oral squamous carcinoma are mutations in the P53 gene, which may result in the formation of highly stabilized protein, with a longer half-life in tissues than the wild-type protein (1). This study showed that unstimulated saliva wild type of p53 concentration significantly increases in SCC than in control individuals. It seems that not only mutated but also unmutated p53 levels are overexpressed in SCC.

OLP is a rather frequent lesion (6) that affects approximately 1-2% of the adult population. The disease occurs more frequently in women than in men, and is more common in the middle-aged and elderly than in young people (2,5). In this study, accurate criteria for diagnosis have been proposed in which histologic and clinical criteria are settled to define OLP. Many recent studies have showed that genetic alterations can be detected early during the process of oral cancer development; in particular lesions defined by WHO as "epithelial precursor lesions" (23). Patients with chronically inflamed oral mucosa are thought to be at increased risk for malignant transformation (24). However, it has been shown that approximately 0.2 percent of OLP patients develop oral SCC each year (25).

While most of the studies could not identify risk factors for the malignant transformation of OLP, a few authors proposed that it may be a consequence of alterations in cell cycle control mechanism affecting wide areas of the oral mucosa (26).

In the study of Lee *et al.*, overexpression of p53 was found in 28.6% of the OLP patients (27). In this study, the p53 positive case was 35% in OLP group which this

was significantly higher than in control individuals. Interestingly, it was significantly higher in OLP patients with reticular form (47%) than erosive form (23%).

The epithelial proliferative and anti-apoptotic response in OLP seems to originate from the inflammatory infiltrate. Moreover, this may generate mutagenic stimuli upon DNA. These actions may induce important activation of the p53 system that arrests the cell cycle for DNA repair. In this context, p53 mutations may constitute an important oncogenic event in malignantly transformed OLP, being able to generate a cell population in which new summative oncogenic events lead to the acquisition of a malignant phenotype. Therefore, the low frequency of p53 mutations could explain the low malignant transformation rate of OLP (23).

At present, the mechanism underlying p53 overexpression in OLP, and whether OLP itself can progress to oral cancer, are subject to controversy (23). OLP is characterized by a high cellular turnover in most patients, probably due to the autoimmune disease, and increased turnover is not related to the clinical disease presentation (23).

This study could not confirm the precancerous nature of OLP based on the relatively low p53 expressions in comparison to SCC.

References

1. Acay RR, Felizzola CR, de Araújo N, et al. Evaluation of proliferative potential in oral lichen planus and oral lichenoid lesions using the immunohistochemical expression of p53 and Ki67. *Oral Oncol* 2006;42(5):475-80.
2. Agha-Hosseini F, Mirzaii-Dizgah I, Mikaili S, et al. Increased salivary lipid peroxidation in human subjects with oral lichen planus. *Int J Dent Hyg* 2009;7(4):246-50.
3. Agha-Hosseini F, Khalili M, Rohani B. Immunohistochemistry analysis of p53 and ki-67 proteins in oral lichen Planus and normal oral mucosa. *Iranian J Publ Health* 2009;38(2):37-43.
4. Agha-Hosseini F, Borhan-Mojabi K, Monsef-Esfahani HR, et al. Efficacy of purslane in the treatment of oral lichen planus. *Phytother Res* 2010;24(2):240-4.
5. Ebrahimi M, Boldrup L, Coates PJ, et al. Expression of novel p53 isoforms in oral lichen planus. *Oral Oncol* 2008;44(2):156-61.
6. Valente G, Pagano M, Carrozzo M, et al. Sequential immunohistochemical p53 expression in biopsies of oral lichen planus undergoing malignant evolution. *J Oral Pathol Med* 2001;30(3):135-40.

7. Ogmundsdóttir HM, Hilmarsdóttir H, Astvaldsdóttir A, et al. Oral lichen planus has a high rate of TP53 mutations. A study of oral mucosa in Iceland. *Eur J Oral Sci* 2002;110(3):192-8.
8. Hassan NM, Tada M, Hamada J, et al. Presence of dominant negative mutation of TP53 is a risk of early recurrence of oral cancer. *Cancer Lett* 2008;270(1):108-19.
9. Snyder LA, Bertone ER, Jakowski RM, et al. p53 expression and environmental tobacco smoke exposure in feline oral squamous cell carcinoma. *Vet Pathol* 2004;41(3):209-14.
10. Bermejo-Fenoll A, Sanchez-Siles M, López-Jornet P, et al. Premalignant nature of oral lichen planus. A retrospective study of 550 oral lichen planus patients from south-eastern Spain. *Oral Oncol* 2009;45(8):e54-6.
11. Lee JJ, Kuo MY, Cheng SJ, et al. Higher expressions of p53 and proliferating cell nuclear antigen (PCNA) in atrophic oral lichen planus and patients with areca quid chewing. *Oral Surg Oral Med Oral Pathol Oral Radiol Endod* 2005;99(4):471-8.
12. Mashayekhi F, Aghahoseini F, Rezaie A, et al. Alteration of cyclic nucleotides levels and oxidative stress in saliva of human subjects with periodontitis. *J Contemp Dent Pract* 2005;6(4):46-53.
13. Agha-Hosseini F, Mirzaii-Dizgah I, Moghaddam PP, et al. Stimulated whole salivary flow rate and composition in menopausal women with oral dryness feeling. *Oral Dis* 2007;13(3):320-3.
14. Agha-Hosseini F, Dizgah IM, Amirkhani S. The composition of unstimulated whole saliva of healthy dental students. *J Contemp Dent Pract* 2006;7(2):104-11.
15. Agha-Hosseini F, Mirzaii-Dizgah I, Rahimi A, et al. Correlation of serum and salivary CA125 levels in patients with breast cancer. *J Contemp Dent Pract* 2009;10(6):E001-8.
16. Agha-Hosseini F, Mirzaii-Dizgah I, Rahimi A. Correlation of serum and salivary CA15-10(6):E001-8.3 levels in patients with breast cancer. *Med Oral Patol Oral Cir Bucal* 2009;14(10):e521-4.
17. Fan GK, Chen J, Ping F, Geng Y. Immunohistochemical analysis of P57(kip2), p53 and hsp60 expressions in premalignant and malignant oral tissues. *Oral Oncol* 2006;42(2):147-53.
18. Yoneda K, Yokoyama T, Yamamoto T, et al. p53 gene mutations and p21 protein expression induced independently of p53, by TGF-beta and gamma-rays in squamous cell carcinoma cells. *Eur J Cancer* 1999;35(2):278-83.
19. Guo-Kang F, Jun C, Feiyun P, et al. Immunohistochemical analysis of P57 (kip 2), p53 and hsp60 expressions in premalignant and malignant oral tissues. *Oral Oncology* (2006);42(2):147-153
20. Kaur J, Srivastava A, Ralhan R. Prognostic significance of p53 protein overexpression in betel- and tobacco-related oral oncogenesis. *Int J Cancer* 1998;79(4):370-5.
21. Schoelch ML, Regezi JA, Dekker NP, et al. Cell cycle proteins and the development of oral squamous cell carcinoma. *Oral Oncol* 1999;35(3):333-42.
22. Kuropkat C, Venkatesan TK, Caldarelli DD, et al. Abnormalities of molecular regulators of proliferation and apoptosis in carcinoma of the oral cavity and oropharynx. *Auris Nasus Larynx* 2002;29(2):165-74.
23. Montebugnoli L, Farnedi A, Marchetti C, et al. High proliferative activity and chromosomal instability in oral lichen planus. *Int J Oral Maxillofac Surg* 2006;35(12):1140-4.
24. Rad M, Hashemipoor MA, Mojtahedi A, et al. Correlation between clinical and histopathologic diagnoses of oral lichen planus based on modified WHO diagnostic criteria. *Oral Surg Oral Med Oral Pathol Oral Radiol Endod* 2009;107(6):796-800.
25. Scully C, Beyli M, Ferreira MC, et al. Update on oral lichen planus: etiopathogenesis and management. *Crit Rev Oral Biol Med* 1998;9(1):86-122.
26. González-Moles MA, Bascones-Ilundain C, Gil Montoya JA, et al. Cell cycle regulating mechanisms in oral lichen planus: molecular bases in epithelium predisposed to malignant transformation. *Arch Oral Biol* 2009;51(12):1093-103.
27. Lee JJ, Kuo MY, Cheng SJ, et al. Higher expressions of p53 and proliferating cell nuclear antigen (PCNA) in atrophic oral lichen planus and patients with areca quid chewing. *Oral Surg Oral Med Oral Pathol Oral Radiol Endod* 2005;99(4):471-8.