

Simultaneous External Iliac Artery and Vein Rupture Following Percutaneous Balloon Angioplasty

Freidoun Sabzi and Reza Faraji

Preventive Cardiovascular Research Centre Kermanshah, Kermanshah University of Medical Sciences, Kermanshah, Iran

Received: 06 Jun 2014; Accepted: 24 Dec. 2014

Abstract- A 73-year-old woman who had undergone coronary artery bypass grafting for coronary artery stenosis six years ago, presented with right lower extremity claudication. Angiography revealed right external iliac artery stenosis. Elective external iliac PTCA was performed complicated with simultaneous external iliac artery and vein rupture that was an exceedingly rare event. Retroperitoneal laparotomy with repair of ruptures took done, but the patient died with post-operative multi-organ failure.

© 2015 Tehran University of Medical Sciences. All rights reserved.

Acta Med Iran, 2016;54(2):151-155.

Keywords: Coronary artery bypass; Artery stenosis; Angiography

Introduction

Tegtmeyer has proved the efficacy of percutaneous transluminal angioplasty (PTA) as a novel technique for the treatment of focal iliac artery stenosis (1). Murphy and Henry reported that the immediate technical success rate has improved significantly, from 70% up to 95%, especially with the use of adjunctive stent placement (2,3). In Brother Study, the patency rates of 85% after 5 years have been reported for focal iliac stenoses that are comparable to surgical results (4). An increasing number of angioplasty interventions in recent years predispose patients to various associated complications of the artery and neighboring organs like nerves and veins. Angioplasty intervention not only causes injury in access site such as, hematoma or pseudoaneurysm but also potentially predisposes the vessel to thrombosis, dissection, intramural hematoma, and serious complication such as rupture and retroperitoneal hematoma. In this report, an exceedingly rare complication of PTCA i.e. simultaneous iliac artery and vein injury is reported.

Case Report

A 73-year-old woman with a history of CABG and non-controlled high blood pressure presented with claudication. The arteriogram revealed occlusion of the right external iliac artery. It was decided to recanalize

the right external iliac artery with a PTCA. Local anesthesia was chosen because we thought this procedure could not be lengthy and, should it fail; a femoro-femoral bypass graft would be put in place straight away. The left retrograde common femoral puncture was done and a 6-F introducer inserted. Plavix (6×75mg) heparin (5,000 units) was administered orally and intravenously, respectively. Arteriography showed total occlusion of the right external iliac artery (Figure 1).

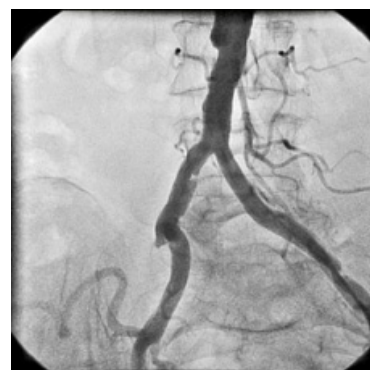


Figure 1. Complete occlusion of the external iliac artery

The right common femoral artery was visualized, and reconstitution occurred at the profunda femoris artery. The lesion was crossed with using crossover approach, with a stiff guide wire invented by Gaines (5) (Figure 2).

Corresponding Author: R. Faraji

Department of Cardiovascular Surgery, Kermanshah University of Medical Sciences, Kermanshah, Iran.

Tel: +98 831 8360295, Fax+98 831 9360043, E-mail address: r.faraji61@gmail.com

Simultaneous external iliac artery and vein rupture

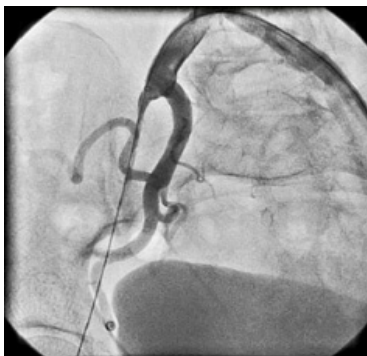

Figure 2. The guide wire in the occluded external iliac artery

In this technique, after a retrograde puncture and sheath placement into the contralateral common femoral artery (CFA), the occlusion was initially passed in crossover technique with a 0.035-inch hydrophilic guide wire, finally placed into the superficial femoral artery. With the guide wire as a marker, the ipsilateral common femoral artery (CFA) was punctured under fluoroscopic control, and a second 8-F sheath was placed. With an angled, shaped wire loop introduced through the ipsilateral sheath, the tip of the guide wire was snared and retrieved out of the sheath. The guidewire was exchanged for an Amplatz Super Stiff guide wire and the introducer for a 45-cm-long guiding sheath which was advanced across the aortic bifurcation to the origin of the right common iliac artery (Figure 3).

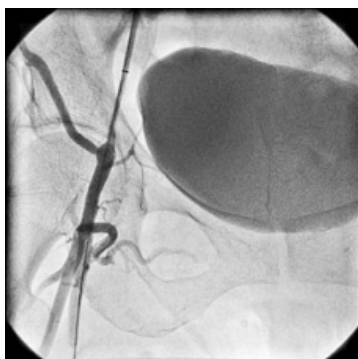


Figure 3. Predilated external iliac artery

The lesion was predilated with a 6×100 mm balloon, and then, dilation was carried out with balloons, which were inflated to 7 × 40 mm at the common femoral and iliac arteries (Figure 4).

Unfortunately, the balloon size was chosen by comparing the image of the inflated balloon to the image of the artery. During the procedure, there was a sudden drop in blood pressure to 70-50 mm Hg, which does not respond promptly to saline infusion completion arteriography in an anteroposterior view, showed contrast medium extravasations (Figure 5).

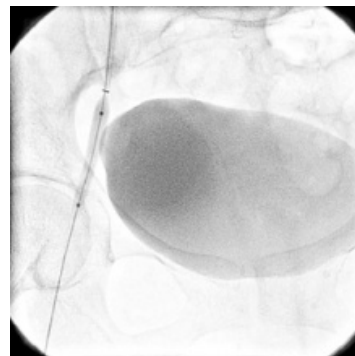


Figure 4. Predilated external iliac artery

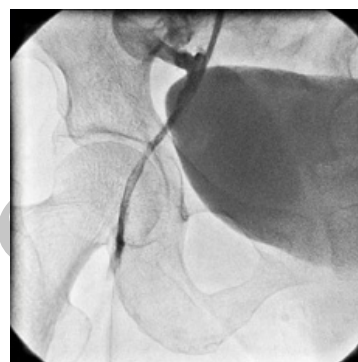

Figure 5. Rupture of the external iliac artery with extravasations of contrast medium

The urinary bladder was filled with contrast medium and due to acute rupture, was not displaced to the side. The patient's heart rate raised, and her abdomen became tender (Figure 6).

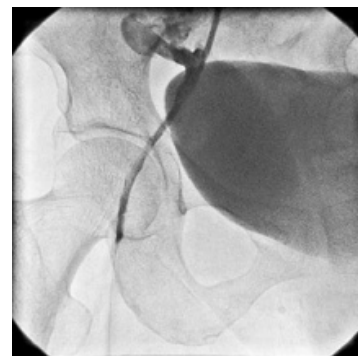


Figure 6. Acute extravasations of contrast medium without displacement of urinary bladder

A severe drop in hemoglobin level, from 13 g/dL before the procedure to 6 g/dL after the procedure, necessitated transfusion of 4 units of packed red cells, which was not effective in increasing the hemoglobin level to 10 g/dL. The blood pressure dropped to 70-50 mm Hg, the heart rate increased to 130 beats per minute, and the patient lost consciousness and intubated urgently by an anesthesiologist. A large bulging mass was

observed in the right lower abdominal quadrant. Rupture of the external right iliac artery with the balloon was strongly suspected. Interventional radiology facilities were not readily available, and the patient underwent emergency open surgery. On duty, the vascular surgeon made a clinical diagnosis of hemorrhage from the iliac rupture and, on this basis alone, the right lower quadrant was retroperitoneal explored. At the right external iliac artery (the dilation site), the right external iliac vein was closely adherent to the medial aspect of the external iliac artery. There was a bleeding with a 5-mm tear in the left external iliac vein, which was repaired with 5-0 Prolene. Also, iliac artery rupture with active bleeding in an external iliac artery (EIA) was seen and repaired as the assumed cause of the bleeding. It was presumed that blood had tracked proximally to form a massive retroperitoneal hematoma. Five units of blood were transfused intraoperatively and a further three units postoperatively in the intensive care unit.

Continuing fluid volume replacement was required, however, 1 hour later, she again became hypovolemic and hypotensive and oliguric and severe abdominal bulging with a hemoglobin of 6 g/dL was observed. The patient was in extremis, and surgical exploration by a consultant vascular surgeon proceeded immediately. The laparotomy was re-explored, but there was no active bleeding; the right common iliac artery and the common femoral artery was exposed, but no bleeding point was found but revealed a large retroperitoneal hematoma. The aortic bifurcation and iliac arteries were exposed, but no active arterial bleeding was seen. A pack was left in the retroperitoneum, and the patient was returned to the intensive care unit. Despite achieving hemorrhage control, the patient died two days later from multiple organ failures.

Discussion

Ring and Calapinto in early series of percutaneous recanalization procedures for chronic iliac artery occlusions have reported, excessively high complication rates of up to 20% (6,7). Isner and Kussmaul in separate studies reported the incidence of this complication as 11 and 13%, respectively (8,9). This complication in the case of small rupture probably causes hematoma and pseudoaneurysm and in large rupture causes hemorrhagic shock and as in our cases massive retroperitoneal hematoma and hypovolemic shock. Obstruction of bilateral iliac artery associated with distal severe aortic lesions like an aneurysm or high-grade stenosis of the aorta are not usually considered or

referred for angioplasty, but this intervention has been proved to be an effective method for the treatment of focal artery stenosis. Johnson et al. revealed that for the 209 external iliac PTAs, the predicted 3-year success rate was 57% for men and 34% for women, and only one rupture occurred that was treated non-surgically (10). In Tegtmen study (1), the initial success rate was 94.7% for lesions and 93.0% of patients. The indications for percutaneous transluminal angioplasty included claudication in 117 patients (58.5%), rest pain or ischemic night pain in 47 (23.5%), limb salvage in 33 (16.5%), and aiding in wound healing in three (1.5%). In the series, 70% of the patients had two or more cardiovascular risk factors. Angioplasty was initially unsuccessful in 14 patients, and 10 patients were lost to follow-up. In Blum study, 151 iliac lesions (149 stenoses, 2 occlusions) in 104 patients were treated by percutaneous transluminal angioplasty and only one minor complication i.e. groins hematoma was seen (11).

Sullivan showed that PTA and stenting of the iliac arteries are associated with reasonable angiographic, hemodynamic, and clinical success (12). The outcome is favorably affected by higher initial severity of stenosis and greater extent of disease, lower severity of baseline ischemia, younger age, and by patency of the ipsilateral superficial femoral artery. The Werwerk *et al.*, placed 154 primary stents in 103 patients with iliac artery occlusions of at least 3 months duration (13). The mean length of the occluded segments was 5.1 cm. All patients had symptoms, with claudication or trophic changes. Ninety-nine patients showed clinical improvement, with relief or improvement of claudication. Complications that required percutaneous or surgical intervention occurred in six patients; minor complications occurred in another six. Embolization occurred in five patients. In Hausegger study (14) during a 5-year period (PTA) was attempted in 134 iliac, femoral, and popliteal arteries in 127 patients. Complications were systematically registered and classified as major, minor, and radiologic. Seventeen major complications (12.7%) including three deaths, occurred as well as five minor (3.7%) and 13 radiologic complications (9.7%).

The last group showed no clinical symptoms. In 2043 iliac procedures that were performed by 13 interventionists two retroperitoneal hematomas occurred. In Waxman study (15), the complication rate of arterial access via the CFA was as low as 0.52% for diagnostic procedures, but this complication for interventional procedures, in Fruwih study was 1% to 6% (16). Belli described that the complications of PTA in iliac and lower limb vessels were relatively

Simultaneous external iliac artery and vein rupture

infrequent, with rates of 3% to 10% (17). In this study, the risk of death was 0.3%. Acute hemorrhages into the retroperitoneal space of the posterior abdominal wall are not occult and separate the posterior peritoneum from the underlying structures. Due to the lack of tamponade, and with the entire abdominal cavity in which to expand, it is often unsuspected until the patient is hypotensive with a falling hematocrit.

In our patient due to anticoagulant usage and rapid abdominal expansion, RPH was discovered immediately, and because there was a systemic sign of circulatory collapse, it may be managed operatively. In subtle cases, when suspected, the diagnosis of RPH can be confirmed noninvasively by ultrasound imaging or computed tomography (CT). If an obvious preceding causal factor is known, the specific anatomic location of the hematoma may enable the source of hemorrhage to be ascertained. Otherwise, the precise site of leakage needs to be determined by arteriography or operatively to direct management appropriately. Lodge found that in cardiac surgery RPH is a recognized complication of IABP insertion site, particularly if the entry site is high (18). We found that this complication was higher in thin, old age patients. In Johnston study (10), the incidence of RPH after iliac procedures was approximately 1%. Chong revealed (19) that, however, it can occur dramatically during angioplasty as a result of arterial rupture, but in Formichi study endoluminal placement of a covered stent was a quick and effective treatment (20). Sereersm found that however RPH accounts for a significant cause of mortality after interventional procedures, the risk of RPH in interventional procedures in Sreesram study was 0.15% (21).

Post-interventional RPH is a serious and poor prognosis complication. All 11 patients in Sreesram study died or physically permanently disabled. Our study has a unique feature that PTCA caused combined arterial and venous injury. Our case is the first case that so far has been reported in medical literature. The first and only case of venous injury following renal artery PTCA was reported by Sharma (22). In this report, PTCA of a renal artery caused isolated renal vein injury. The precise mechanism of venous injury following PTCA of an artery was not determinate. We believe that any arthritis with inflammation of the external wall of an artery causes adhesion of neighboring vessels (vein). Balloon dilatation of artery cause stretching of adherent thin-wall neighboring vein and venous injury. Another mechanism is penetration of atheromatous plaque to vein wall by arterial dilatation.

The acute post-interventional hypotension and the

drop in hemoglobin level reveal serious oncoming iatrogenic accident. Completion angiography showed the occurrence of iliac artery rupture in the patient, the hypotension was not short-lived and associated with tachycardia.

The patient has severe pain at the angioplasty location, and the blood transfusion was not effective in increasing the hemoglobin level. The acute onset of the rupture could have been due to the continuous expansion and radial force exercised by the balloon, which further stretched the weakened arterial wall, eventually causing it to burst with stretching and rupture of iliac vein. This rupture has been linked to guidewire perforation, the use of an oversize balloon, the use of a cutting balloon, recanalization of occlusions, high-grade stenoses, heavily calcified arteries, recent endarterectomy, steroid therapy, and inflammatory disease of the arterial system.

References

1. Tegtmeier CJ, Hartwell GD, Selby JB, et al. Results and complications of angioplasty in aortoiliac disease. *Circulation* 1991;83(2 suppl):53-60.
2. Murphy KD, Encarnacion CE, Le VA, et al. Iliac artery stent placement with the Palmaz stent: a follow-up study. *J Vasc Intervent Radiol* 1995;6(3):321-9.
3. Henry M, Amor M, Ethevenot G, et al. Palmaz stent placement in iliac and femoropopliteal arteries. *Radiology* 1995;197(1):167-74.
4. Brothers TE, Greefield LJ. Long-term results of aortoiliac reconstruction. *J Vasc Intervent Radiol* 1990;1(1):49-55.
5. Gaines PA, Cumberland DC. Wire loop technique for angioplasty of total iliac artery occlusions. *Radiology* 1988;168(1):275-6.
6. Ring EJ, Freimann DB, McLean GK, et al. Percutaneous recanalization of common iliac artery occlusions. *AJR Am J Roentgenol* 1982;139(3):587-9.
7. Colapinto RF, Stronell RD, Johnston WK. Transluminal angioplasty of complete iliac obstructions. *Am J Roentgenol* 1986 Apr;146(4):859-62.
8. Isner JM, Cohen SR, Virmani R. Complications of the intraaortic balloon counterpulsation device: clinical and morphologic observations in 45 necropsy patients. *Am J Cardiol* 1980;45(2):260-8.
9. Kussmaul WG, Buchbinder M, Whitlow PL. Rapid arterial hemostasis and decreased access site complications after cardiac catheterization and angioplasty. *J Am Coll Cardiol* 1995;25(7):1685-92.
10. Johnston KW. Iliac arteries. *Radiology* 1993;186(1):207-12.
11. Blum U, Gabelmann A, Redecker M, et al. Percutaneous

- recanalization of iliac artery occlusions: results of a prospective study. *Radiology* 1993;189(2):536-40.
12. Sullivan TM, Childs MB, Bacharach JM, et al. Percutaneous transluminal angioplasty and primary stenting of the iliac arteries in 288 patients. *J Vasc Surg* 1997;25(5):829-38.
 13. Vorwerk D, Gunther RW, Schurmann K, et al. Aortic and iliac stenoses. Follow-up results of stent placement after insufficient balloon angioplasty in 118 cases. *Radiology* 1996;198(1):45-8.
 14. Hausegger KA, Lammer J, Klein G, et al. Percutaneous recanalization of pelvic artery occlusions: fibrinolysis, PTA, stents. *Rofo* 1991;155(6):550-5.
 15. Waksman R, King SB, Douglas JS. Predictors of groin complications after balloon and new-device coronary interventions. *Am J Cardiol* 1995;75(14):886-9.
 16. Fruhwirth J, Pascher O, Hauser H. Local vascular complications after iatrogenic femoral artery puncture. *Wien Klin Wochenschrift* 1996;108(7):196-200.
 17. Belli AM, Cumberland DC, Knox AM. The complication rate of percutaneous peripheral balloon angioplasty. *Clin Radiol* 1990;41(6):380-3.
 18. Lodge JP, Hall R. Retroperitoneal haemorrhage: A dangerous complication of common femoral arterial puncture. *Eur J Vasc Surg* 1993;7(3):355-7.
 19. Chong WK, Cross FW, Raphael MJ. Iliac artery rupture during percutaneous angioplasty. *Clin Radiol* 1990;41(5):358-9.
 20. Formichi M, Raybaud G, Benichou H. Rupture of the external iliac artery during balloon angioplasty: Endovascular treatment using a covered stent. *J Endovasc Surg* 1998;5(1):37-41.
 21. Sreeram S, Lumsden AB, Miller JS. Retroperitoneal hematoma following femoral arterial catheterization: A serious and often fatal complication. *Am Surg* 1993;59(2):94-8.
 22. Sharma S, Arya S, Mehta SN. Renal vein injury during percutaneous transluminal renal angioplasty in nonspecific aortoarteritis. *Cardiovasc Intervent Radiol* 1993;16(2):114-6.

Archive of SID