

Guillain-Barré Syndrome as First Presentation of Non-Hodgkin's Lymphoma

Abolhassan Ertiaei¹, Mahsa Ghajarzadeh², Azizollah Javdan¹, Abbas Taffakhori³, Bahaaddin Siroos³,
Mohsen Esfandbod⁴, and Hooshang Saberi^{1,2}

¹ Department of Neurosurgery, School of Medicine, Tehran University of Medical Sciences, Tehran, Iran

² Brain and Spinal Injury Research Center, Imam Khomeini Hospital, Tehran University of Medical Sciences, Tehran, Iran

³ Department of Neurology, Iranian Center of Neurological Research, Imam Khomeini Hospital,
Tehran University of Medical Sciences, Tehran, Iran

⁴ Department of Medicine, School of Medicine, Tehran University of Medical Sciences, Tehran, Iran

Received: 30 Apr. 2015; Accepted: 30 Jun. 2015

Abstract- We present a woman referred with underlying non-Hodgkin's lymphoma (NHL) masquerading clinically with Guillain-Barré syndrome (GBS) like syndrome. At first evaluation, chest CT-Scan along with brain and whole spine MRI were normal. Electrodiagnostic studies were in favor of acute generalized polyradiculoneuropathy. Laboratory evaluation revealed hypoglycorrhachia. She treated with plasmapheresis after two weeks; she was discharged from hospital, but neurological recovery was not complete. After 6 months, she came back with acute onset of weakness in lower limbs, back pain, fever and urinary incontinence. Pinprick and light touch complete sensory loss was found beneath umbilicus. Thoracic MRI with contrast revealed a dorsal epidural mass extending smoothly from T8 to T12 (10 cm) with spinal cord compression. She underwent urgent laminectomy for spinal cord decompression. Histological examination revealed small round cell tumor suggestive of malignant T-cell type lymphoma. In cases with Guillain-Barré syndrome presentation, systemic hematologic disorders such as non-Hodgkin's lymphoma should be considered as one of the differential diagnosis of underlying disease.

© 2016 Tehran University of Medical Sciences. All rights reserved.

Acta Med Iran, 2016;54(7):471-474.

Keywords: Guillain-Barré syndrome; Non-Hodgkin's lymphoma; Polyradiculopathy

Introduction

The prevalence of non-Hodgkin's lymphoma (NHL) has increased in recent years, and different factors such as immune-suppression, genetics, and exposure to chemical agents have been considered to have roles in developing the disease (1-2). In contrast to Hodgkin lymphoma, NHL is not limited to lymph nodes and in near one-third of patients, extranodal organs are involved (3). In 0.1-3.3% of lymphomas, spinal epidural tissues is involved, and thoracic spine is the most common site of involvement (69%) (4).

Guillain-Barré syndrome (GBS) is a polyradiculopathy characterized by acute areflexic motor paralysis with varying degrees of sensory impairment (6). It may also be one of the presentations of recent vaccination, hematological malignancy, and connective tissue disorder. Peripheral nervous system impairment is an extremely rare manifestation of Hodgkin's lymphoma (HL) or non-Hodgkin's

lymphoma.

Here, we present a woman referred with underlying NHL masquerading clinically with GBS like syndrome.

Case Report

A 19-year-old woman was admitted with bilateral facial paresis (mainly in left side), weakness of lower limbs and progressive lower limbs paresthesia since 20 days before admission. On neurological examination, higher mental functions and cranial nerves were intact. Proximal and distal forces of lower limb's muscles were approximately 3/5 (symmetrically). Forces of lower limb's muscles were 5/5.

Deep tendon reflexes were absent. The sensory examination did not reveal any abnormality. Soon after, she developed upper limb weakness, but sphincter function was normal. Abdominopelvic ultrasonography showed no organomegaly or lymphadenopathy. Chest CT-Scan along with brain and whole spine MRI were

Corresponding Author: H. Saberi

Department of Neurosurgery, School of Medicine, Tehran University of Medical Sciences, Tehran, Iran
Tel: +98 912 1085771, Fax: +98 21 66938885, E-mail address: hgsaberi@gmail.com

normal at that time.

Electrodiagnostic studies were in favor of acute generalized polyradiculoneuropathy. Laboratory evaluation revealed hypoglycorrhachia (Table 1).

Table 1. Laboratory findings

Findings	Value
Hb (gr/L)	9.4
Plt	97000
WBC	5500
Serum Glucose (mgr/dl)	120
Glucose(mgr/dl)	49
CSF	
WBC	1-2
Protein	100

CSF cytology was inconclusive without any evidence of malignant cells. Blink reflex study was compatible with complete peripheral left facial nerve lesion. Bone marrow biopsy disclosed severe hypocellularity with maturation arrest, without evidence of malignancy, fibrosis, and inflammation.

Serologic tests ruled out infectious and collagen vascular disorders. According to clinical manifestations and electrodiagnostic findings, a diagnosis of Guillain-Barré syndrome was made. Treatment with plasmapheresis led to favorable clinical improvement. After two weeks, she was discharged from hospital, but neurological recovery was not complete. She attended in rehabilitation programs.

After 6 months, she came back with acute onset of weakness in lower limbs, back pain, fever and urinary incontinence. Pinprick and light touch complete sensory loss was found beneath umbilicus. Thoracic MRI with contrast revealed a dorsal epidural mass extending smoothly from T8 to T12 (10 cm) with spinal cord compression (causing hyperintense signal in the adjacent cord parenchyma) (Figure 1a and 1b).

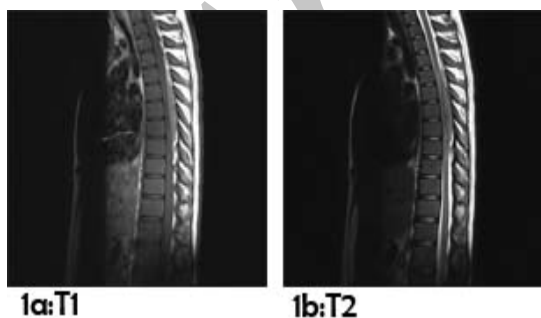

Figure 1. 1a:T1 sequence of thoracic MRI
1b:T2 sequence of thoracic MRI

She underwent urgent laminectomy for spinal cord decompression. Gray colored soft and suctionable epidural mass was totally removed uneventfully.

Postoperatively (during 2 weeks) the patient’s neurological status did not reveal motor changes. After 3 months spinal rehabilitation, a neurologic exam revealed that sensory level is on T12. Histological examination using conventional techniques (Figure 2) and immunohistochemistry (Figure 3) revealed small round cell tumor suggestive of malignant T-cell type lymphoma (TdT and Mic2 were positive EMA, CK, CD20, Myogenin were all negative, LCA was weakly positive, CD79 and CD3 were scattered).

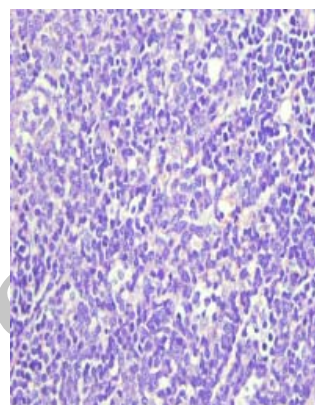


Figure 2. Histological evaluation (H and E) showed complete effacement of the epidural space by sheets of atypical lymphoid cells. The tumor cells were of large size resembling normal centroblasts or immunoblasts.

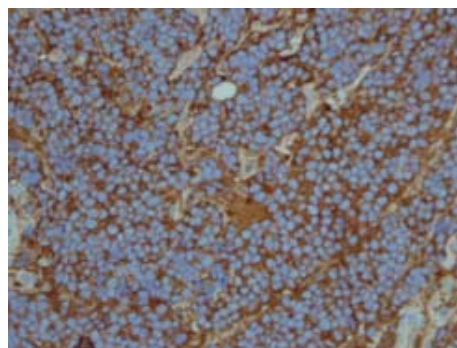


Figure 3. Immunohistochemistry (IHC) staining revealed positive staining with MIC 2

She was treated with emergency radiotherapy with eight cycles of R-CHOP chemotherapy. In follow-up MRI (6 months later), no tumor recurrence was detected. Neurological examination revealed no change during 6 months of surgery.

Discussion

Only 9% of spinal epidural tumors are lymphomas (7). Non-Hodgkin's lymphoma rarely involves spinal epidural space. The most common site of involvement is

thoracic spine (69%) followed by lumbar (27%) and cervical region (4%) (4-5). In contrast to our case, the usual age of epidural spinal tumors as the result of systemic lymphomas is fourth to the fifth decade of life and male to female ratio is 1.6 (4-5,8). Our case was a young (19-year-old) woman. Lower limb weakness, localized back pain, and bladder dysfunction are triads of presentation which were present in our case. In these cases, MR scans show iso/hypointense lesion on both T1/T2 weighted images with contrast enhancement as was found in this patient. On immunohistochemistry, these tumor cells are negative for CD138, CD30, and CD3, while positive for LCA and CD20 (9). In this case, CD20 and LCA were positive while CD79 and CD3 were scattered.

According to the type of lymphoma, different kinds of peripheral neuropathies such as Guillain-Barré syndrome could be present. Guillain-Barré syndrome has been described in different hematologic diseases especially in cases with Hodgkin's lymphoma (10). However, Guillain-Barré syndrome has been described in rare cases of non-Hodgkin's lymphoma (11-13). Diagnosis of Guillain-Barré syndrome is made based on clinical data along with CSF analysis and the nerve conduction study. In our case, clinical data were consistent with a diagnosis of Guillain-Barré syndrome, but glucose level was low in CSF. In a case reported by Polo-Romero, mononuclear pleocytosis was present in CSF (14) which could mimic an infectious disease (15-16). In similar cases with Guillain-Barré syndrome presentation, there is a relationship between antibodies, presentation, and progression of the syndrome. In near 20% of all cases, anti-ganglioside antibodies are present and in most cases, *Campylobacter jejuni* infection history is positive (17). Different mechanisms have been described for the association between polyneuropathy and lymphoma such as direct infiltration of the nerve trunks by lymphoma cells, vascular impairment with nerve infarction; and an inflammatory response of the type occurring in GBS (10). On the other hand, hematological medications such as vincristine toxicity could cause GBS (12,18). The symptoms in our case presented before chemotherapy, and it could not be related to therapy. In this case, we could consider GBS as an immune-mediated para-neoplastic syndrome as the previous history of infection was not clear for the patient. Association of GBS with lymphoma is a rare condition, and it is even rarer to present before hematological symptoms (11,14).

In cases with Guillain-Barré syndrome presentation, systemic hematologic disorders such as non-Hodgkin's

lymphoma should be considered as one of the differential diagnosis of underlying disease.

References

1. Ferlay J, Shin HR, Bray F, Forman D, Mathers C, Parkin DM. Estimates of worldwide burden of cancer in 2008: GLOBOCAN 2008. *Int J Cancer* 2010;127:2893-917.
2. Parkin DM, Bray F, Ferlay J, Pisani P. Global cancer statistics, 2002. *CA Cancer J Clin* 2005;55:74-108.
3. Lee SJ, Suh CW, Lee SI, Kim WS, Lee WS, Kim HJ, et al. Clinical characteristics, pathological distribution, and prognostic factors in non-Hodgkin lymphoma of Waldeyer's ring: nationwide Korean study. *Korean J Intern Med* 2014;29:352-60.
4. Kapoor R, Kumar V, Sharma S. Primary extradural non-Hodgkin's lymphoma. *JK Science* 2006;8:45-8.
5. Hughes RA, Rees JH. Clinical and epidemiologic features of Guillain-Barré syndrome. *J Infect Dis* 1997;176:S92-8.
6. Mally R, Sharma M, Khan S, Velho V. Primary lumbosacral spinal epidural non-Hodgkin's lymphoma: a case report and review of literature. *Asian Spine J* 2011;5:192-5.
7. Lim CC, Chong BK. Spinal epidural non-Hodgkin's lymphoma: case reports of three patients presenting with spinal cord compression. *Singapore Med J* 1996;37:497-500.
8. McDonald A, Nicoll J, Rampling R. Non-Hodgkin's lymphoma presenting with spinal cord compression; a clinicopathological review of 25 cases. *Eur J Cancer* 2000;36:207-13.
9. Kelly JJ, Karcher DS. Lymphoma and peripheral neuropathy: a clinical review. *Muscle Nerve* 2005;31:301-13.
10. Vallat J, De Mascarel H, Bordessoule D, Jauberteau M, Tabaraud F, Gelot A, et al. Non-Hodgkin malignant lymphomas and peripheral neuropathies—13 cases. *Brain* 1995;118:1233-45.
11. Re D, Schwenk A, Hegener P, Bamborschke S, Diehl V, Tesch H. Guillain-Barré syndrome in a patient with non-Hodgkin's lymphoma. *Ann Oncol* 2000;11:217-20.
12. Kivity S, Shalmon B, Sidi Y. Guillain-Barre syndrome: an unusual presentation of intravascular lymphoma. *Isr Med Assoc J* 2006;8:137-8.
13. Polo-Romero F, Sánchez-Beteta P, Perona-Buendía P, Pérez-García A. Guillain-Barré syndrome as first presentation of non-Hodgkin lymphoma. *Neurología* 2012;27:511-3.
14. Berciano J, Berciano M, Lafarga M. Cerebrospinal fluid pleocytosis with neutrophil leukocytes in Guillain-Barré syndrome. *Eur J Neurol* 2004;11:645-6.

15. Rauschka H, Jellinger K, Lassmann H, Braier F, Schmidbauer M. Guillain-Barré syndrome with marked pleocytosis or a significant proportion of polymorphonuclear granulocytes in the cerebrospinal fluid: Neuropathological investigation of five cases and review of differential diagnoses. *Eur J Neurol* 2003;10:479-86.
16. Codina Puiggrós A, Cervera Radigales C. Síndrome de Guillain-Barré. *Med Clí* 2002;118:142-5.
17. Seffo F, Daw HA. Non-Hodgkin lymphoma and Guillain-Barré syndrome: a rare association. *Clin Adv Hematol Oncol* 2010;8:201-3.

Archive of SID